Université Paris Cité

Embolie Pulmonaire & Hypertension Pulmonaire

Pr Marie-Pierre REVEL, Hôpital Cochin, APHP.Centre

Objectifs

- Performance de l'angioscanner pour le diagnostic de l'embolie, points importants du compte-rendu
- Sur quels éléments suspecter une forme chronique, un CPCPE
- Revoir les autres causes d'hypertension pulmonaire

Objectifs

- Performance de l'angioscanner pour le diagnostic de l'embolie, points importants du compte-rendu
- Sur quels éléments suspecter une forme chronique, un CPCPE
- Revoir les autres causes d'hypertension pulmonaire

ANGIOSCANNER THORACIQUE EN TECHNIQUE MULTIBARRETTES

- Performance élevée, validée par de nombreuses études de suivi clinique
- Le risque d'événement thromboembolique après un angioscanner négatif est de 0.3 % *(Righini, Lancet 2008)*

La prévalence de l'EP est faible dans les séries les plus récentes

- 9,7 % dans une série de 3500 CTA *(Adams et al Am J Med. 2013)*

- **Seuls les patients présentant une probabilité clinique élevée ou des D-dimères élevés doivent être adressés en angioscanner thoracique**
- Seuil de D-dimères : 500 µg/L ou (âge x 10 µ g/L au-delà de 50 ans)

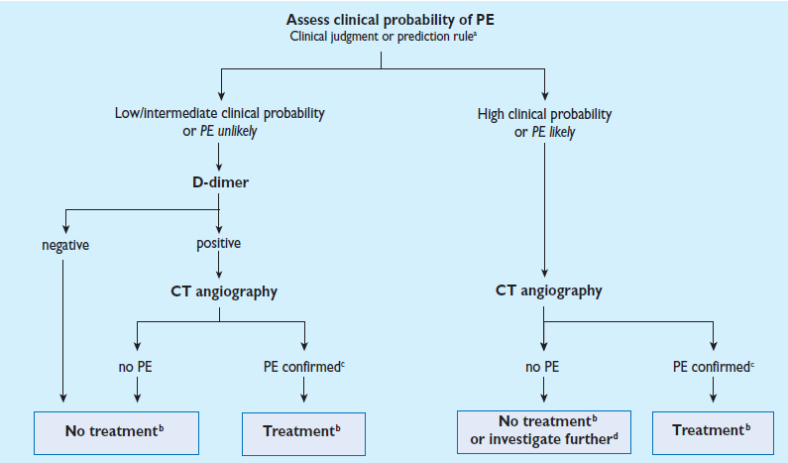

Konstantinides SV et al. 2014 ESC guidelines on the diagnosis and management of acute pulmonary embolism. Eur Heart J. 2014

• Contre indications

- Allergie aux produits de contraste iodés
- Insuffisance rénale (clairance de la créatinine <30ml/mn)
- Situations rares
  - Hyperthyroïdie non contrôlée
  - Protéinurie de Bence Jones

LA GROSSESSE n'est pas une contre indication

- Dose fœtale négligeable, ≤ Scintigraphie pulmonaire (Winer-Muram-Radiology 2002)
- Administration de produit de contraste iodé : pas d'effet sur la fonction thyroïdienne à la naissance (Bourjeily- Radiology 2010)
- Mais dose mammaire >>> Scintigraphie pulmonaire


Radiology

American Thoracic Society Documents: An Official American Thoracic Society/Society of Thoracic Radiology Clinical Practice Guideline—Evaluation of Suspected Pulmonary Embolism in Pregnancy[1]

Ann N. Leung
Todd M. Bull
Roman Jaeschke
Charles J. Lockwood
Phillip M. Boiselle
Lynne M. Hurwitz

Background: Pulmonary embolism (PE) is a leading cause of maternal mortality in the developed world. Along with appropriate prophylaxis and therapy, prevention of death from PE in pregnancy requires a high index of clinical suspicion followed by a timely and accurate diagnostic approach.

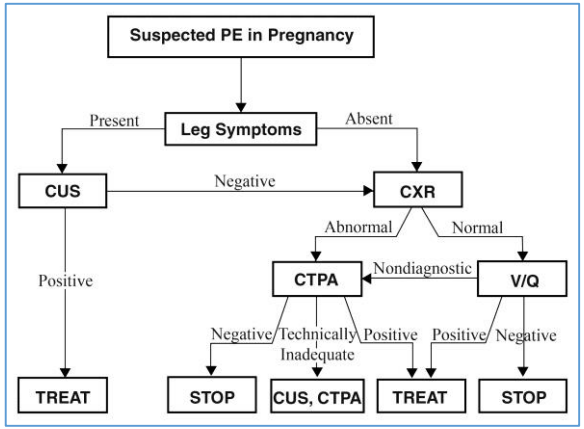

Leung et al. Radiology 2012;262:635-46.

Université de Paris

COMMENT OPTIMISER L'OPACIFICATION?

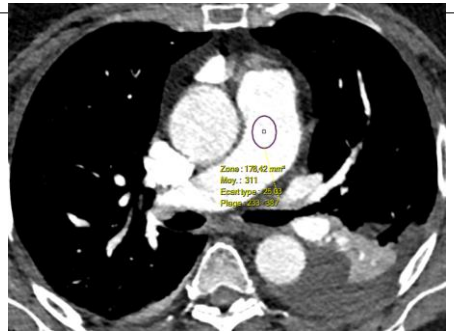

- Nécessité d'avoir une bonne opacification artérielle pulmonaire
  - (au moins 250 UH 25O UH)
- Bas kilovoltage: 100 kV ou moins
- Bolus tracking

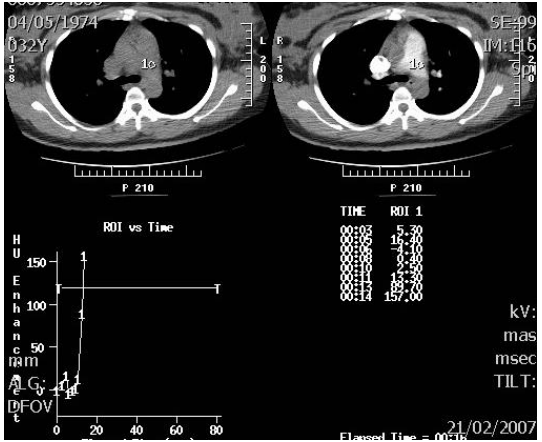

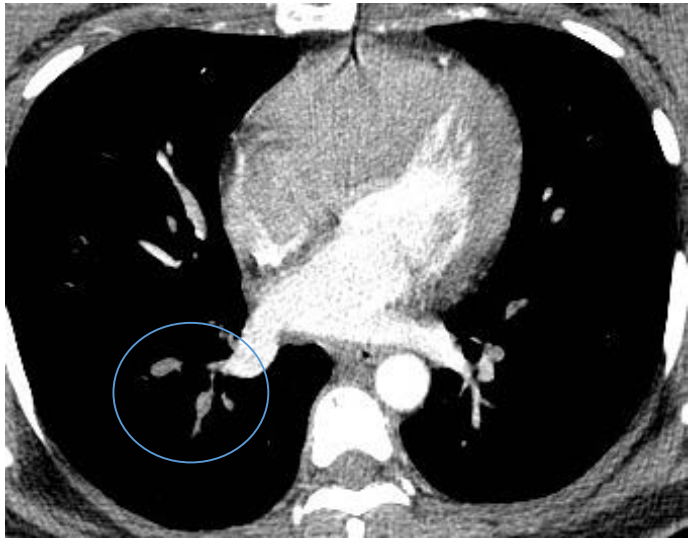

*Schueller-Weidekamm C et al. CT angiography of pulmonary arteries to detect pulmonary embolism: improvement of vascular enhancement with low kilovoltage settings. Radiology. 2006

Pulmonary CT angiography protocol adapted to the hemodynamic effects of pregnancy

Ridge et al. AJR 2011

–Pas d’inspiration profonde

– Injection d’un volume élevé de produit de contraste
– Bas kilovoltage 100 kV
– Réduction dans l’axe Z: on réduit l’acquisition du toit de l’aorte au dôme hépatique pour limiter l’irradiation

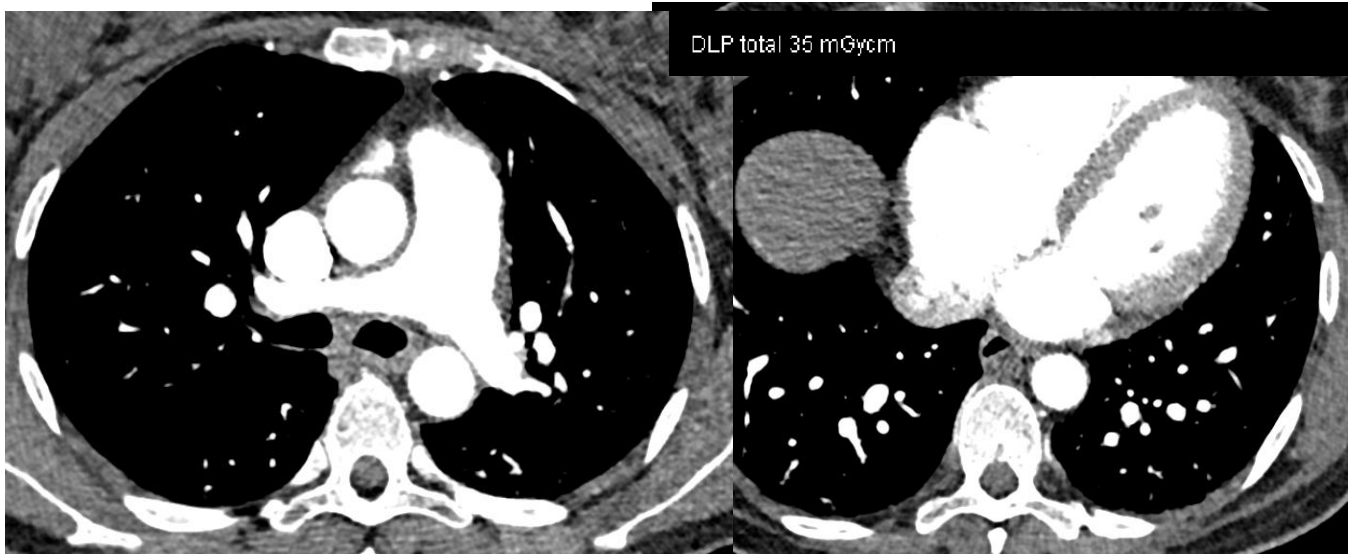

DONNEES DU COMPTE-RENDU QUAND POSITIF

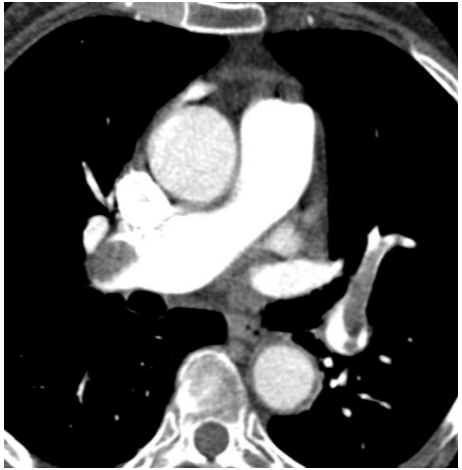

- Uni or bilatérale? Proximal or péripherique?
  - EP sous segmentaire: un seul ou plusieurs territoires?

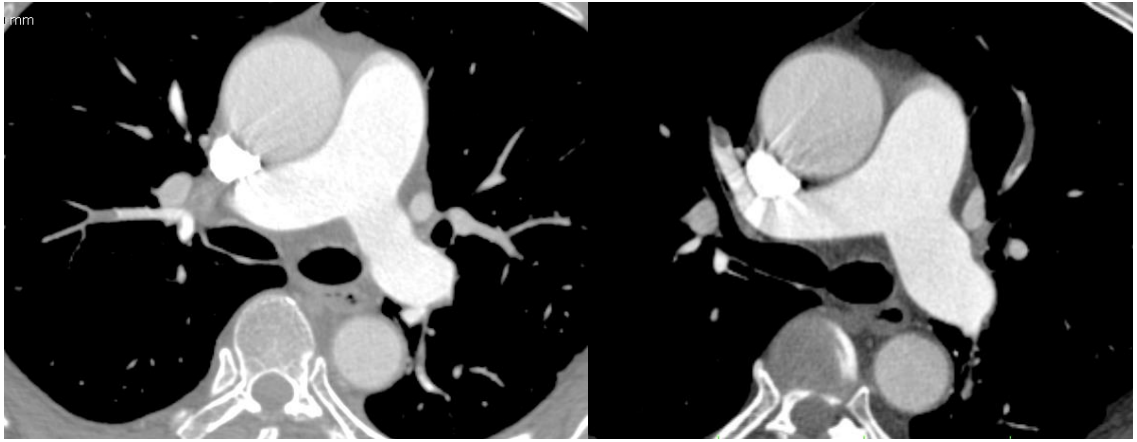

DONNEES DU COMPTE-RENDU QUAND POSITIF

- TAILLE DU VD?
  - Rv/Lv ratio > 0.9 higher mortality rate
    - *(Schoepf, Circulation 2004)*

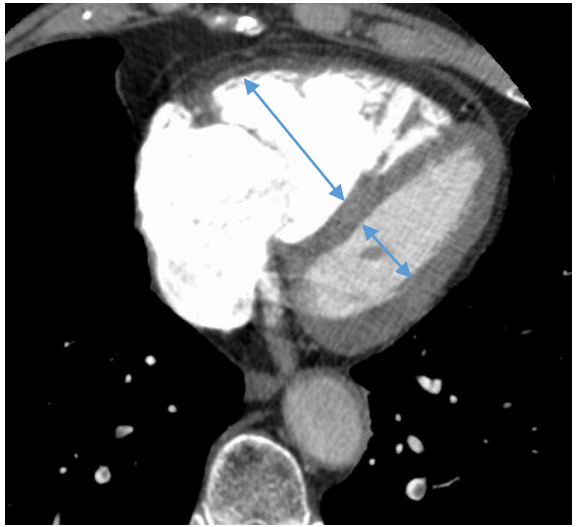

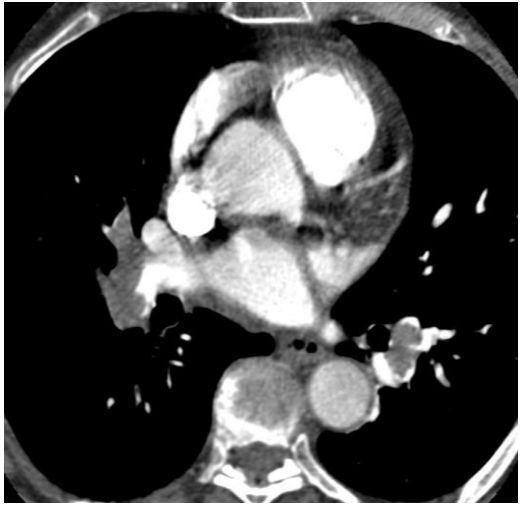

EXAMENS INCONCLUSIFS

- Artéfacts, mauvaise opacification

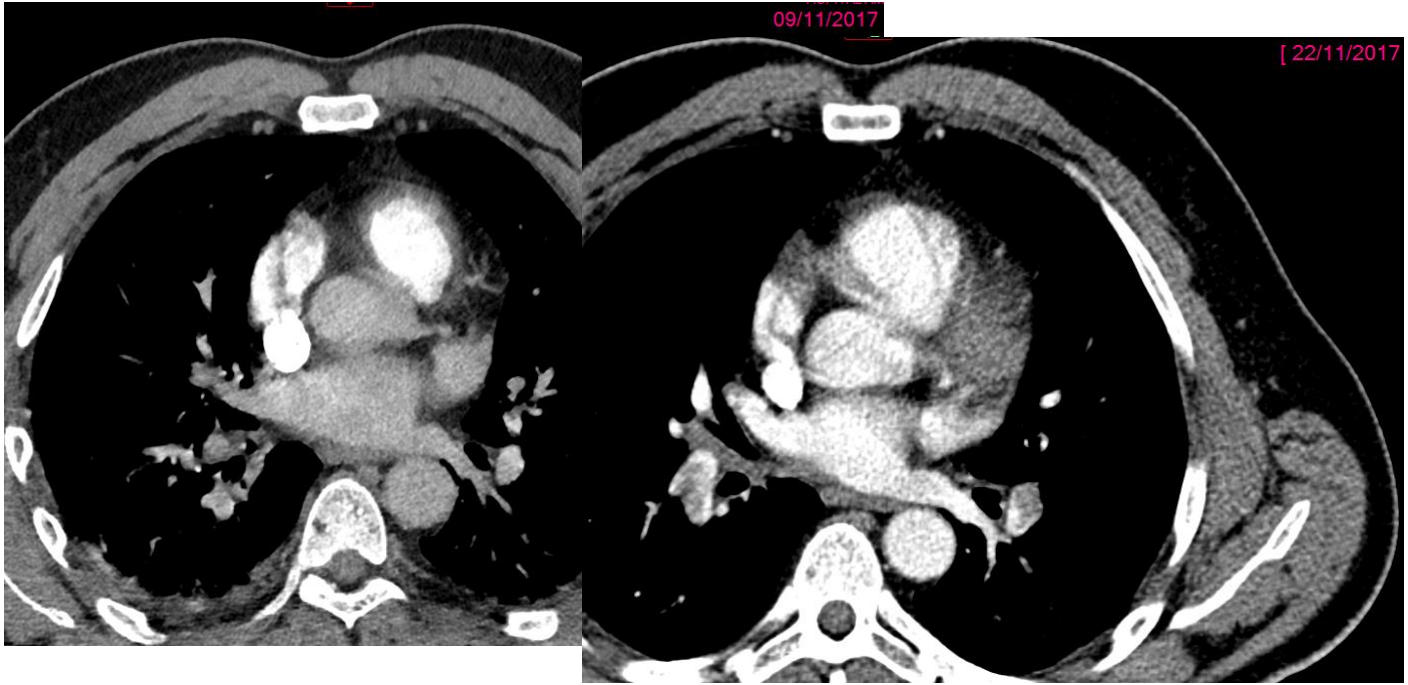

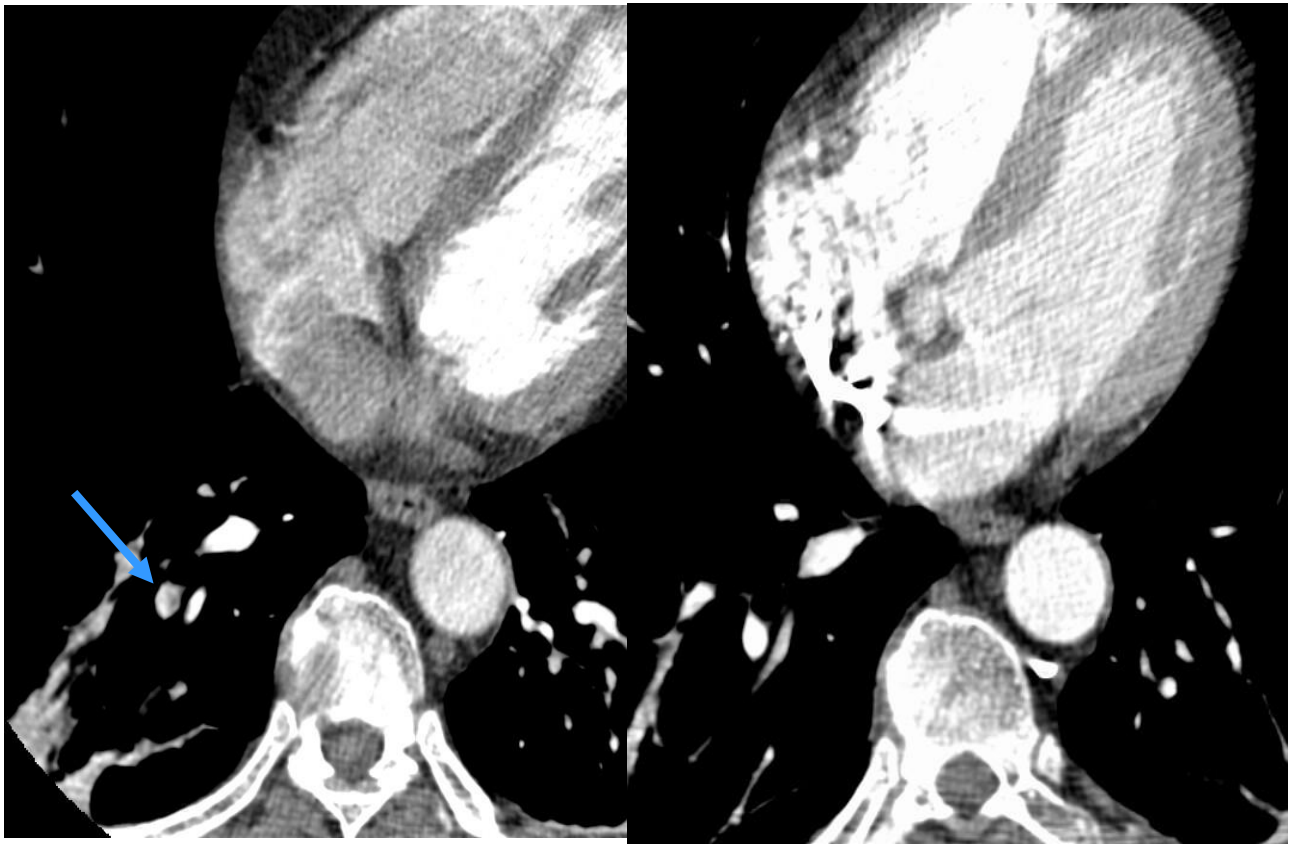

- INFARCTUS: condensation périphérique à base d'implantation pleurale, avec **clartés aériques centrales** (pas de bronchogramme)

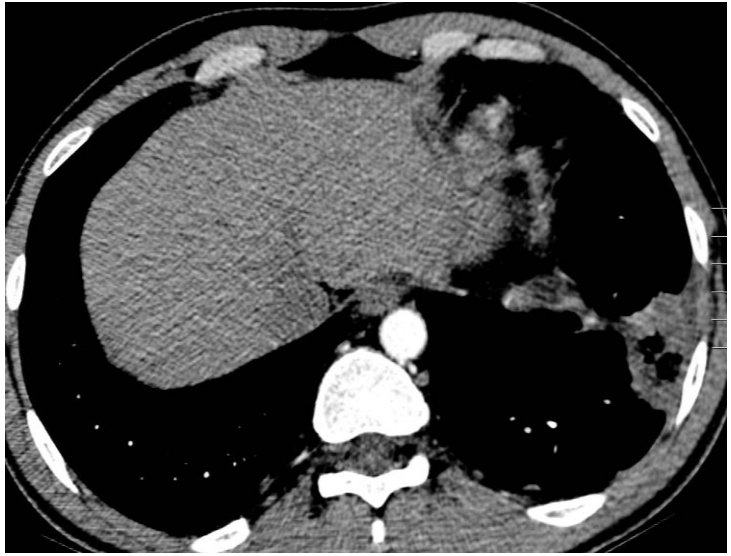

INDICATION A EXPLORATION VEINEUSE EXHAUSTIVE

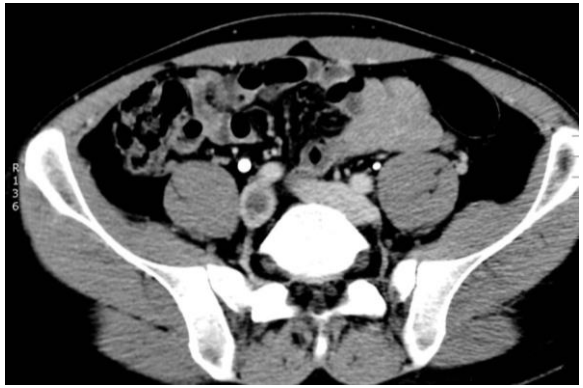

Revel et al Radiology September2007 central air lucencies Odd ratio 23

Objectifs

- Performance de l'angioscanner pour le diagnostic de l'embolie, points importants du compte-rendu
- Sur quels éléments suspecter une forme chronique, un CPCPE
- Revoir les autres causes d'hypertension pulmonaire

Prévalence du CPCPE post EP

↓ 2 à 3% , 5 à 8% chez les patients qui restent dyspnéiques

↓ Conséquence de l'EP aigue?

↓ ou révélation à l'occasion d'un épisode aigu?

7/146 (4.8%), tous ont 2 signes de TEC sur le scanner initial

Prevalence of chronic thromboembolic pulmonary hypertension after acute pulmonary embolism

Thrombosis and Haemostasis 112.3/2014

Prevalence of CTEPH after pulmonary embolism

Laurent Guérin[1]; Francis Couturaud[2]; Florence Parent[3]; Marie-Pierre Revel[4]; Florence Gillaizeau[5]; Benjamin Planquette[1]; Daniel Pontal[1]; Marie Guégan[2]; Gérald Simonneau[3]; Guy Meyer[1,6]; Olivier Sanchez[1,6]

Patiente adressée pour suspicion d'embolie pulmonaire

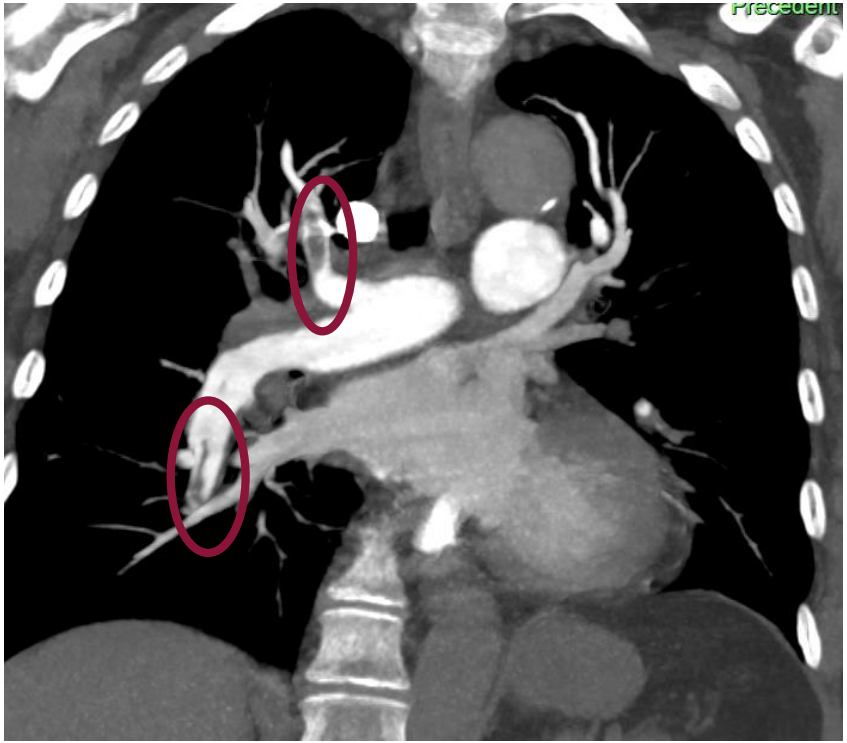

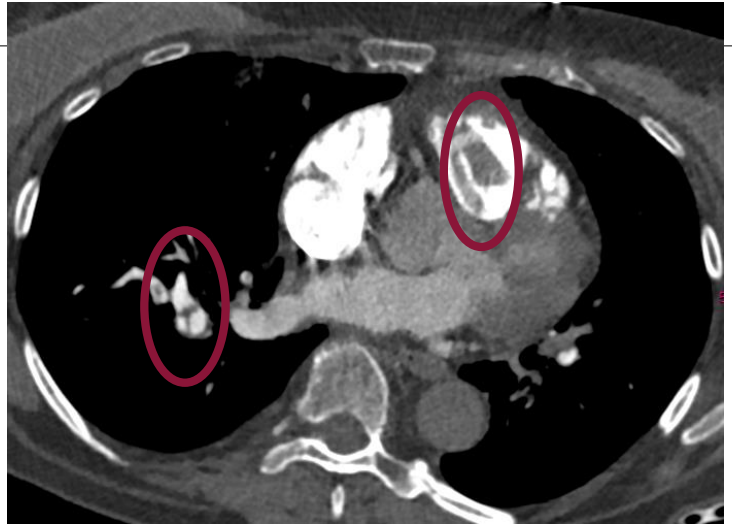

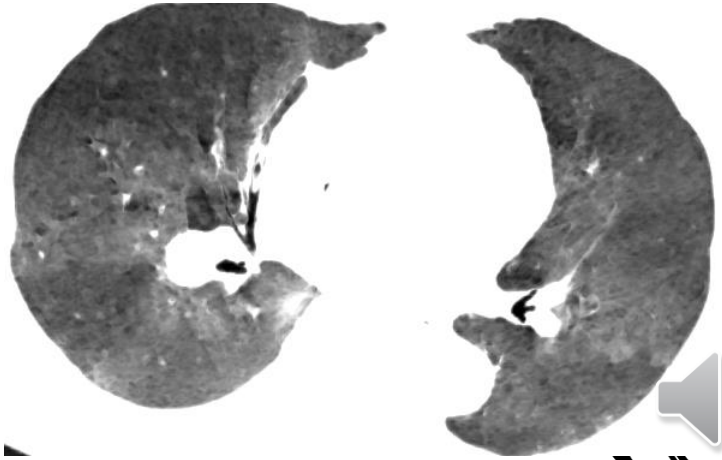

Comment reconnaitre une TEC/ CPCPE en angioscanner spiralé?

↓Association de signes d'hypertension pulmonaire &

1. Signes de thrombose artérielle pulmonaire chronique
2. Hypervascularisation systémique
3. Perfusion mosaïque

Signes d'hypertension pulmonaire

- **VASCULAIRES**
- Dilatation (≥29 mm) du tronc pulmonaire: Se, sp 87, 89%
- Rapport AP/Aorte ≥1: VPP 96%, SP 92%

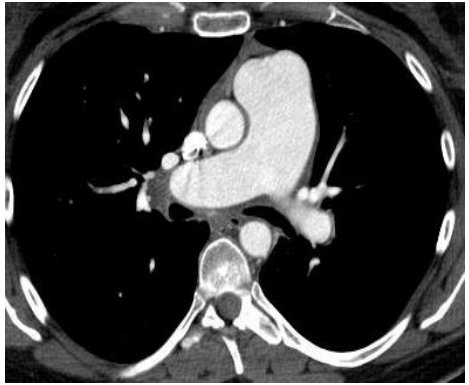

Tan et al Chest 1998

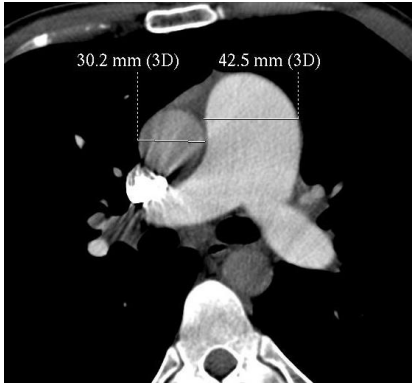

Ng CS et al. J Thorac Imaging 1999

Signes d’hypertension pulmonaire

- **CARDIAQUES**
- **Hypertrophie ventriculaire droite**
  - Paroi libre du VD ≥ 4 mm
- Dilatation VD (VD/VG≥ 1)
- Anomalie de courbure septale
- Reflux de contraste dans la VCI et les veines sus hépatiques

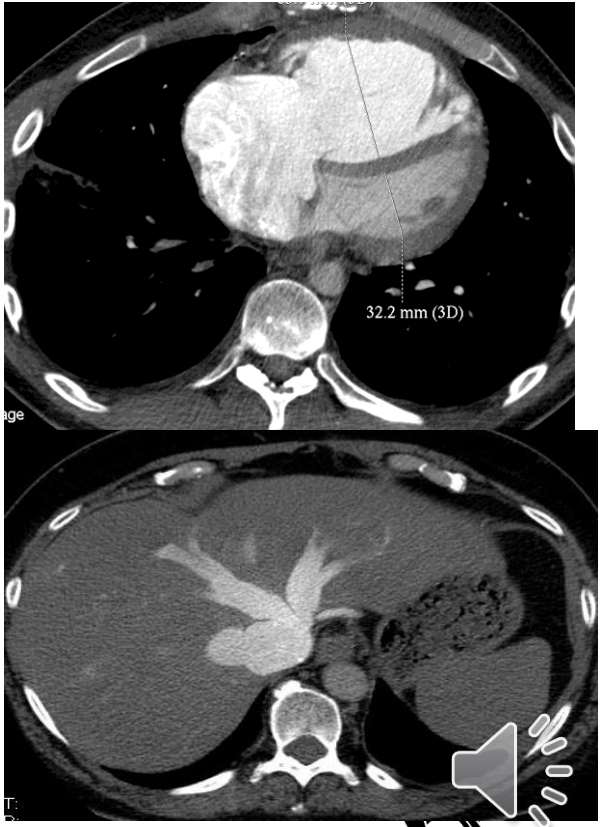

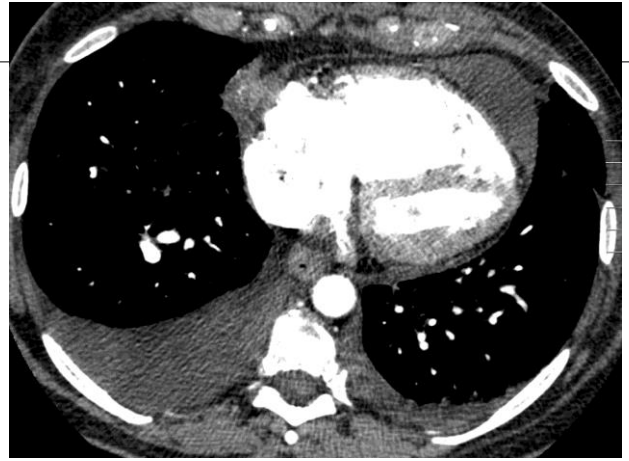

- Epanchements (pleural, péricardique)
- Réouverture du foramen ovale(cas sévères)

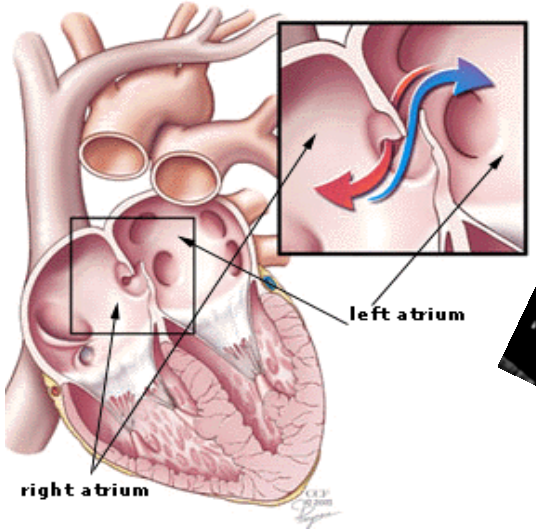

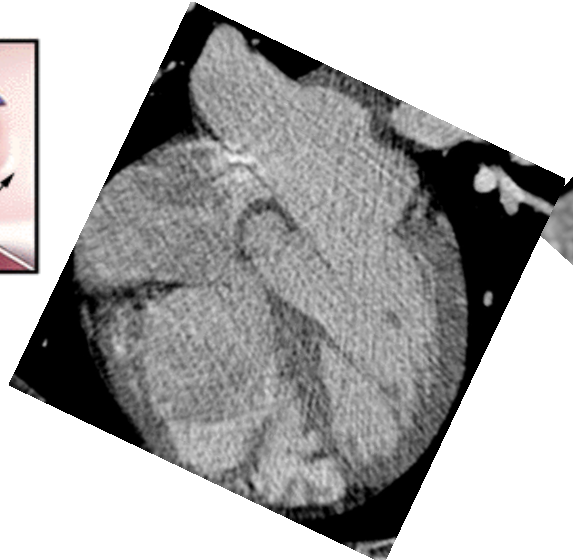

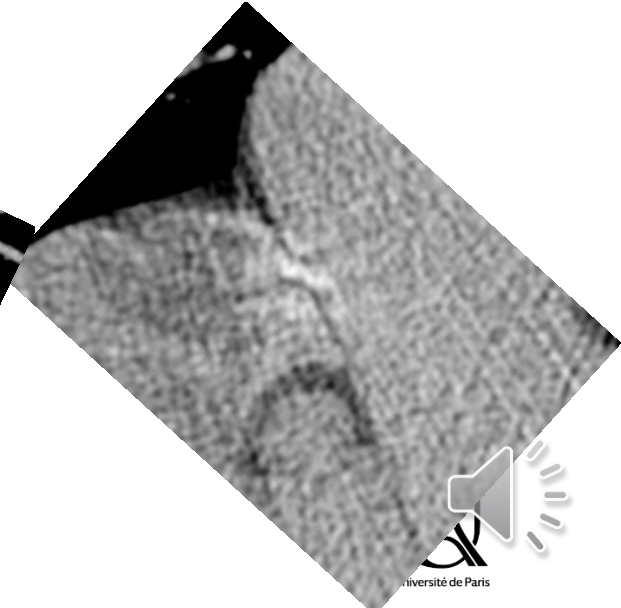

Université Paris Cité

Triade suggérant une cause post embolique à l'hypertension pulmonaire

1- Signes de thrombose artérielle pulmonaire chronique

rétraction artérielle

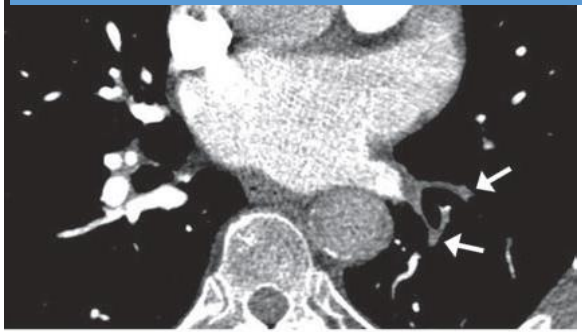

Thrombi marginés

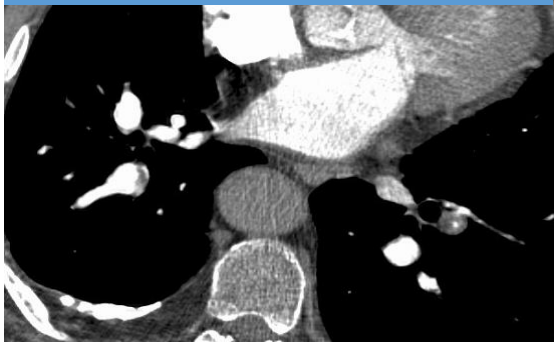

Sténoses artérielles

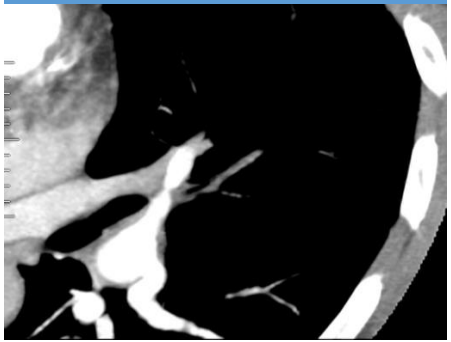

Pouching defect

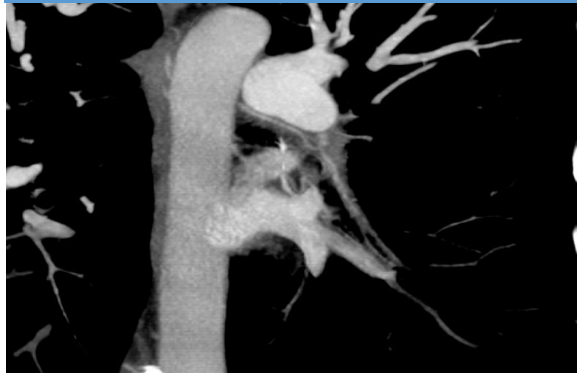

Band

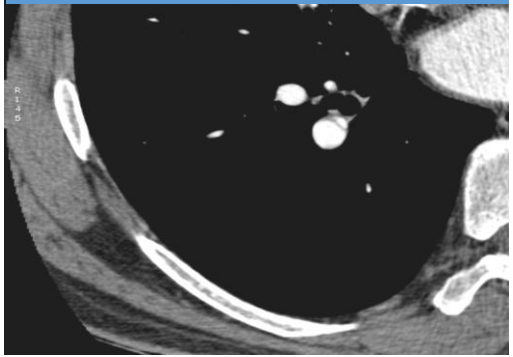

Web

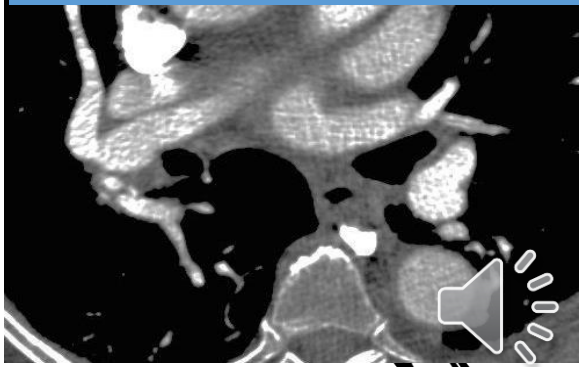

Les thrombi marginés sont parfois calcifiés

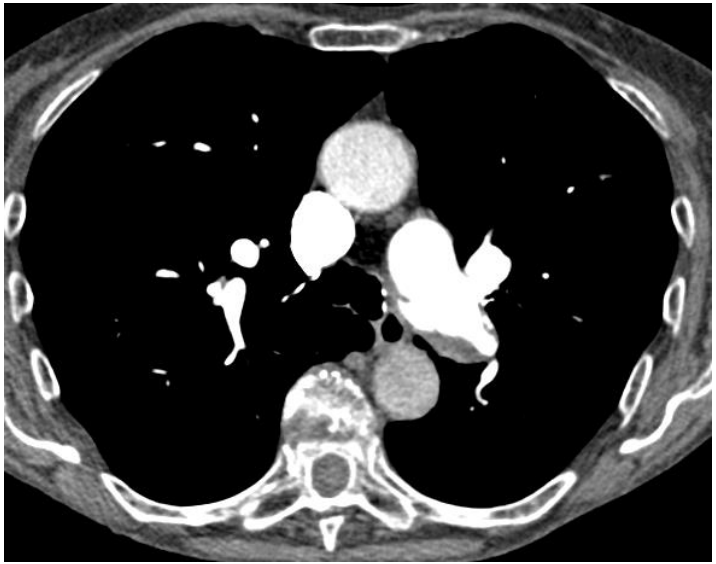

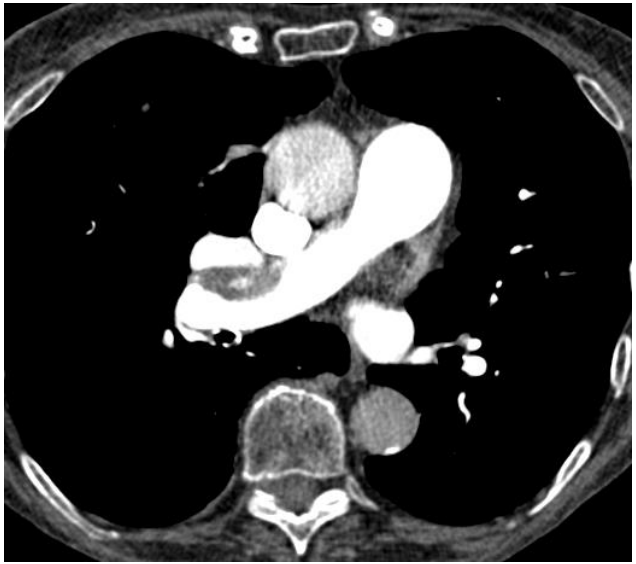

2- Hypervascularisation systémique

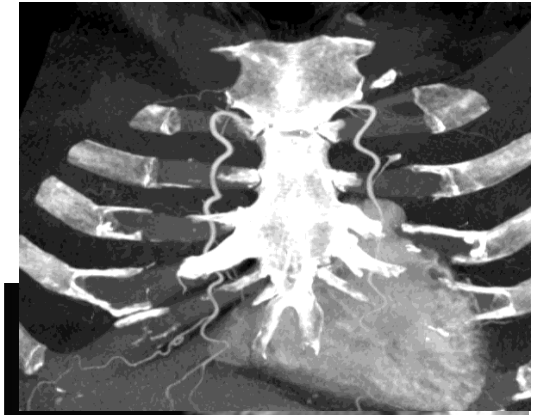

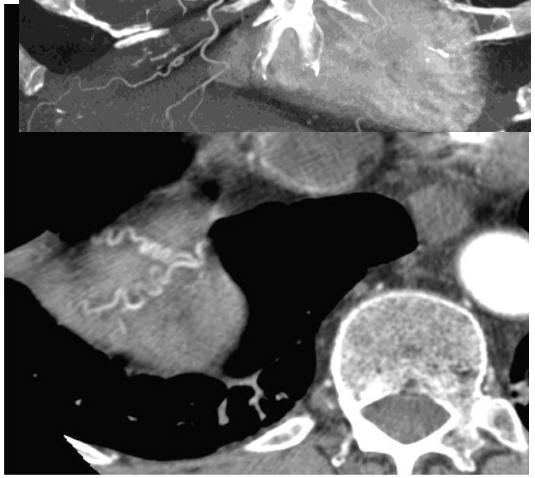

artère phrénique /mammaire interne

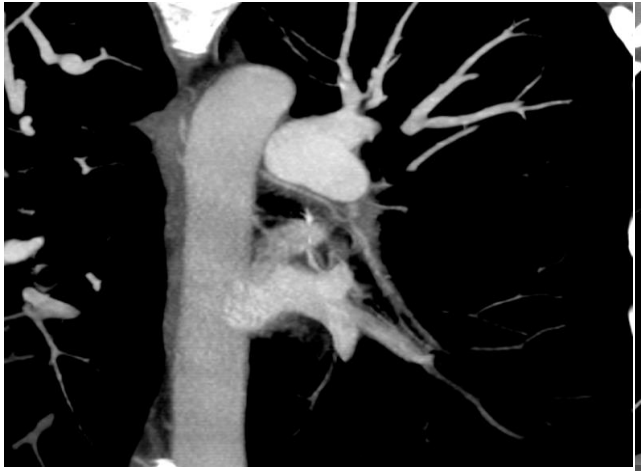

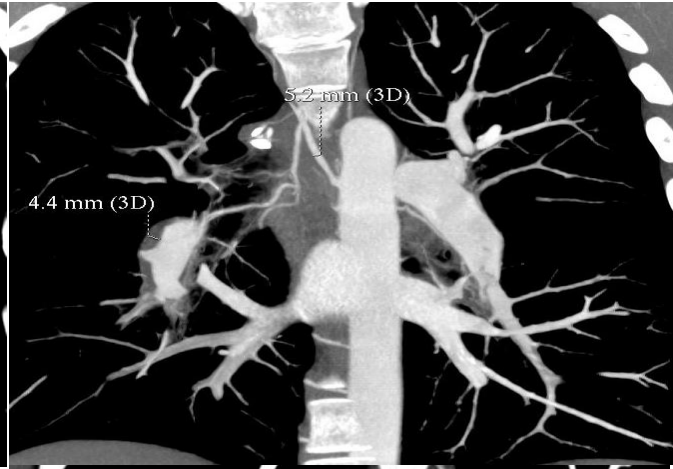

Artères bronchiques

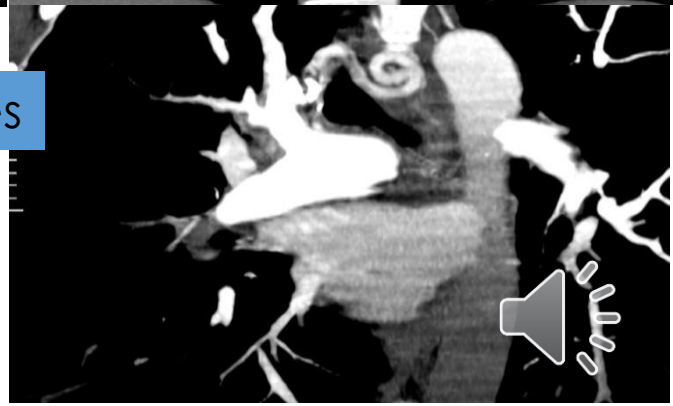

3- Perfusion mosaïque (se voit sans injection)

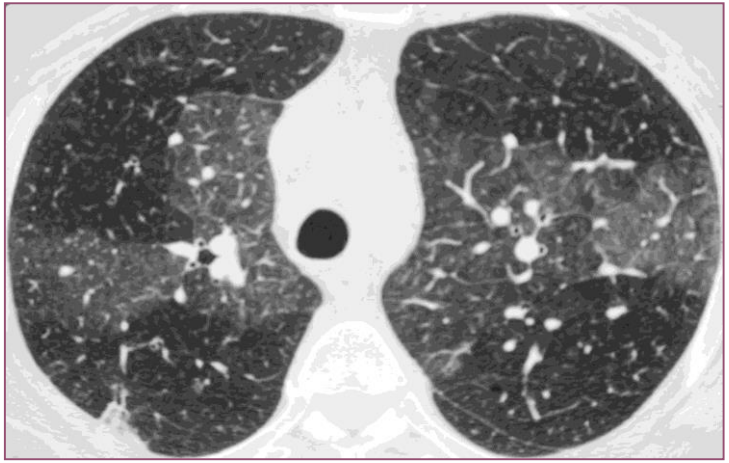

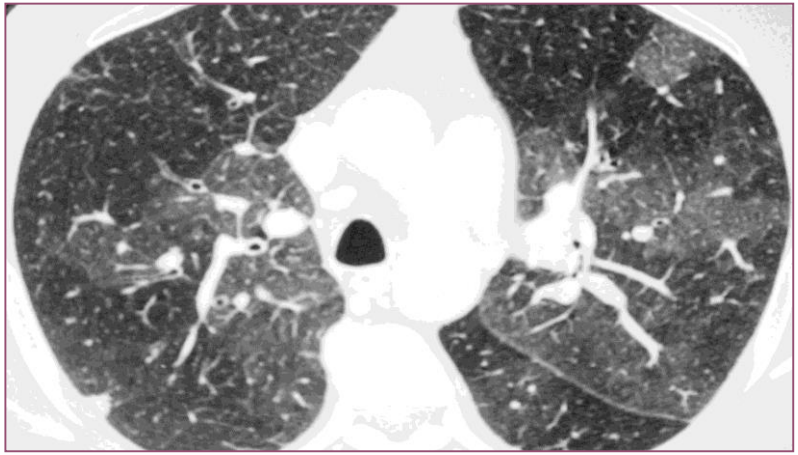

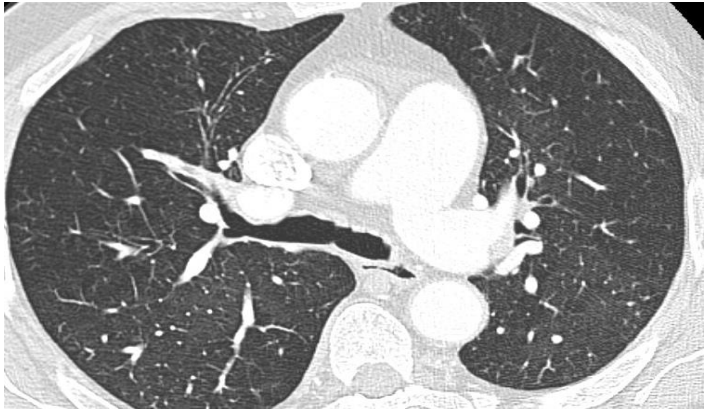

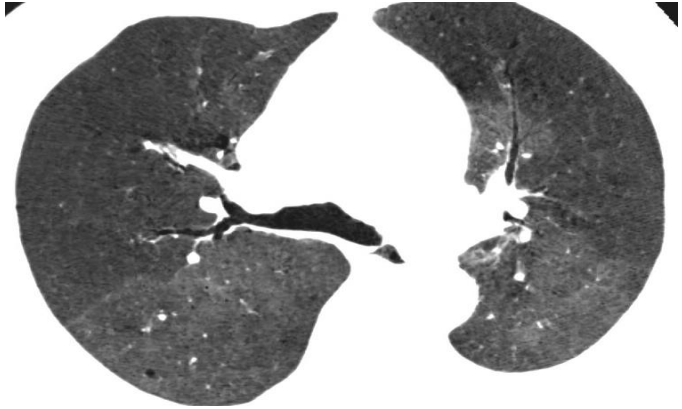

Angioscanner spiralé double énergie

- Peut être utilisé pour évaluer la perfusion pulmonaire
- Mais le minIP suffit la plupart du temps!

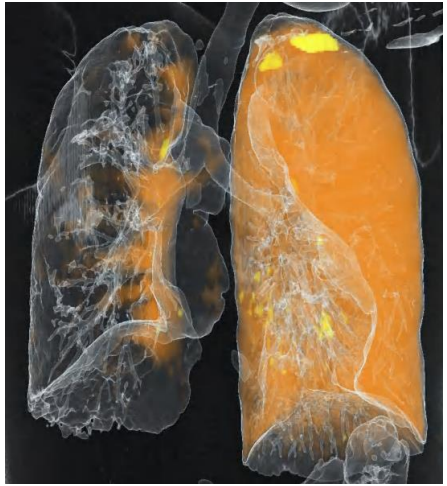

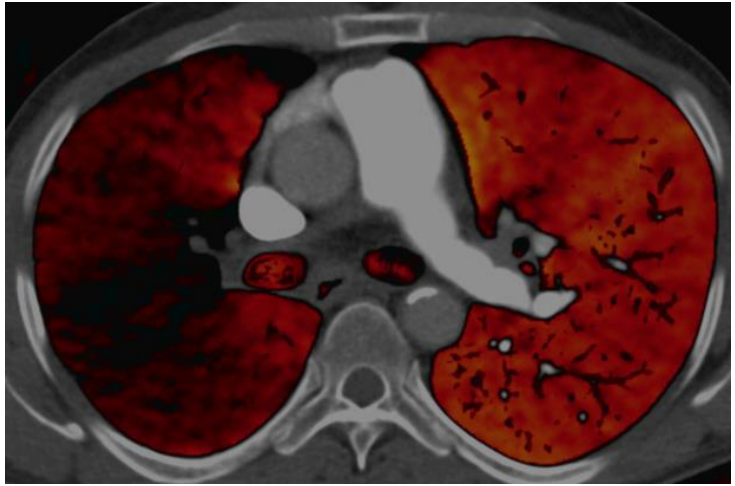

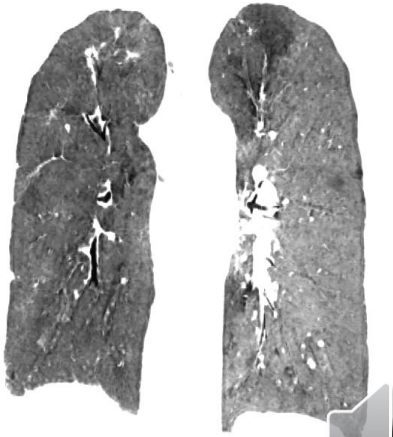

Objectifs

- Performance de l'angioscanner pour le diagnostic de l'embolie, points importants du compte-rendu
- Sur quels éléments suspecter une forme chronique, un CPCPE
- Revoir les autres causes d'hypertension pulmonaire

Updated clinical classification of pulmonary hypertension

6th PH World Symposium Nice, Fr –2018

Eur Respir J. 2019 Jan; 53(1): 1801913

1 PAH

PAH: Pulmonary arterial hypertension

1.1 Idiopathic PAH

1.2 Heritable PAH

1.3 Drug- and toxin-induced PAH (table 3)

1.4 PAH associated with:

1.4.1 Connective tissue disease

1.4.2 HIV infection

1.4.3 Portal hypertension

1.4.4 Congenital heart disease

1.4.5 Schistosomiasis

1.5 PAH long-term responders to calcium channel blockers (table 4)

1.6 PAH with overt features of venous/capillaries (PVOD/PCH) involvement (table 5)

1.7 Persistent PH of the newborn syndrome

2 PH due to left heart disease

2.1 PH due to heart failure with preserved LVEF

2.2 PH due to heart failure with reduced LVEF

2.3 Valvular heart disease

2.4 Congenital/acquired cardiovascular conditions leading to post-capillary PH

3 PH due to lung diseases and/or hypoxia

3.1 Obstructive lung disease

3.2 Restrictive lung disease

3.3 Other lung disease with mixed restrictive/obstructive pattern

3.4 Hypoxia without lung disease

3.5 Developmental lung disorders

4 PH due to pulmonary artery obstructions (table 6)

4.1 Chronic thromboembolic PH

4.2 Other pulmonary artery obstructions

5 PH with unclear and/or multifactorial mechanisms (table 7)

5.1 Haematological disorders

5.2 Systemic and metabolic disorders

5.3 Others

5.4 Complex congenital heart disease

Idiopathic , inherited, due to HIV or anorexigens

- **NO SPECIFIC CT FEATURES:** only vascular and cardiac signs

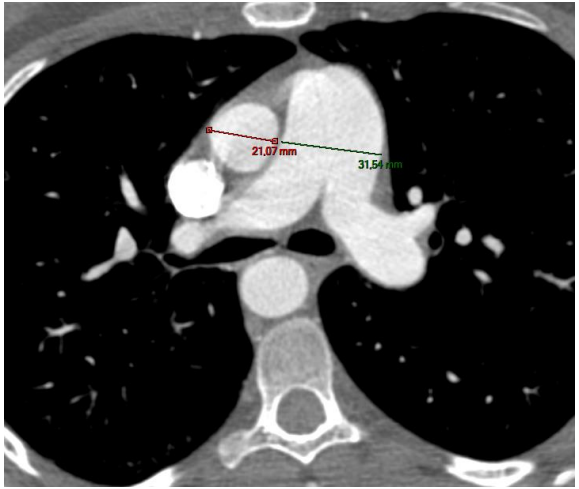

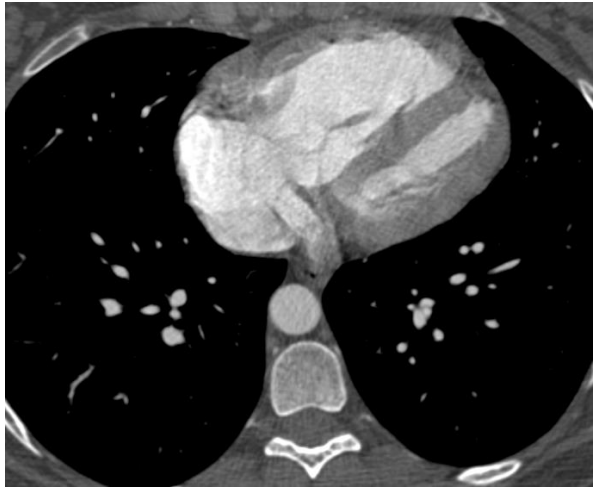

Heritable PAH in a 30-yo-woman

1 PAH
- 1.1 Idiopathic PAH
- 1.2 Heritable PAH
- 1.3 Drug- and toxin-induced PAH (table 3)
- 1.4 PAH associated with:
  - 1.4.1 Connective tissue disease
  - 1.4.2 HIV infection
  - 1.4.3 Portal hypertension
  - 1.4.4 Congenital heart disease
  - 1.4.5 Schistosomiasis
- 1.5 PAH long-term responders to calcium channel blockers (table 4)
- 1.6 PAH with overt features of venous/capillaries (PVOD/PCH) involvement
- 1.7 Persistent PH of the newborn syndrome

HIV related PH

Indirect role of the virus (HIV-related proteins) & genetic susceptibility (HLA-DR6 and HLA-DR52)
Persists despite antiretroviral therapy - Requires PAH-specific therapy

1 PAH

- 1.1 Idiopathic PAH
- 1.2 Heritable PAH
- 1.3 Drug- and toxin-induced PAH (table 3)
- 1.4 PAH associated with:
  - 1.4.1 Connective tissue disease
  - 1.4.2 HIV infection
  - 1.4.3 Portal hypertension
  - 1.4.4 Congenital heart disease
  - 1.4.5 Schistosomiasis
- 1.5 PAH long-term responders to calcium channel
- 1.6 PAH with overt features of venous/capillaries (
- 1.7 Persistent PH of the newborn syndrome

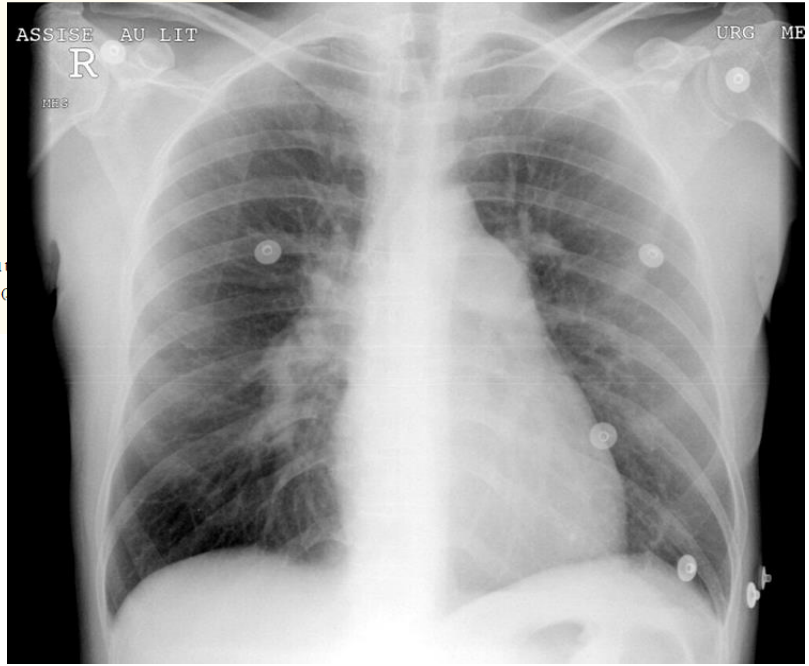

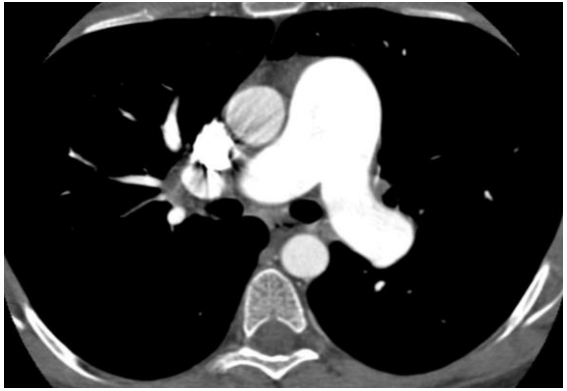

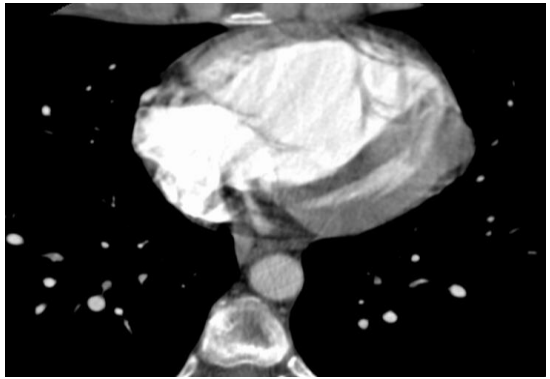

37 YO woman, HIV infection, no treatment nor F/u

Congenital heart disease (Einsenmenger)

1 PAH

- 1.1 Idiopathic PAH
- 1.2 Heritable PAH
- 1.3 Drug- and toxin-induced PAH (table 3)
- 1.4 PAH associated with:
  - 1.4.1 Connective tissue disease
  - 1.4.2 HIV infection
  - 1.4.3 Portal hypertension
  - 1.4.4 Congenital heart disease
  - 1.4.5 Schistosomiasis
- 1.5 PAH long-term responders to calcium channel blockers (table 4)
- 1.6 PAH with overt features of venous/capillaries (PVOD/PCH) involvement (table 5)
- 1.7 Persistent PH of the newborn syndrome

Initially left-to-right shunt: mainly ventricular septal defect

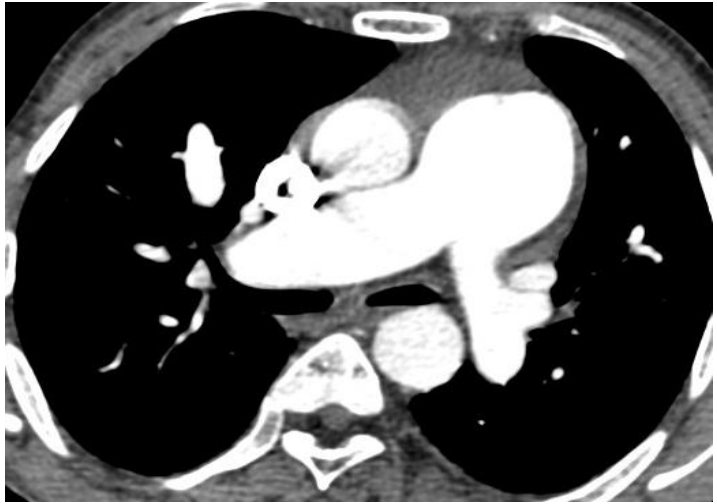

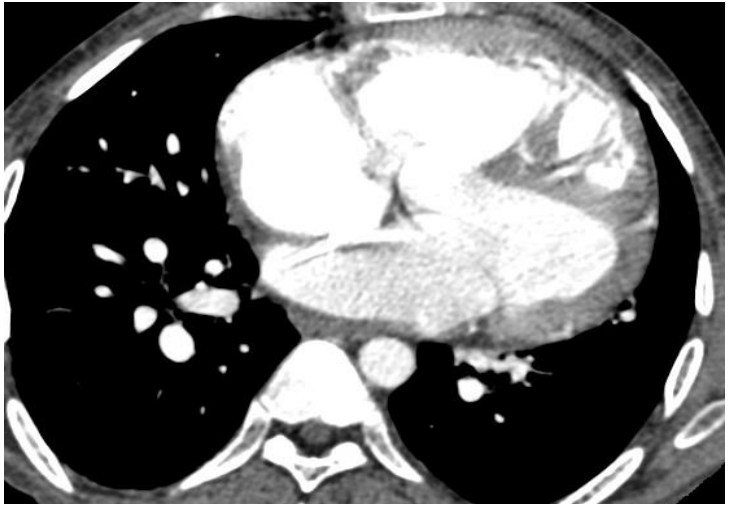

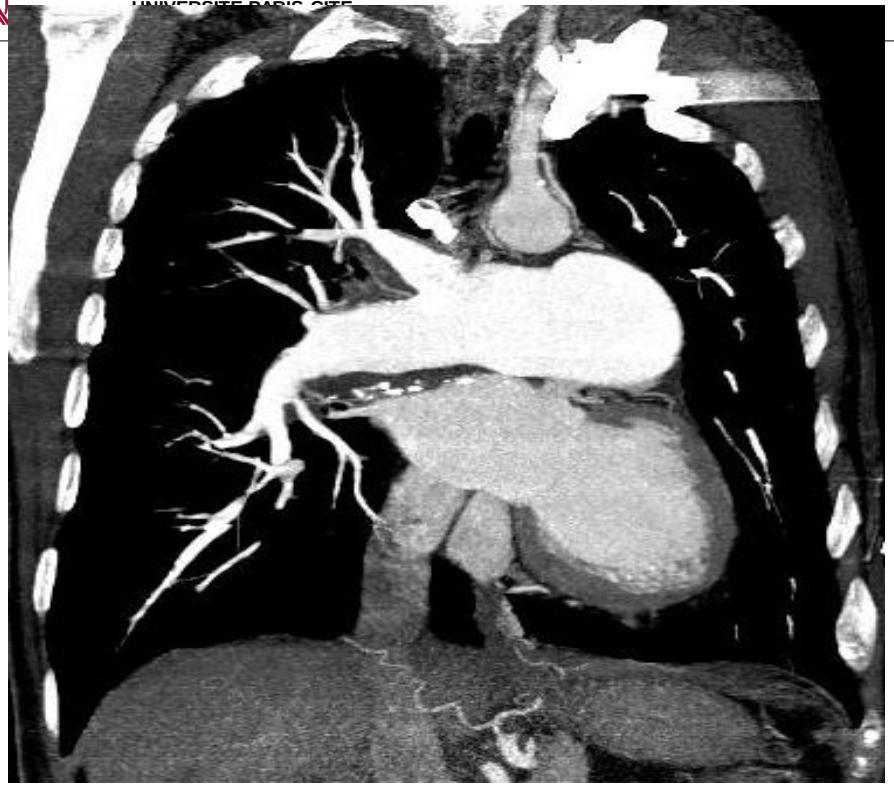

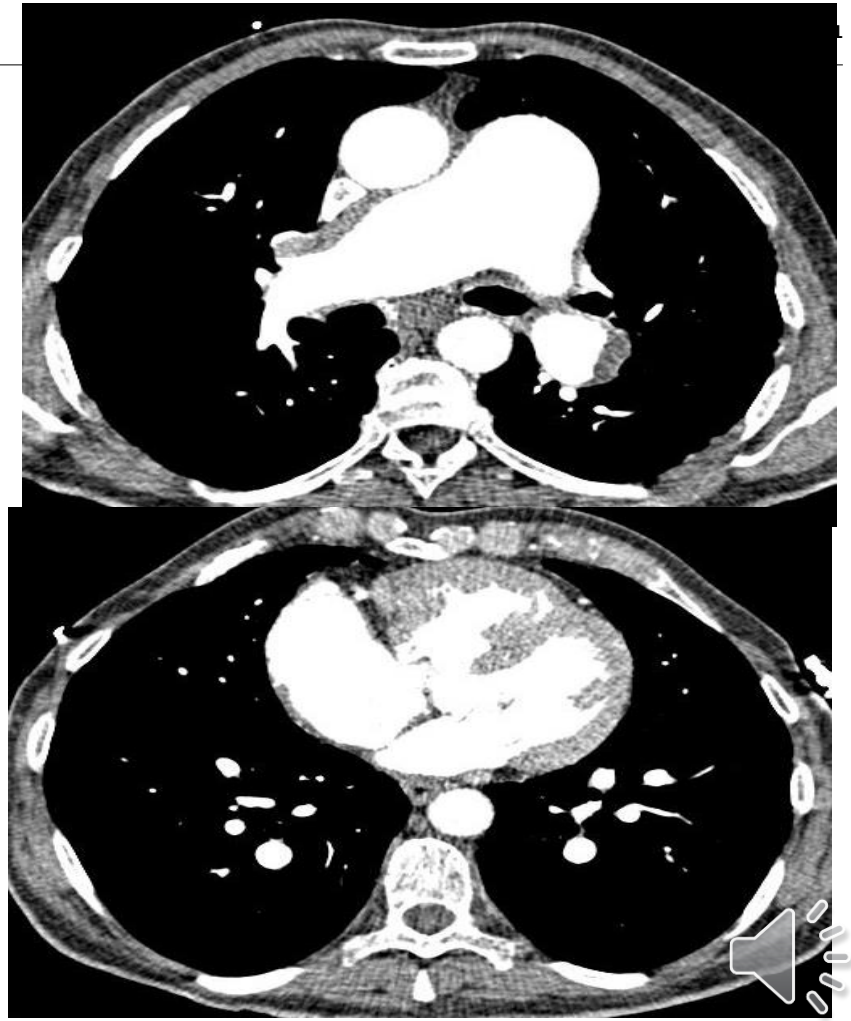

- CIA

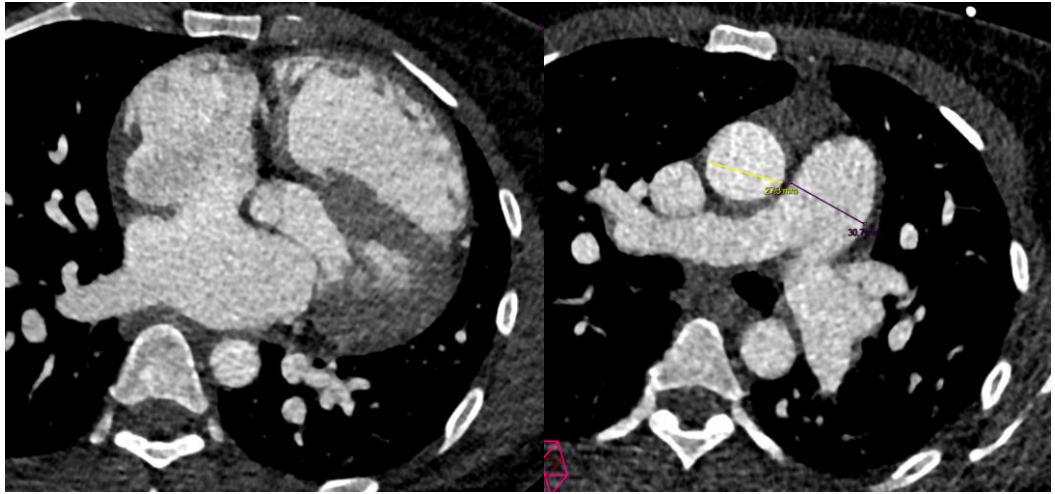

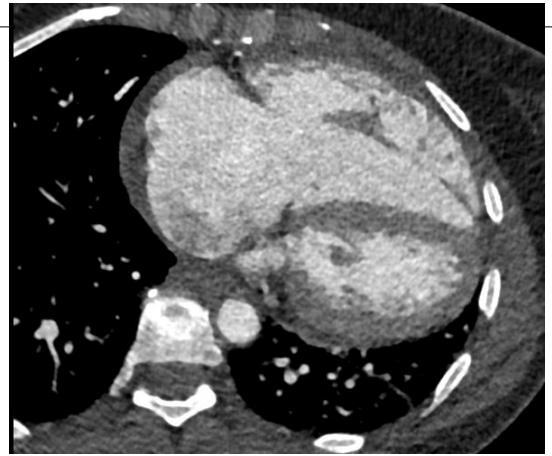

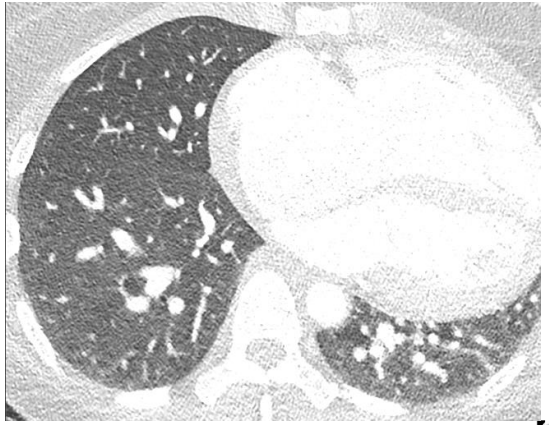

PVOD and PCH

1 PAH

- 1.1 Idiopathic PAH
- 1.2 Heritable PAH
- 1.3 Drug- and toxin-induced PAH (table 3)
- 1.4 PAH associated with:
  - 1.4.1 Connective tissue disease
  - 1.4.2 HIV infection
  - 1.4.3 Portal hypertension
  - 1.4.4 Congenital heart disease
  - 1.4.5 Schistosomiasis
- 1.5 PAH long-term responders to calcium channel blockers (table 4)
- 1.6 PAH with overt features of venous/capillaries (PVOD/PCH) involvement (table 5)
- 1.7 Persistent PH of the newborn syndrome

Rare, difficult to diagnose
But no room for error!

Patients with these conditions may develop fatal pulmonary edema if they are treated with vasodilator agents …

PVOD(pulmonary veno- occlusive disease)

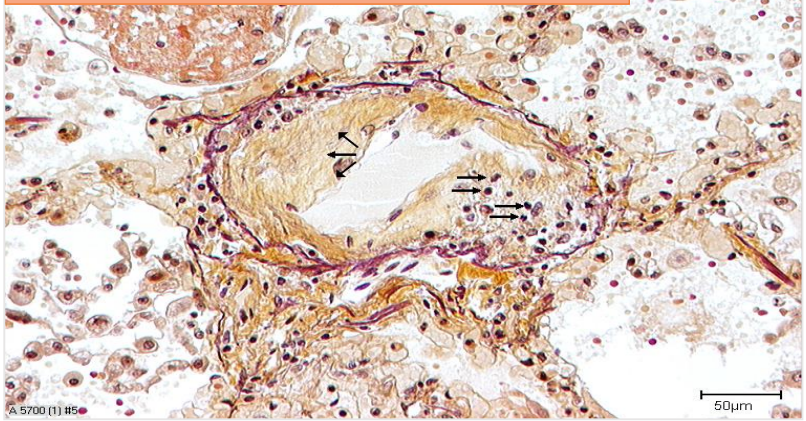

Obliteration of the post capillary veins

PCH (pulmonary capillary hemangiomatosis)

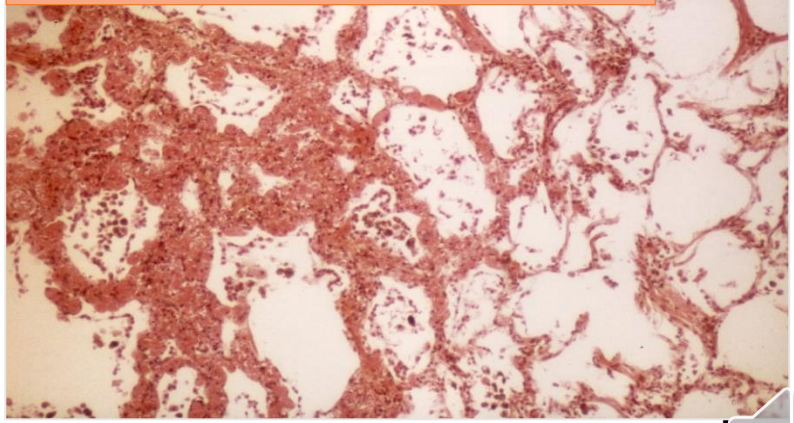

Alveolar capillary proliferation

PVOD (pulmonary veno- occlusive disease)

- ≈ Pulmonary edema+ signs of PH
  - Thickened interlobular septa
  - Poorly defined centrilobular ground-glass nodules
  - Pleural effusion
  - Lymphadenopathy

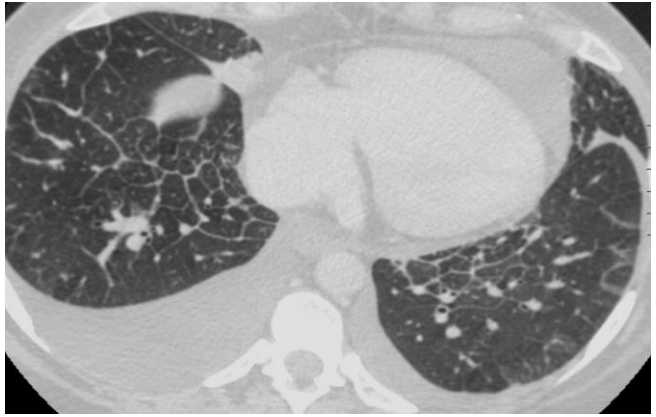

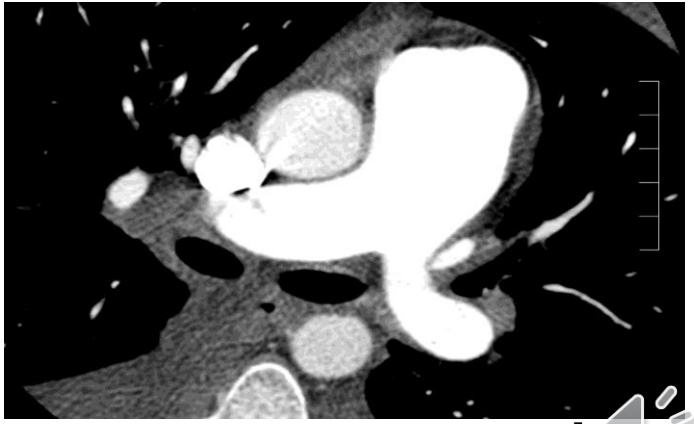

And small pulmonary veins!

Resten A et al Radiology 2002

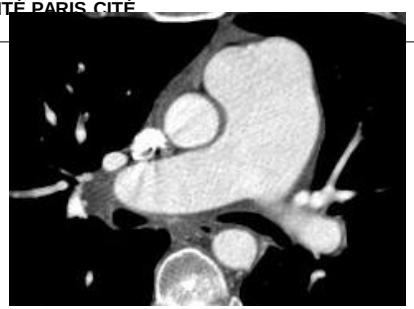

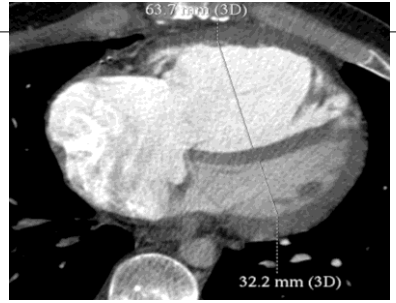

Isolated non specific signs

Idiopathic, Inherited, HIV, anorexigen

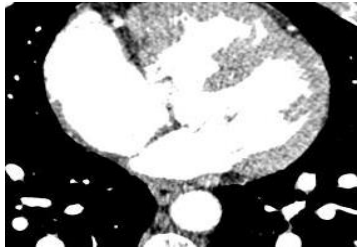

Eisenmenger

specific signs

Key points Group 1 (PAH)

Portal hypertension

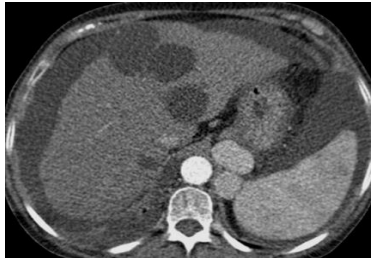

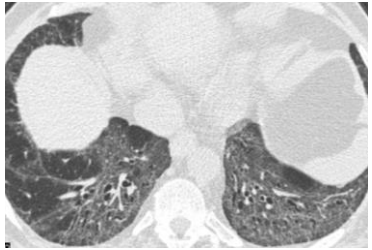

Scc

PVOD

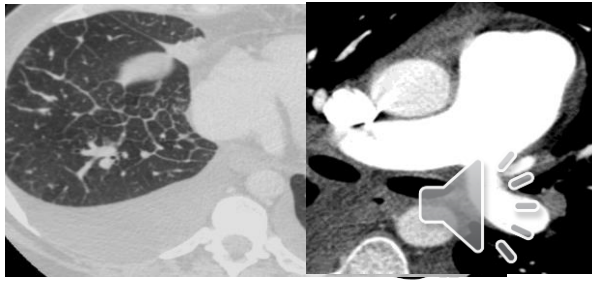

- Pitfall : Isolated signs of PH, make sure it is not CTPEH before concluding idiopathic PH

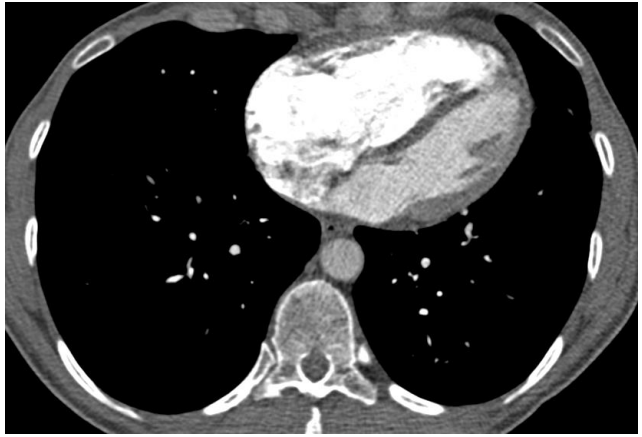

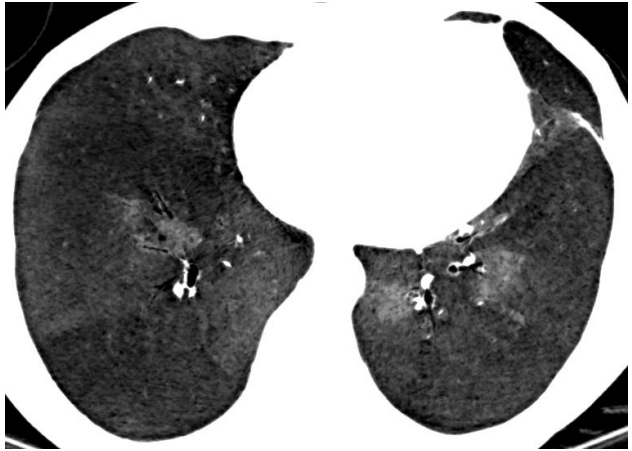

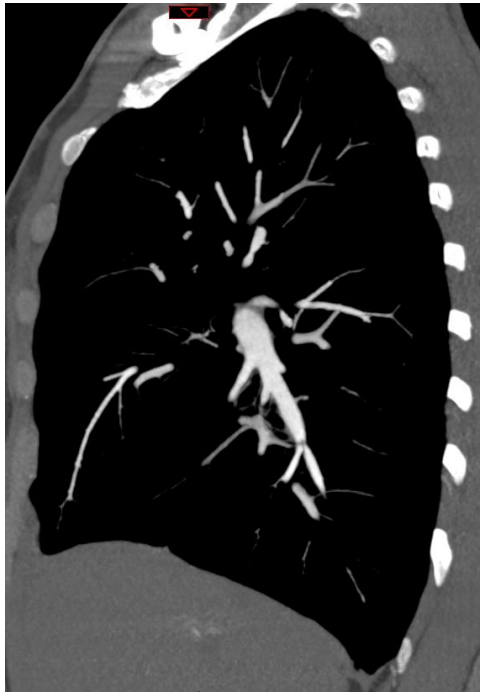

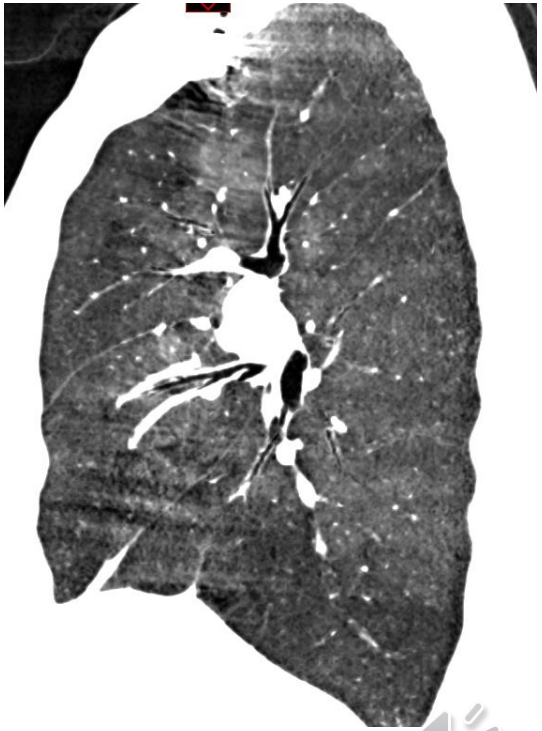

POINTS CLES

- EMBOLIE AGUE
  - Effet délétère de l’inspiration aigue
- CPCPE: 3 signes
  - Occlusion artérielle, hypervascularisation systémique, perfusion mosaique
- HTP
  - Signes non spécifiques: F idiopathique, familiale, HIV, toxique
  - MVO: signes d’HTP + œdème interstitiel+ petites veines centrales

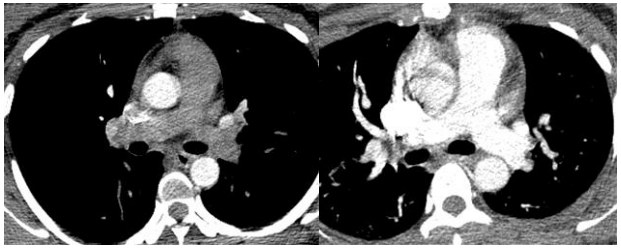

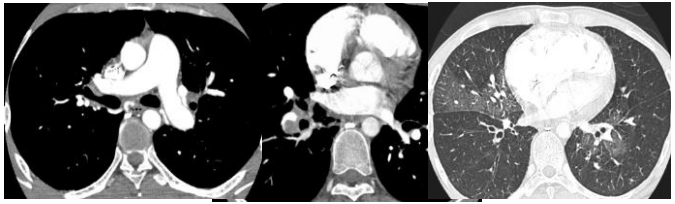

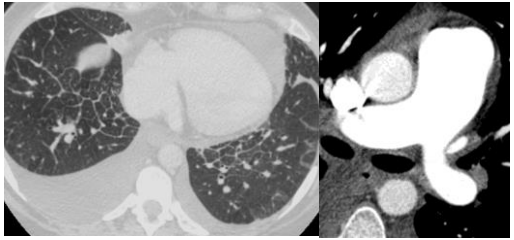

Merci de votre attention