Sémiologie élémentaire des PID

Marie-Pierre Debray

Hôpital Bichat, Paris, France

Séminaire imagerie DES de pneumologie
21 Janvier 2022

Parenchyme normal

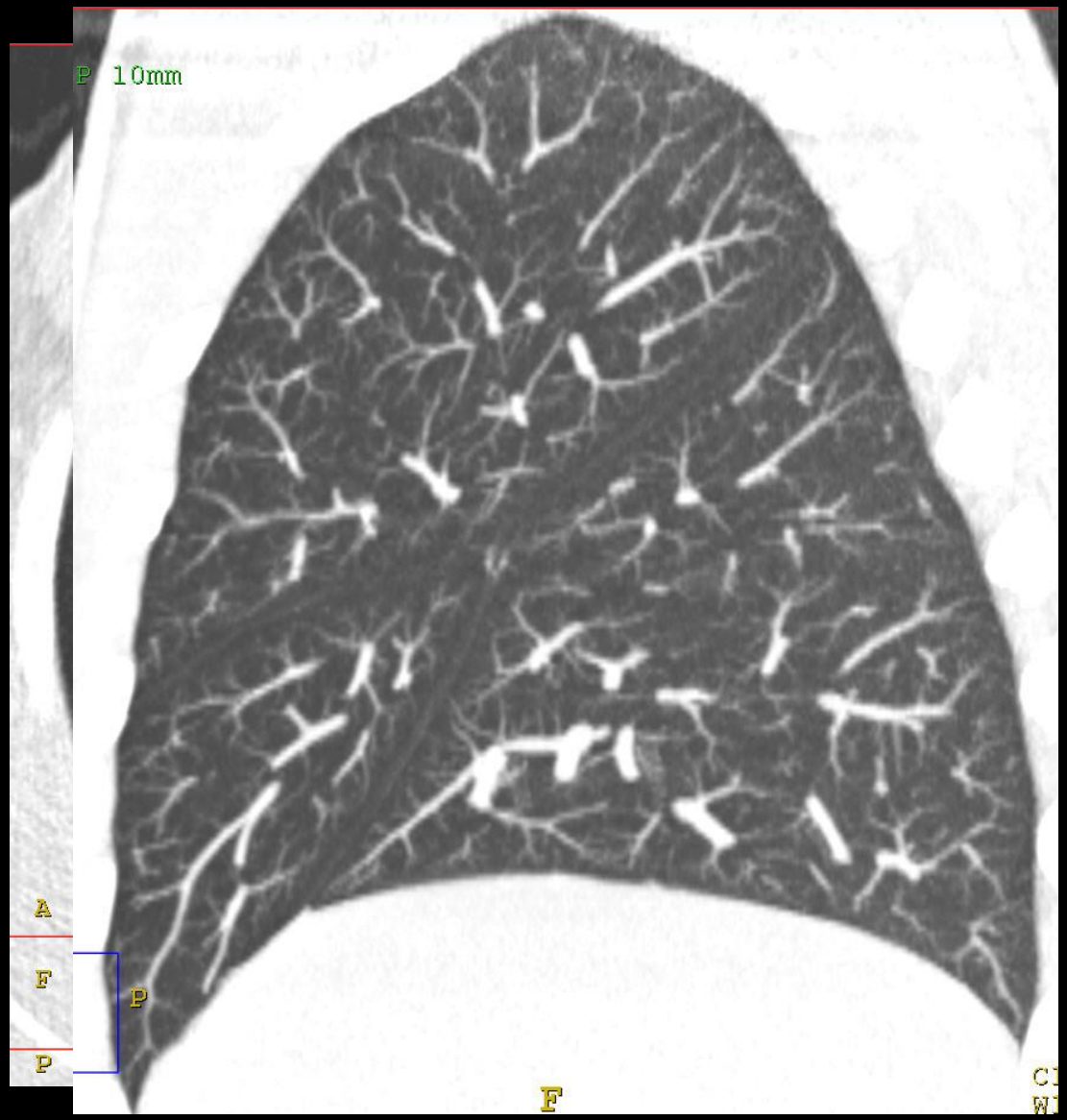

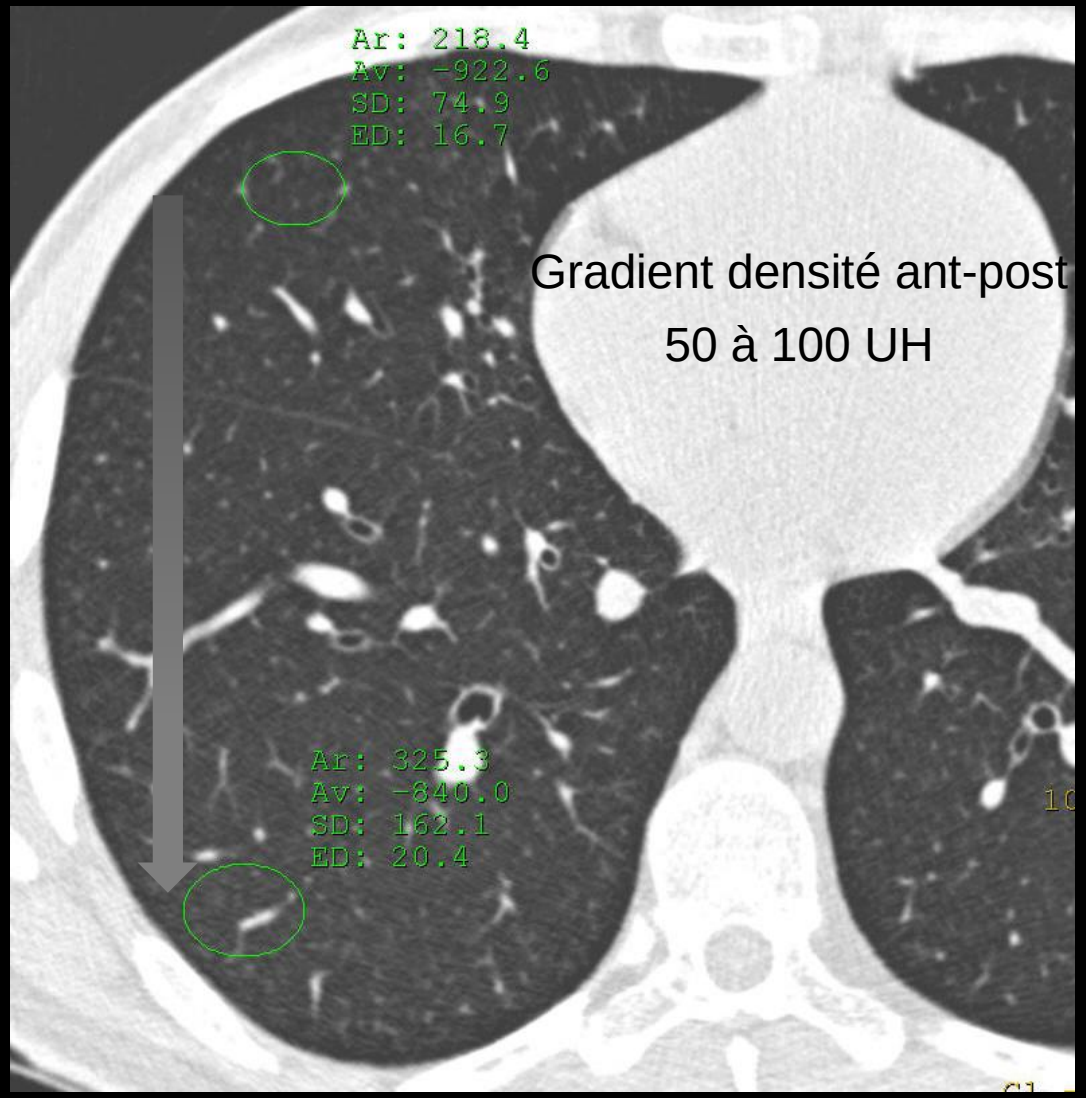

Parenchyme normal en expiration

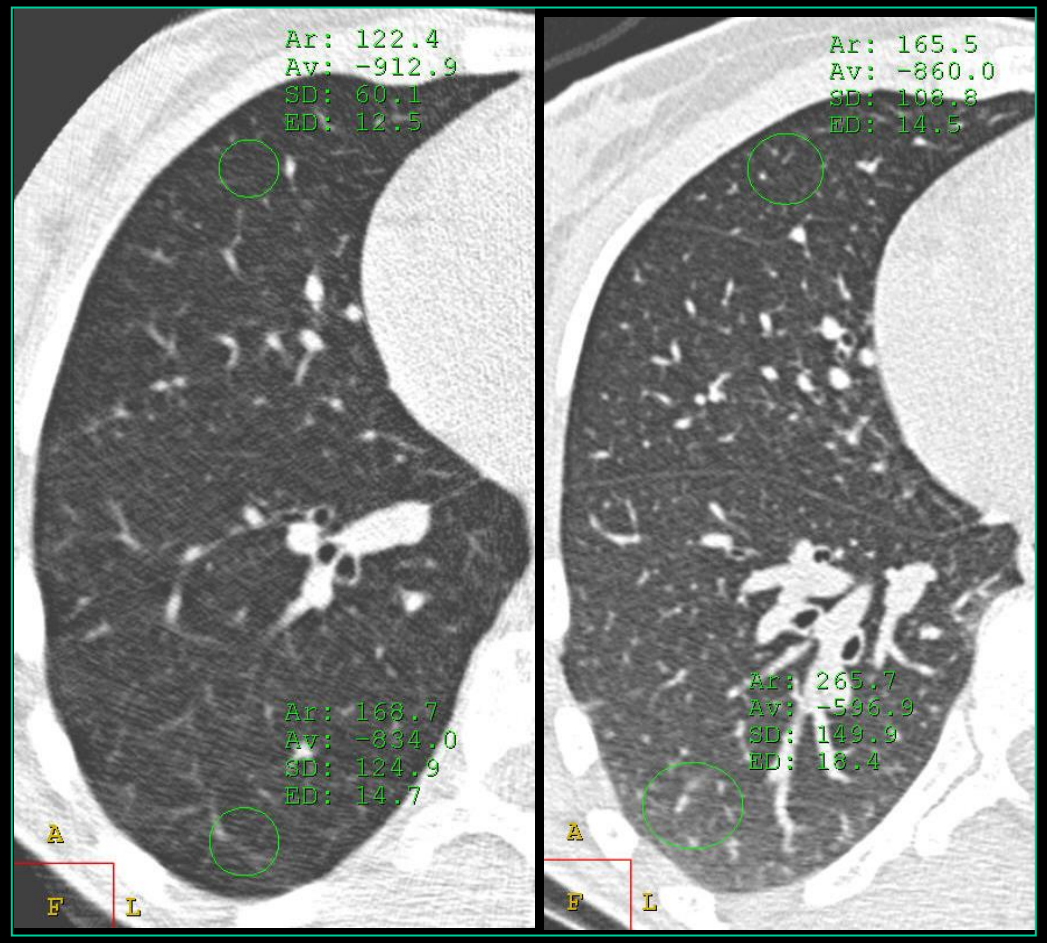

↗ Densité

↗ Gradient densité

Comment reconnaître l'expiration?

Convexité antérieure de la membraneuse trachéale

Anatomie du lobule pulmonaire secondaire

Unité morphologique limitée par septas interlobulaires

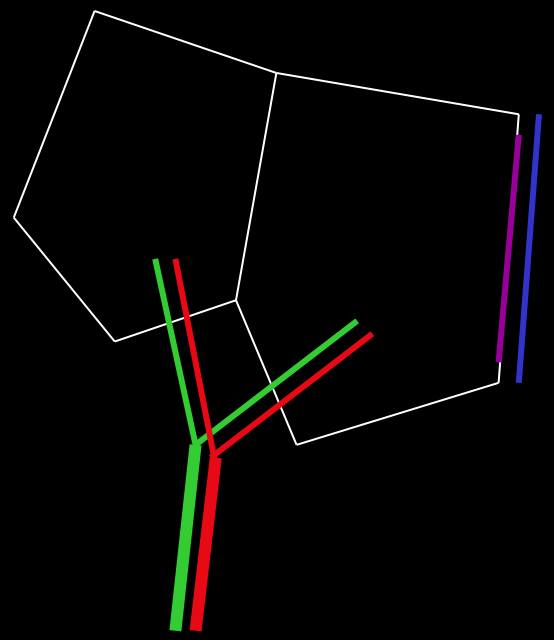

Centre lobule	artériole bronchiole conjonctif
Septa interlobulaires	veines lymphatiques conjonctif

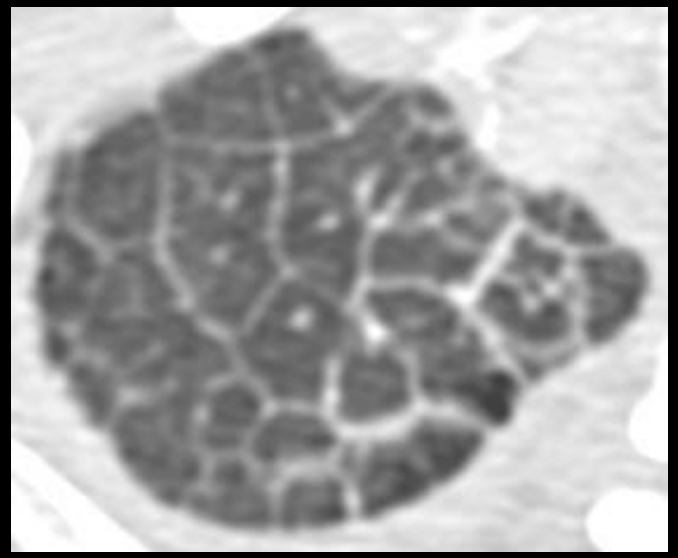

Méthode d'analyse du scanner

Sans injection
< 1,5 mm
Filtre poumon
Inspiration maximale

Scanner thoracique

Qualité ?
Artéfacts ?

Distribution

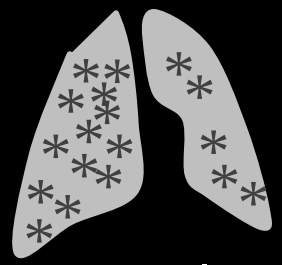

Zonale



Axiale

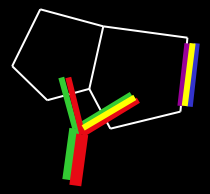

Lobule

Signes élémentaires

- Signe dominant
- Signe associés

Signes de fibrose

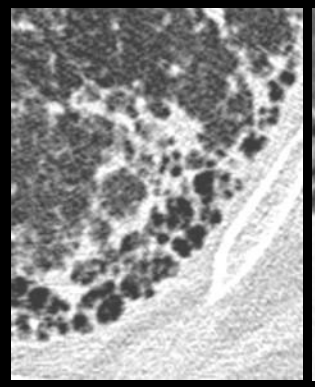

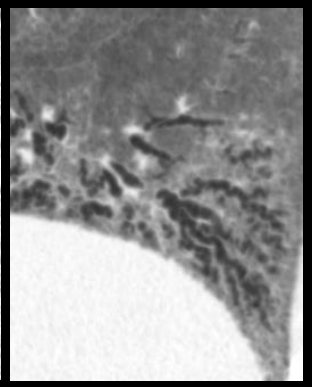

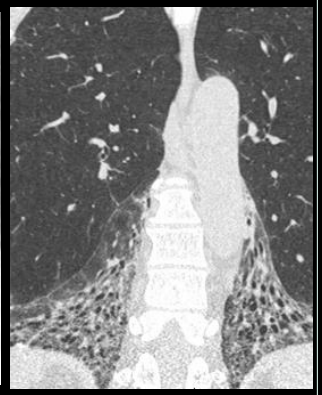

Rayon de miel, bronch. traction, perte volume

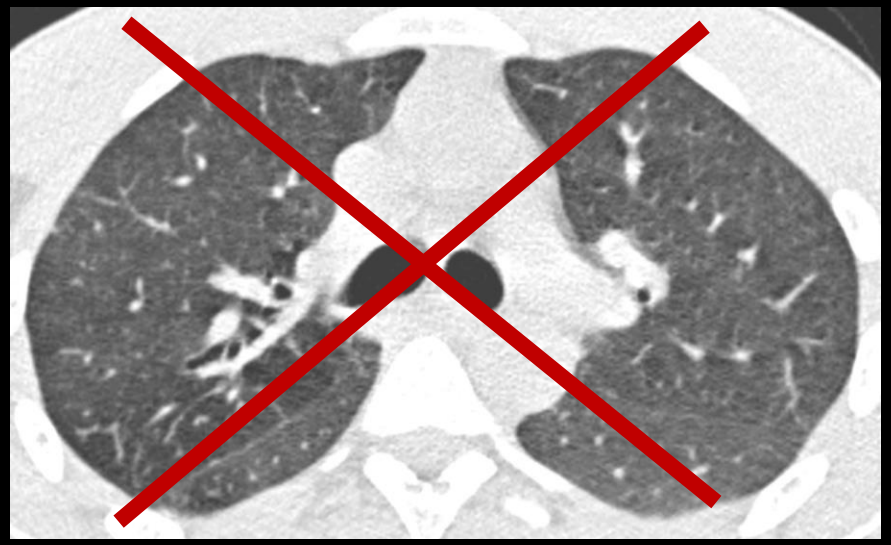

Pseudo-verre dépoli expiratoire

Densité normale en inspiration profonde

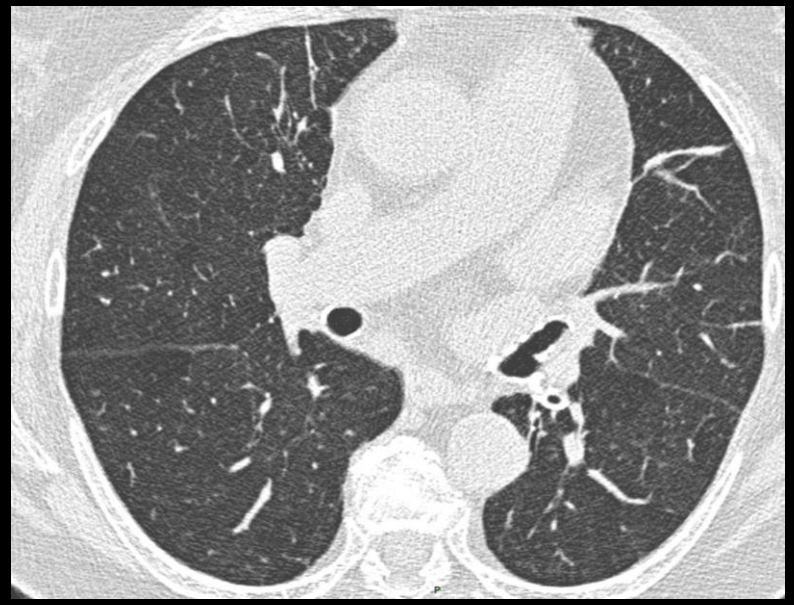

Opacités gravito-dépendantes

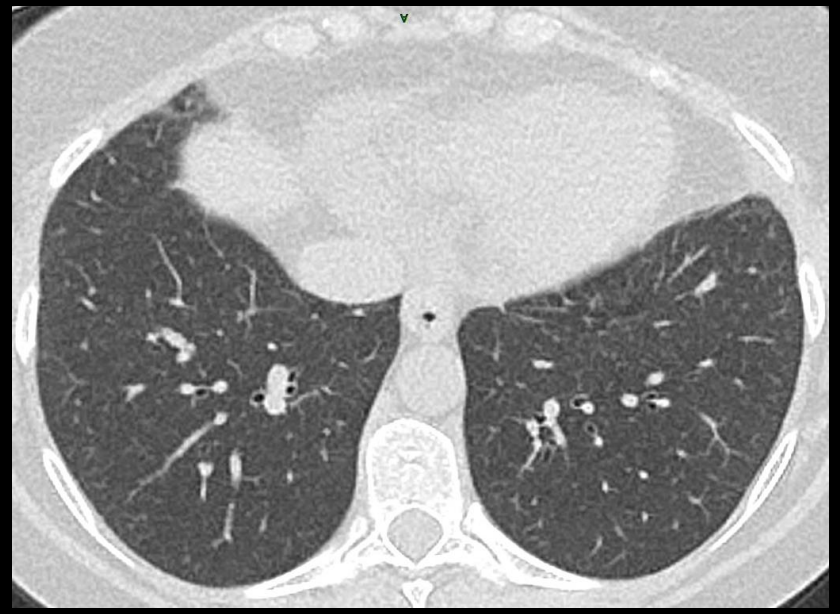

Disparition en procubitus

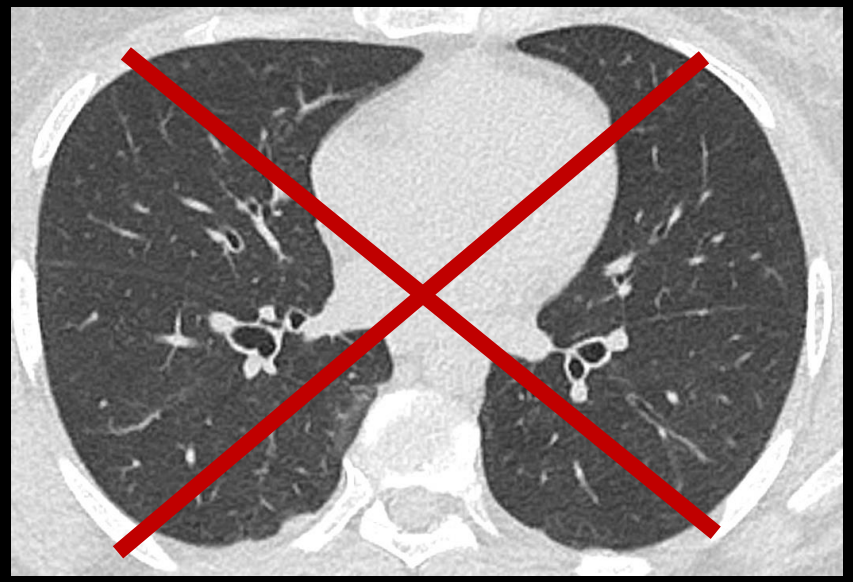

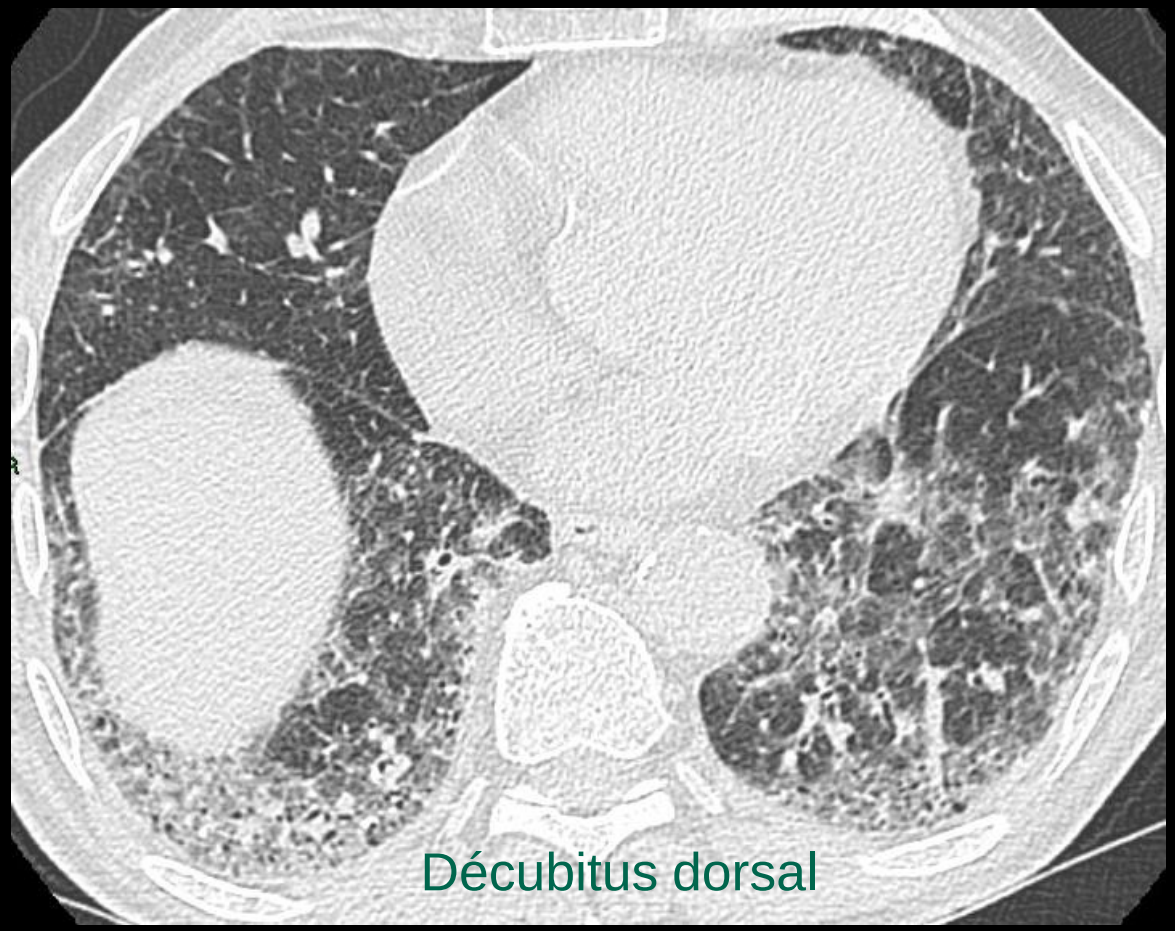

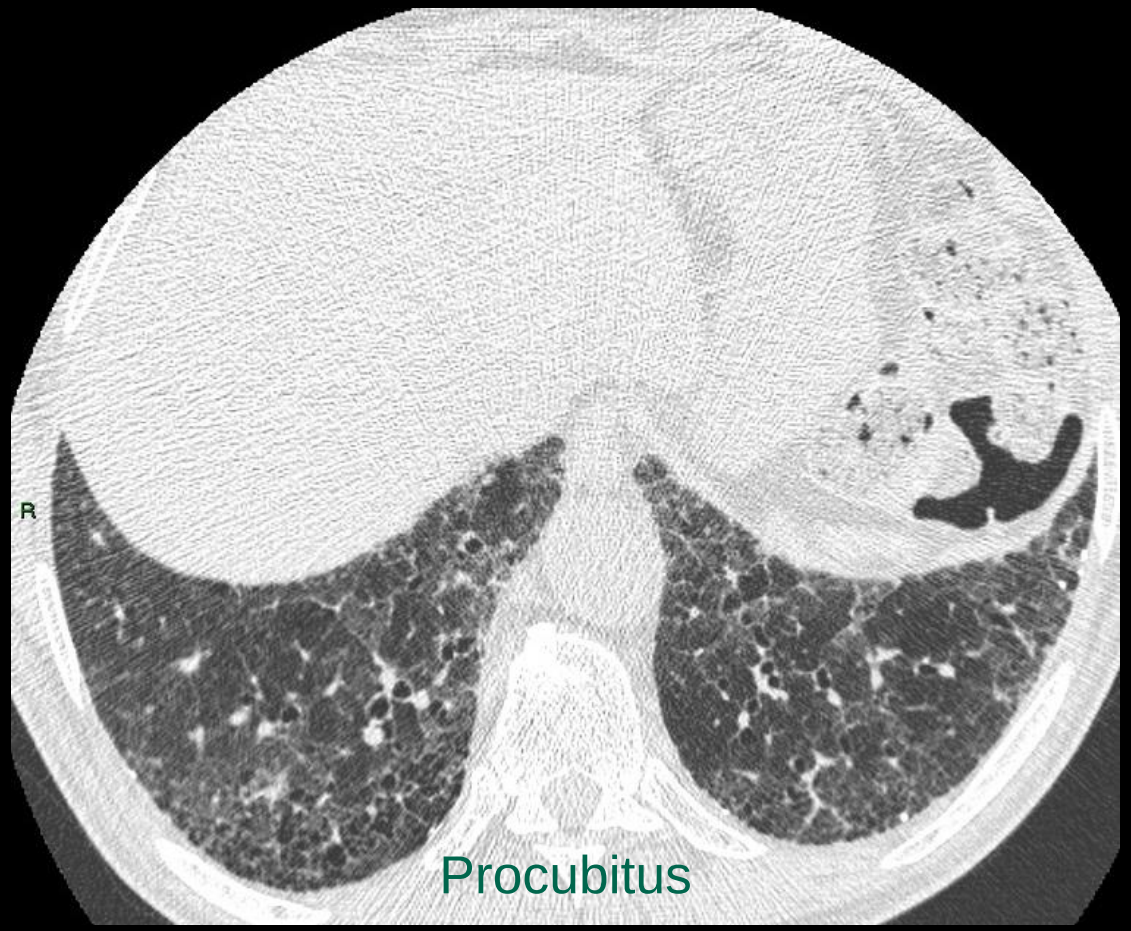

Déclivité + inspiration sous-maximale

- ⇨ Vérifier l'inspiration
- ⇨ Procubitus si anomalies en zones déclives

Opacités en plages

- Verre dépoli

N'efface pas les vaisseaux

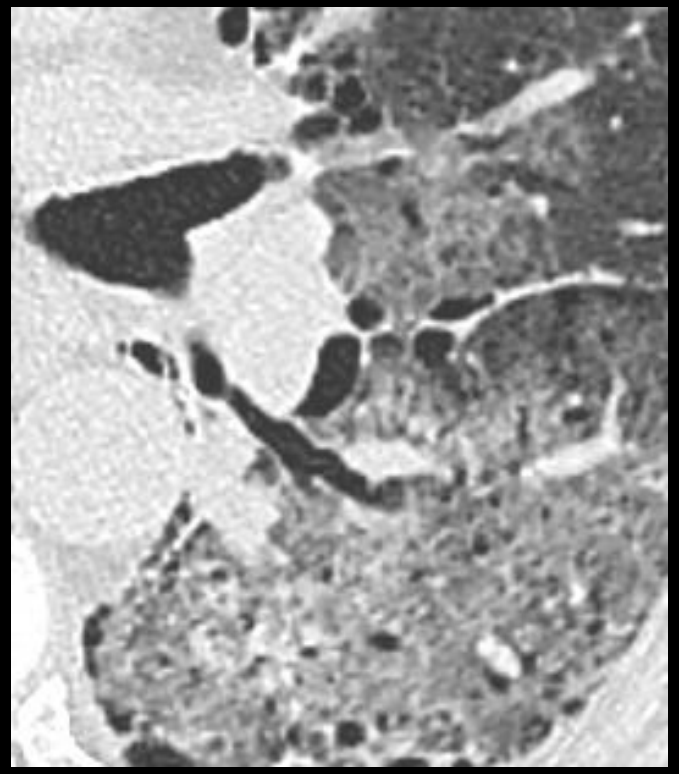

-400 à -200 HU

- Condensation

Efface les vaisseaux

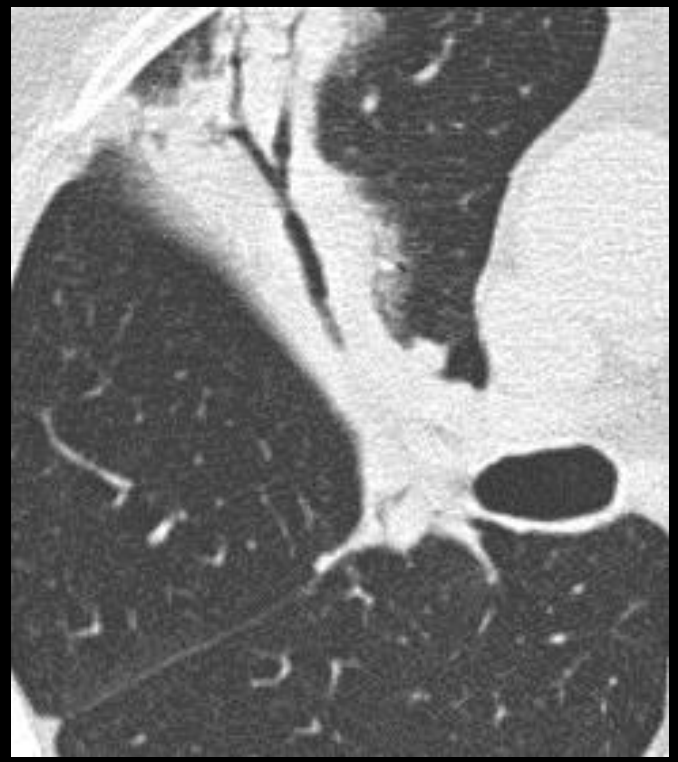

40 à 60 HU

Verre dépoli

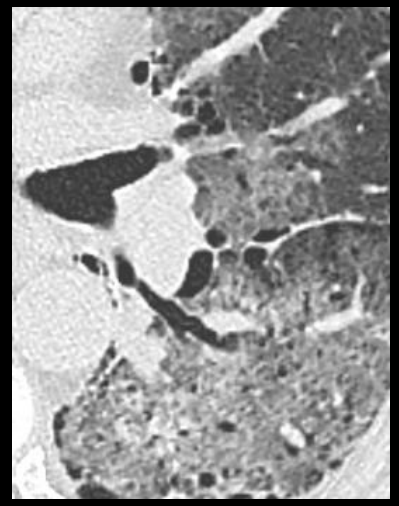

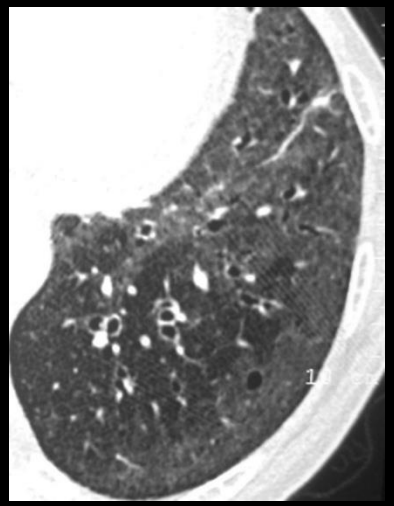

Effet de volume partiel

- Remplissage alvéolaire partiel
- Infiltration interstitielle
- Atteinte mixte, alvéolaire et interstitielle
- *Augmentation du volume sanguin capillaire*

Condensations

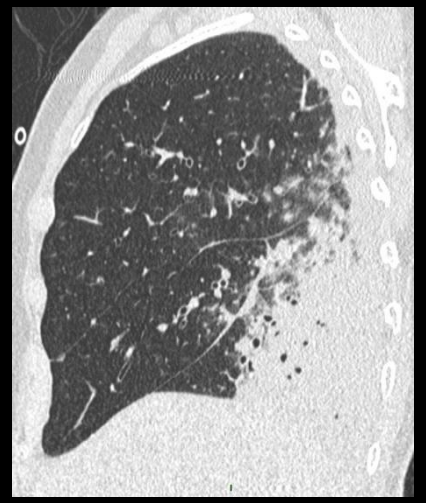

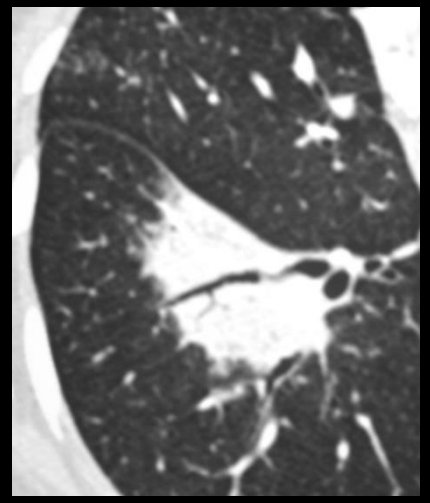

- Remplissage alvéolaire ++
- Infiltration interstitielle profuse

A l'échelle du lobule

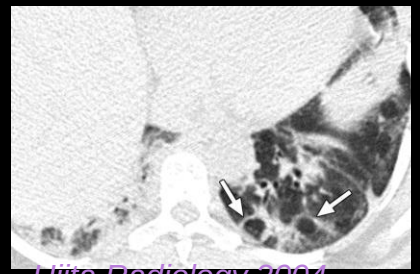

Ujita Radiology 2004

Verre dépoli de très faible intensité

S’aider du minIP

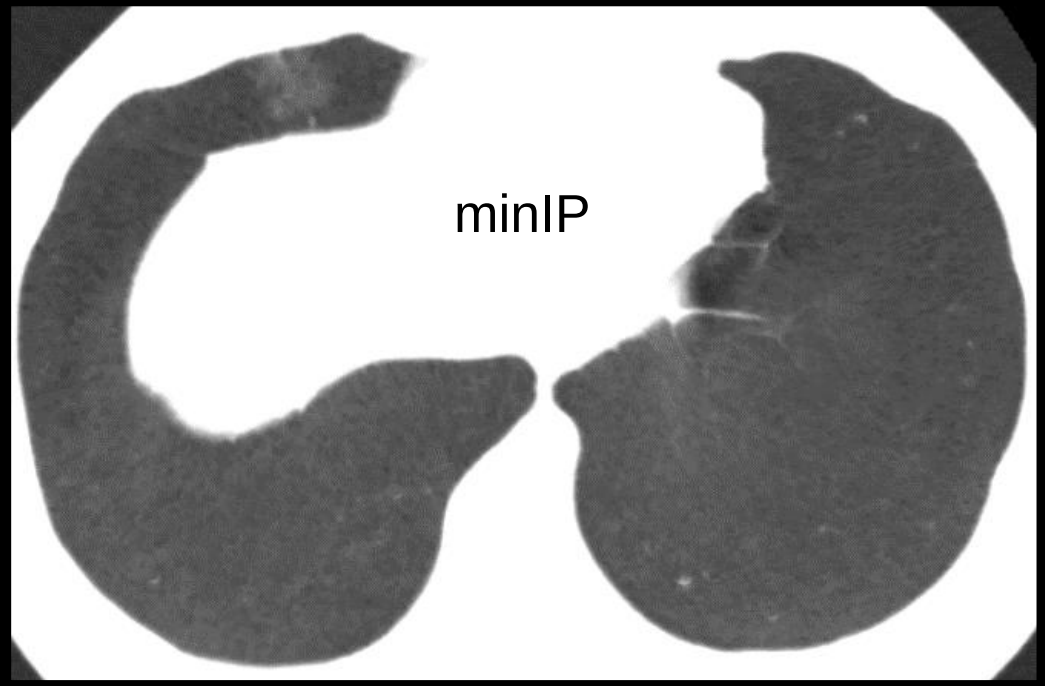

Opacités en verre dépoli

Contexte aigü

- Œdème pulmonaire
- Hémorragie pulmonaire
- Infection
  - P. jiroveci
  - Virus, M. pneumoniae
- …

Contexte chronique

- PINS
- Pneumopathie d'hypersensibilité
- DIP, RB-ILD
- Pneumopathie médicamenteuse
- LIP
- Pneumonie lipidique
- Adenocarcinome
- Protéinose alvéolaire
- Nieman-Pick
- …

« Crazy paving »

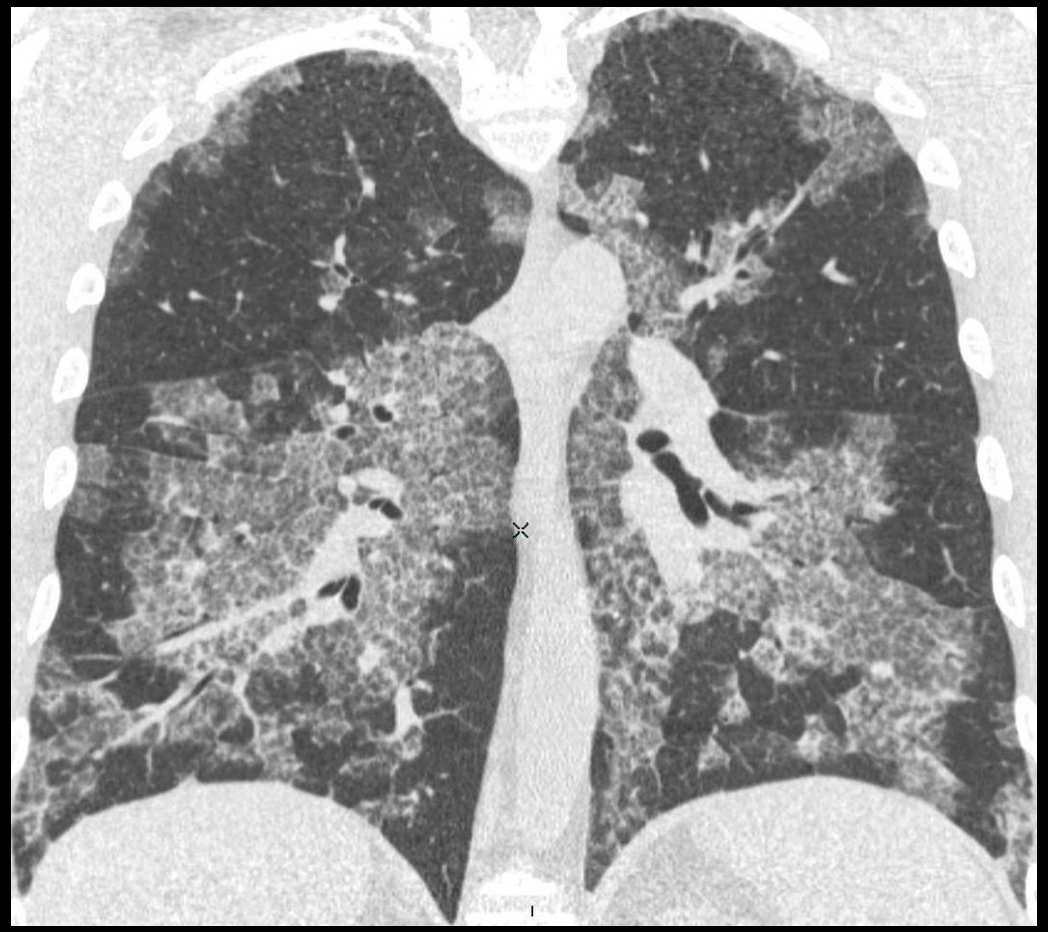

- Superposition réticulations et verre dépoli
- Aspect en carte de géographie
- Pas de signe de fibrose

« Halo inversé»

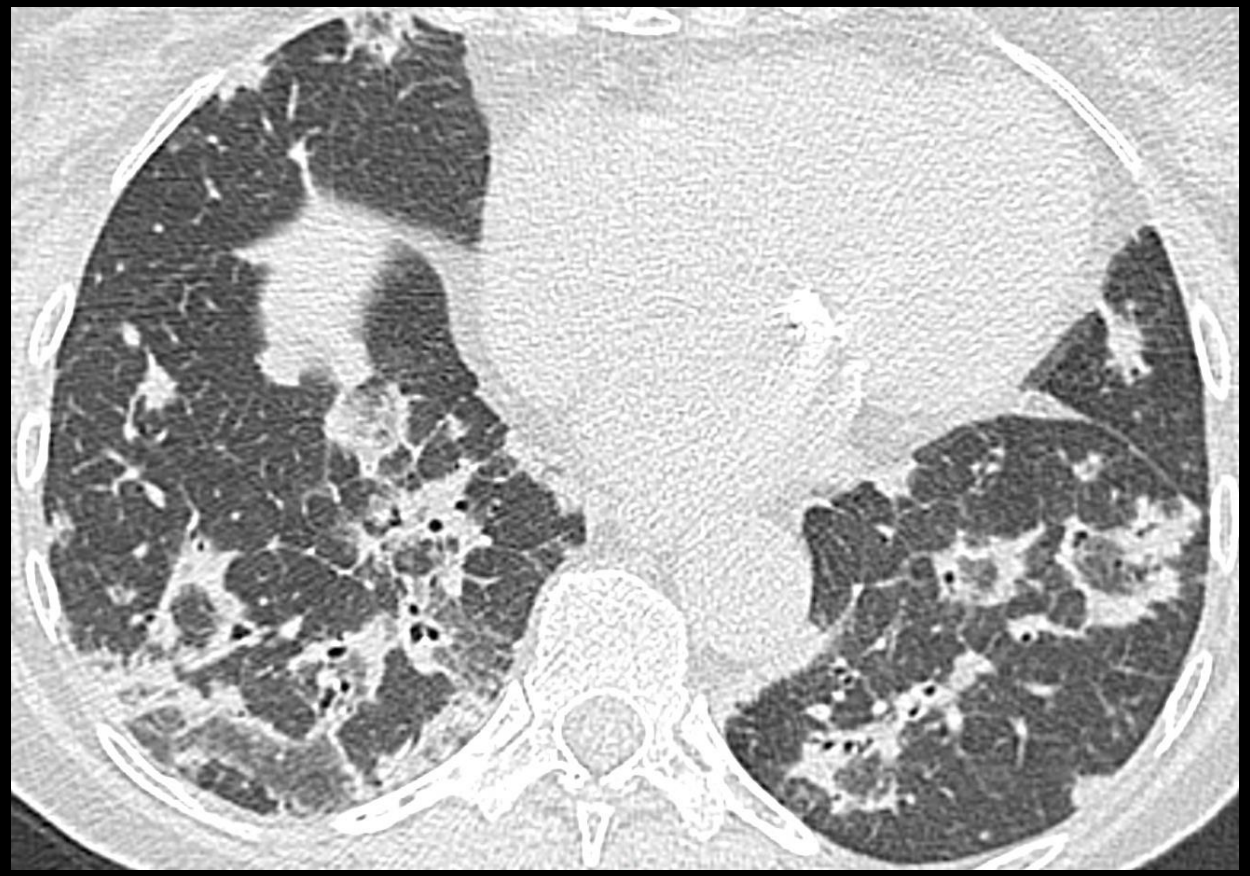

- Plage de verre dépoli
- Couronne de condensation

Verre dépoli en contexte chronique

Rechercher des signes de fibrose

DIP

PINS fibrosante

Verre dépoli en contexte chronique

Rechercher des kystes, lobules clairs, un crazy paving

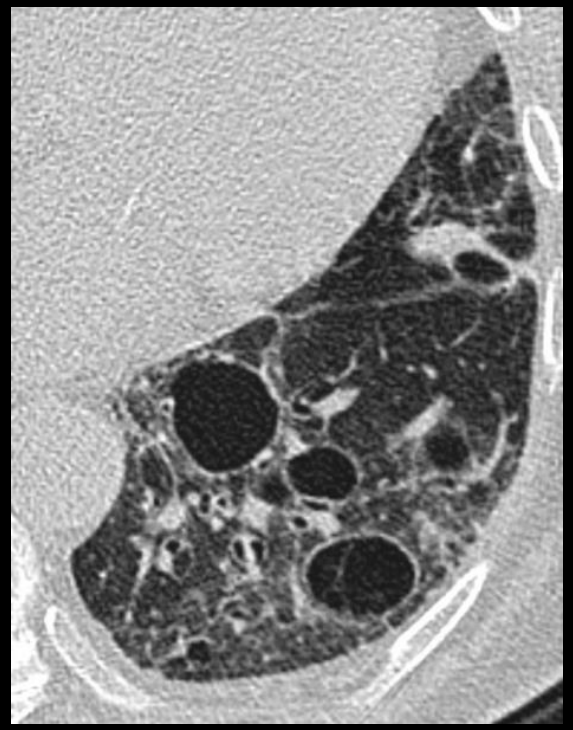

LIP

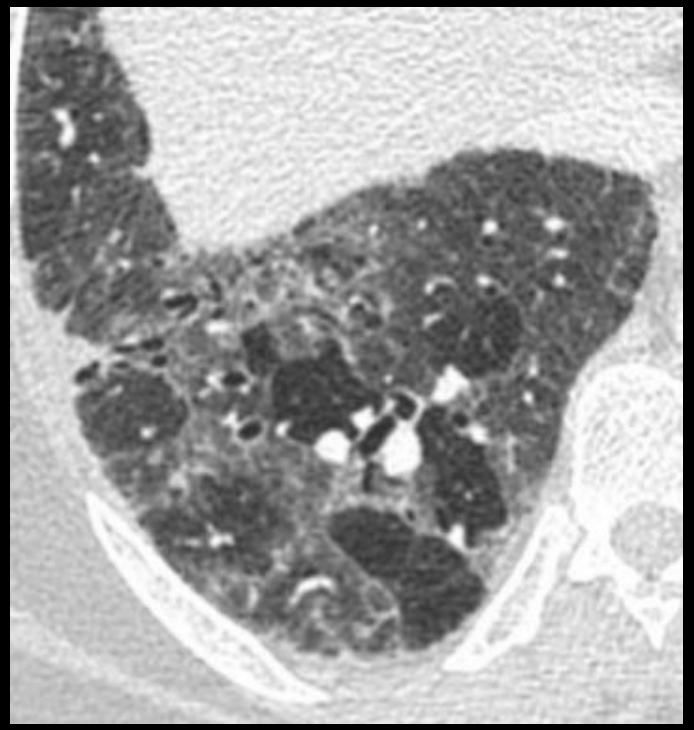

Pneumopathie d’hypersensibilité

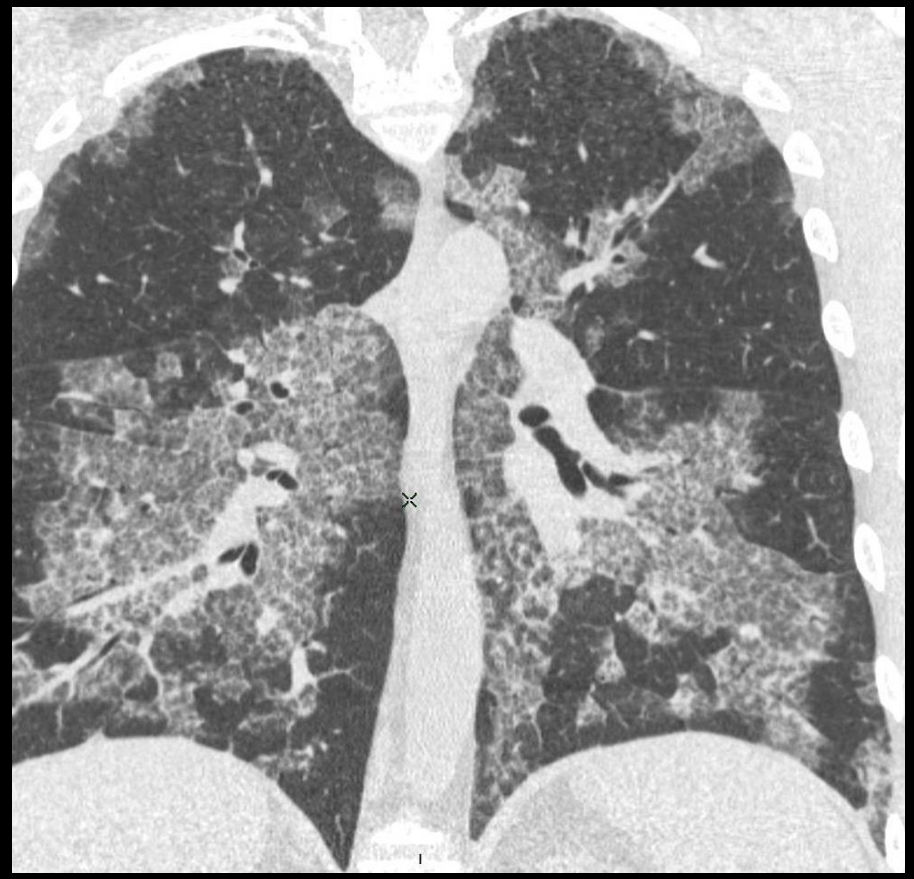

Protéinose alvéolaire

Aspect en mosaïque des densités

- Verre dépoli patchy

Zones les plus denses sont pathologiques

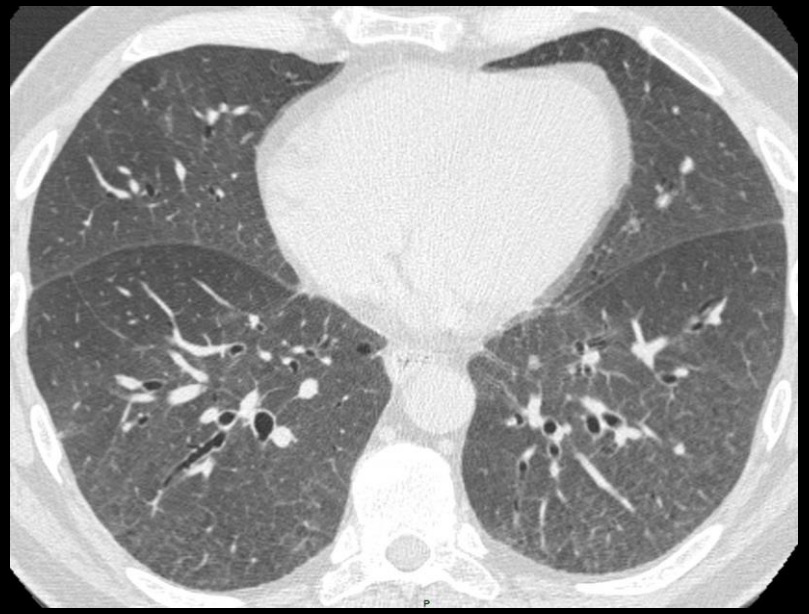

- Perfusion en mosaïque

Zones les moins denses sont pathologiques

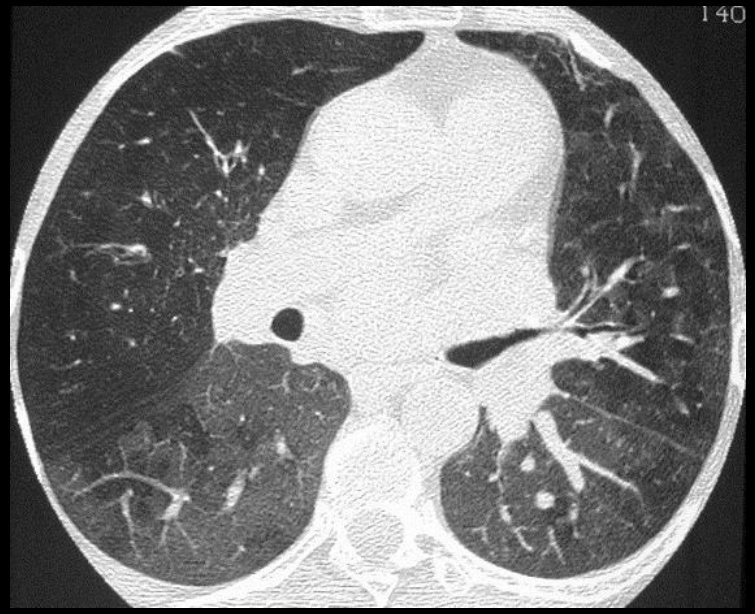

Perfusion en mosaïque

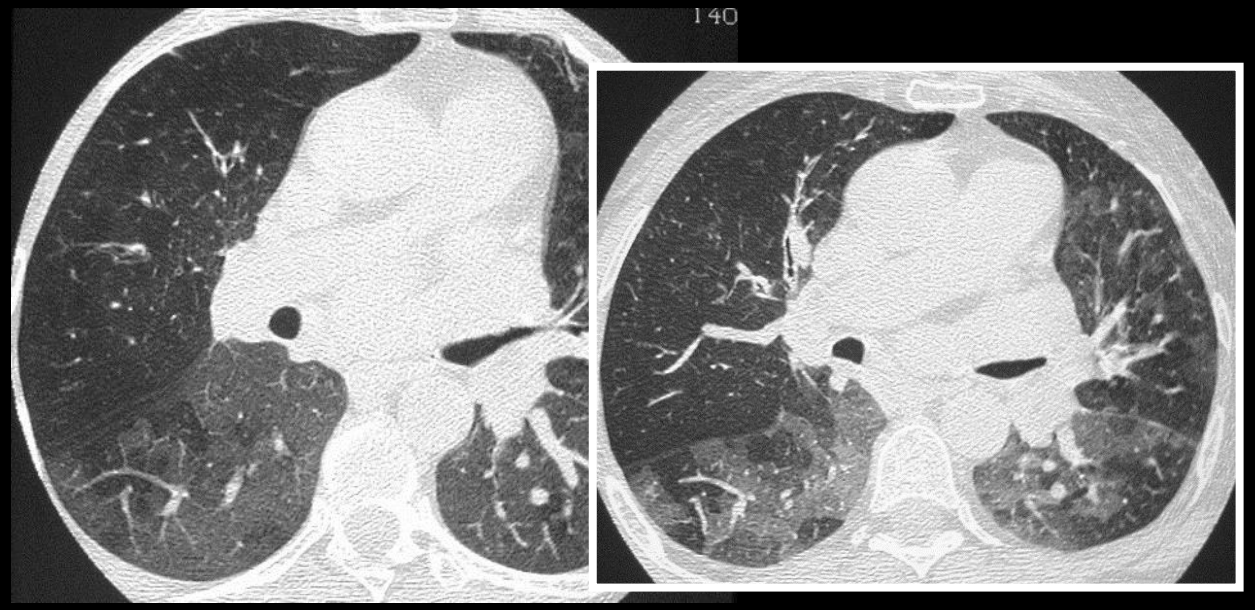

Comment la reconnaître ?

↓ calibre vaisseaux des zones moins denses

Comment identifier la cause ?

Rechercher un piégeage aérique

⇒ Coupes en <u>expiration</u>

- Zones les moins denses hypoperfusées
  - Séquelle embolique
  - Vasoconstriction réactionnelle à atteinte bronchiolaire
- Zones les plus denses bien perfusées

Comparer le calibre des vaisseaux



Perfusion en mosaïque



Aspect en mosaïque

Expiration

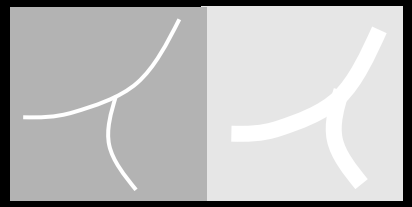

Maladie vasculaire

Maladie voies aériennes

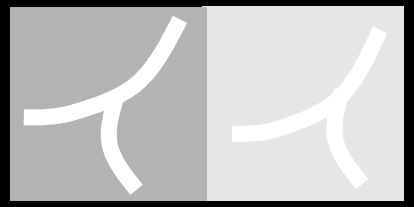

Maladie infiltrative

Aspect « 3 densités »

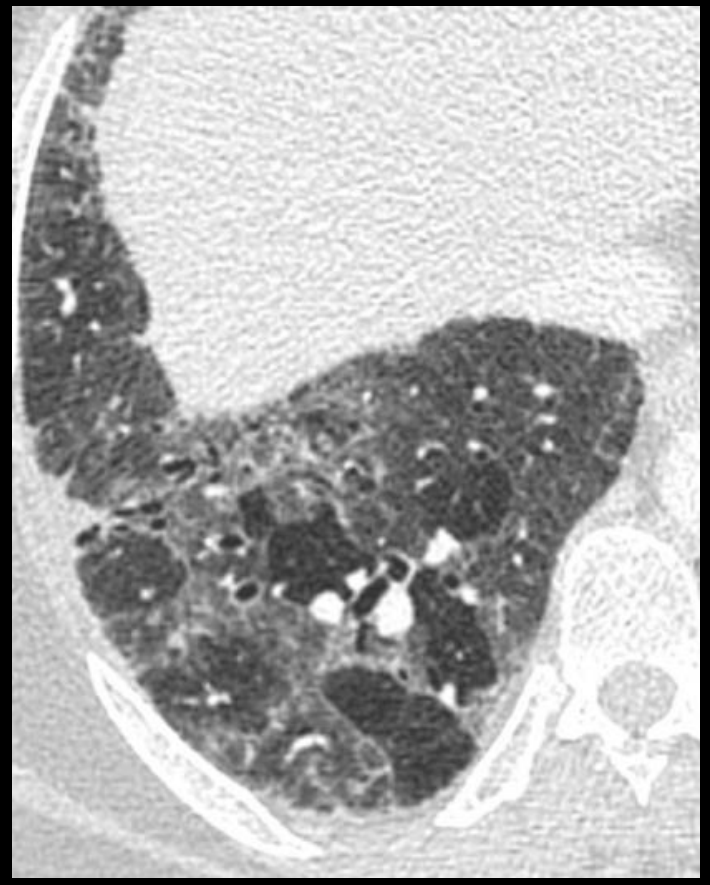

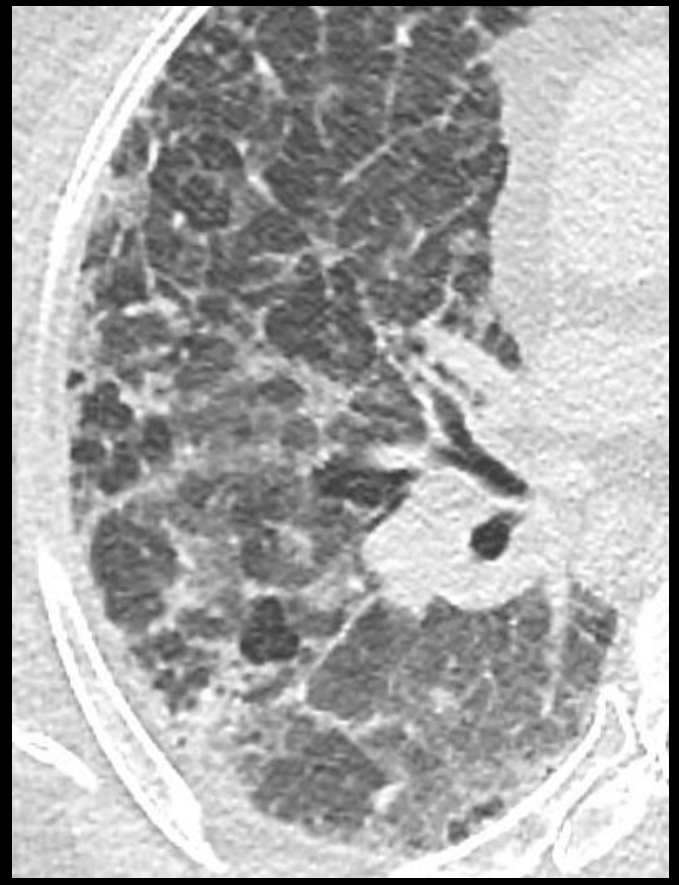

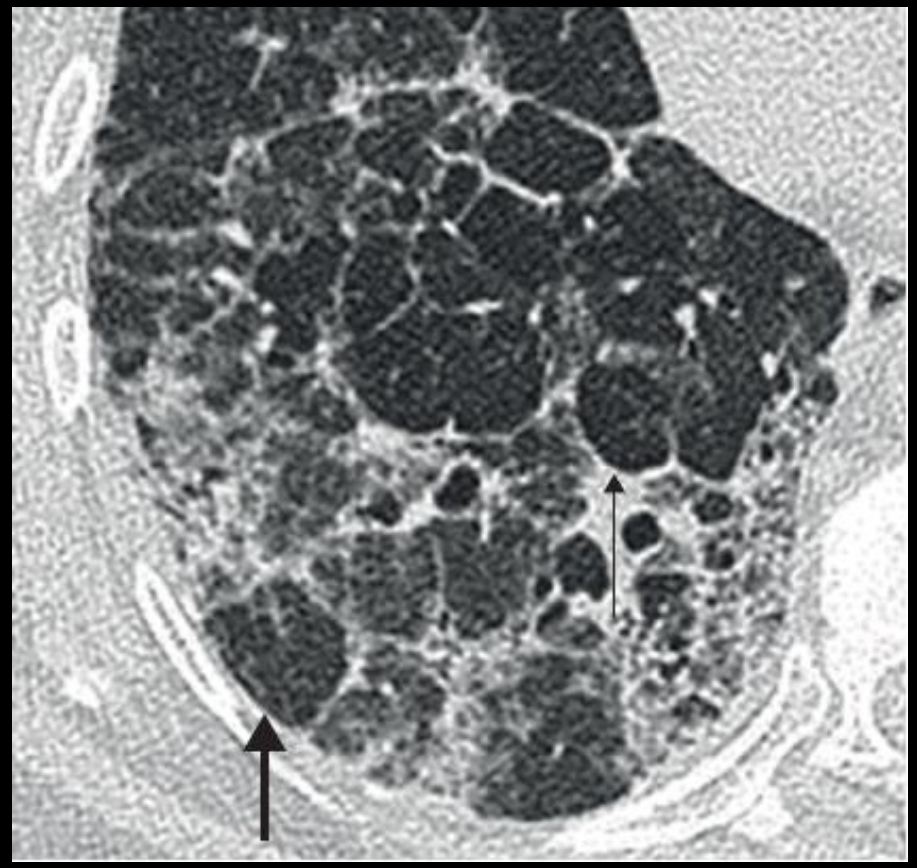

Verre dépoli
Lobules hyperclairs
Lobules de densité normale

→

- Pneumopathie d'hypersensibilité
- Sarcoidose
- PID liées au tabac

Nodules

- Focal, rond ou ovale

  Micro - < 3 mm
  Masses > 30 mm

- « Solide » ou de faible densité

« Solide »

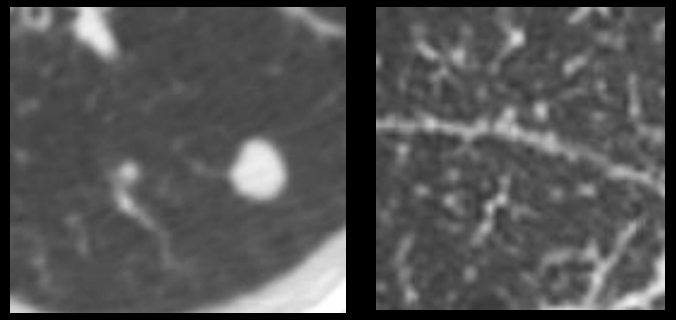

Faible densité

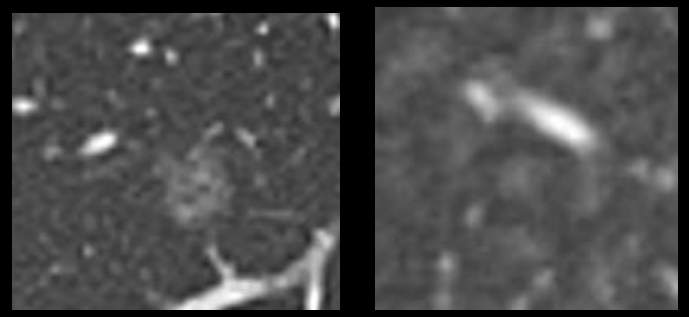

Lésions micronodulaires

Distribution centrolobulaire

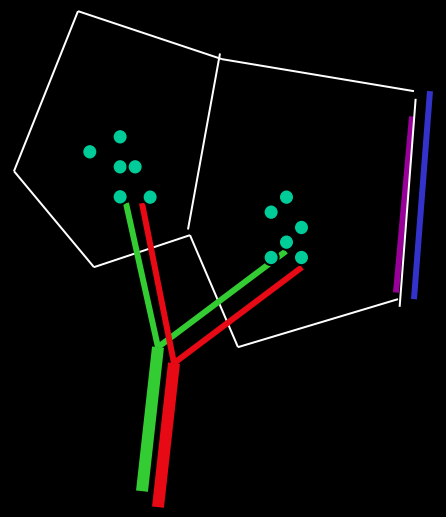

Distribution périlymphatique

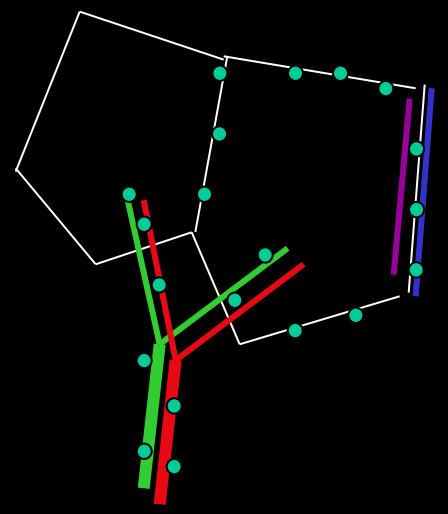

Distribution au hasard

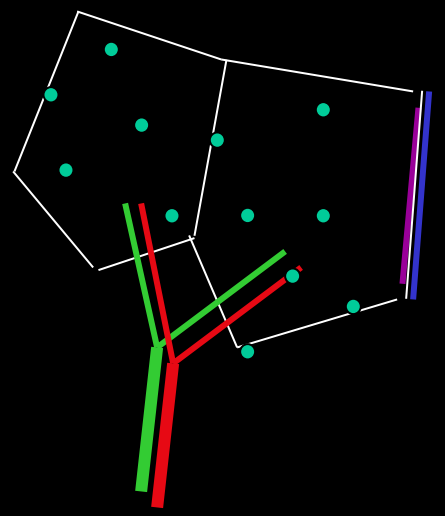

Avec arbre en bourgeons

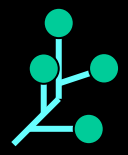

Distribution centrolobulaire

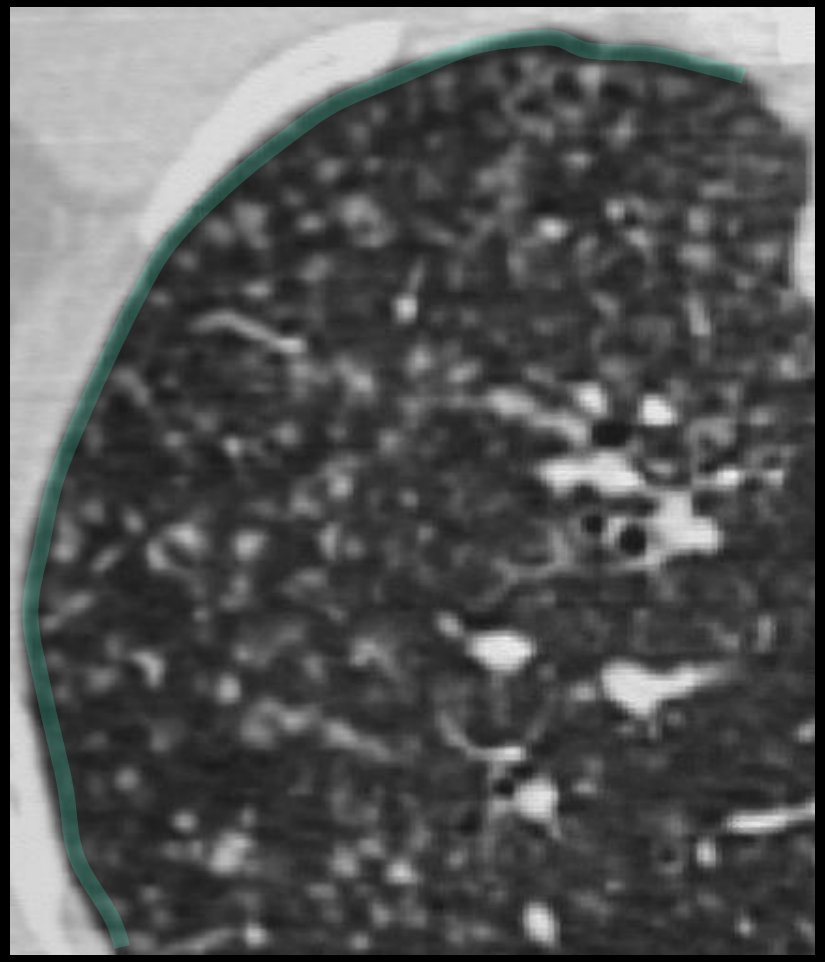

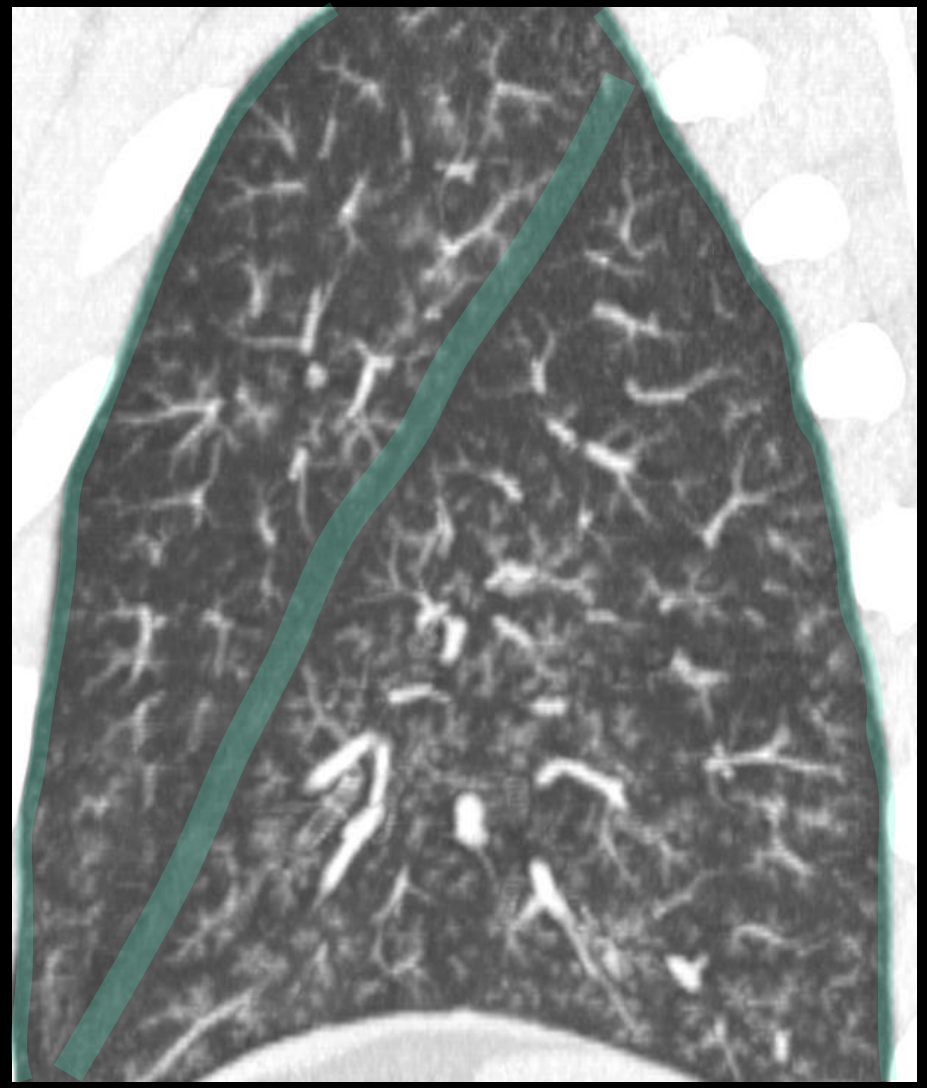

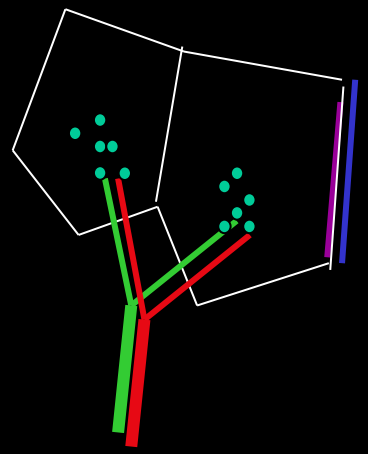

Distribution centrolobulaire

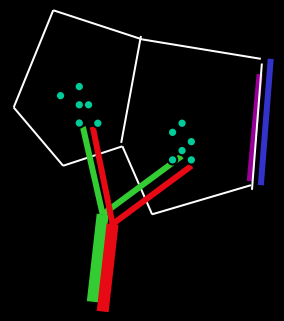

Maladie péribronchiolaire

- Bronchiolite infectieuse
- Bronchiolite respiratoire
- Pneumopathie d’hypersensibilité
- Bronchiolite folliculaire
- …

Maladie périvasculaire

- Œdème pulmonaire débutant
- Hémorragie alvéolaire
- Hypertension artérielle pulmonaire
- …

Distribution centrolobulaire

Infection ++

- Arbre en bourgeons fréquent
- ± Verre dépoli, condensations, épaississement parois bronchiques
- Souvent patchy

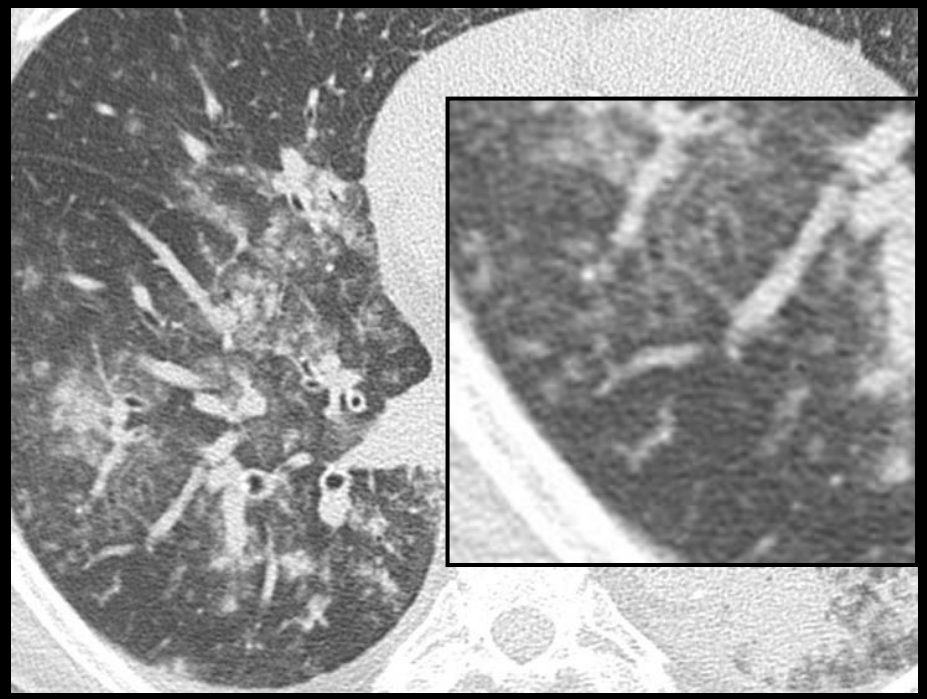

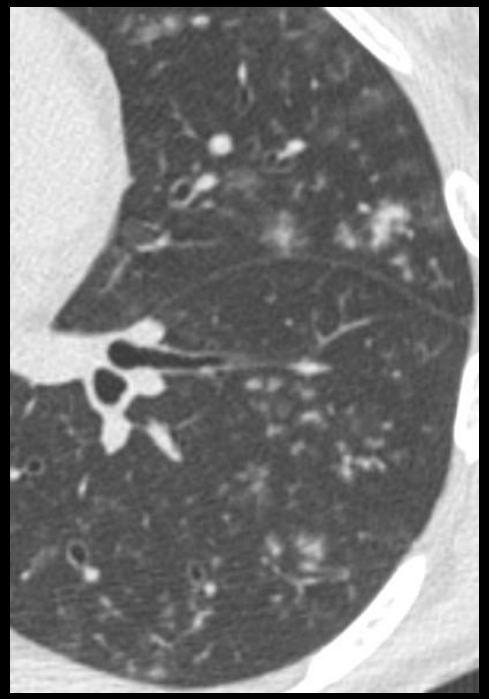

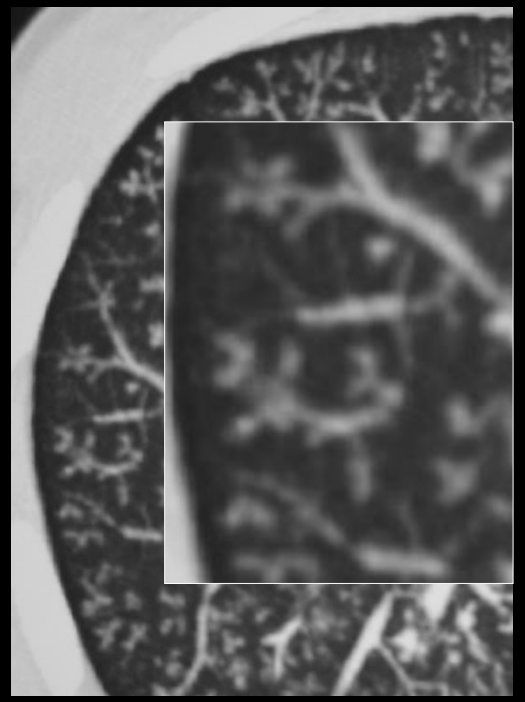

Causes non infectieuses d’arbre en bourgeons

- Certaines bronchiolites inflammatoires
- Métastases endobronchiques/endovasculaires

Bronchiolite folliculaire (Sjögren)

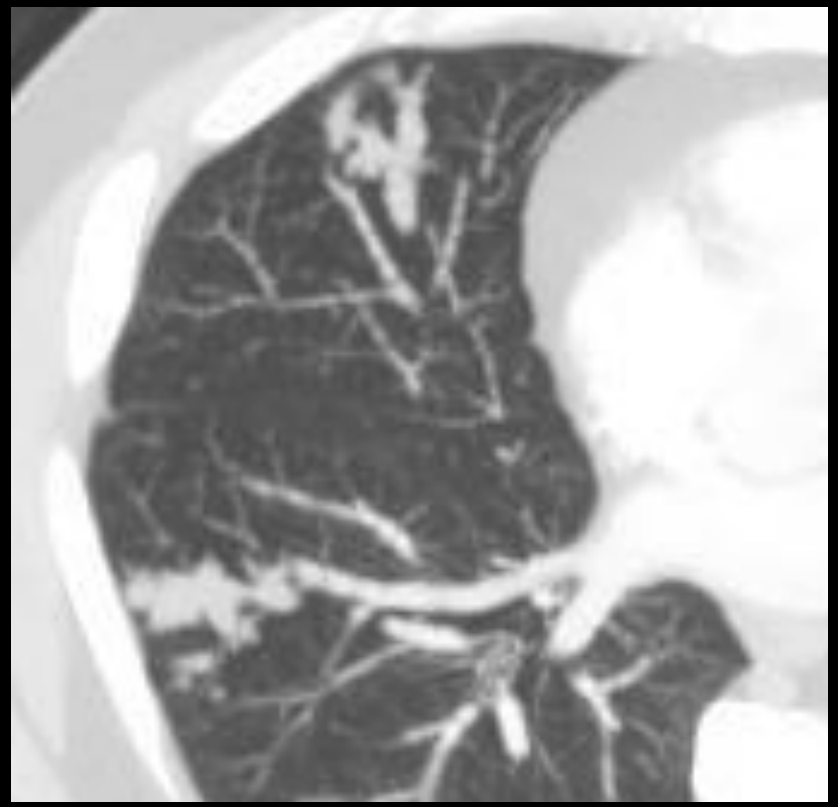

Métastases endovasculaires

Distribution centrolobulaire sans arbre en bourgeons

Bronchiolite respiratoire et pneumopathie d’hypersensibilité

- Faible densité
- Diffus ou à prédominance supérieure

Bronchiolite respiratoire

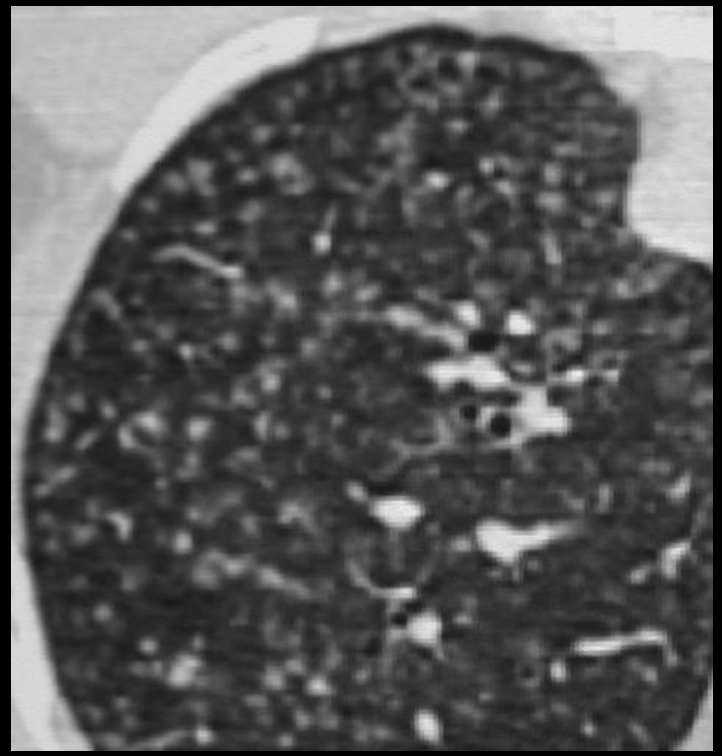

Pneumopathie d’hypersensibilité

Distribution périlymphatique

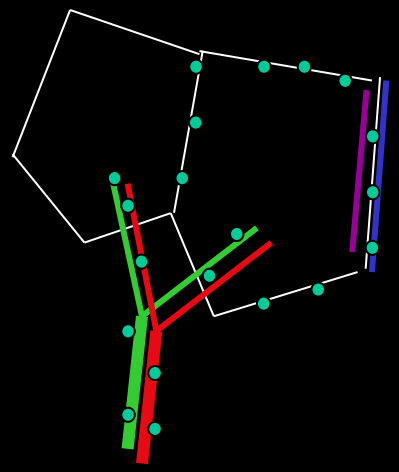

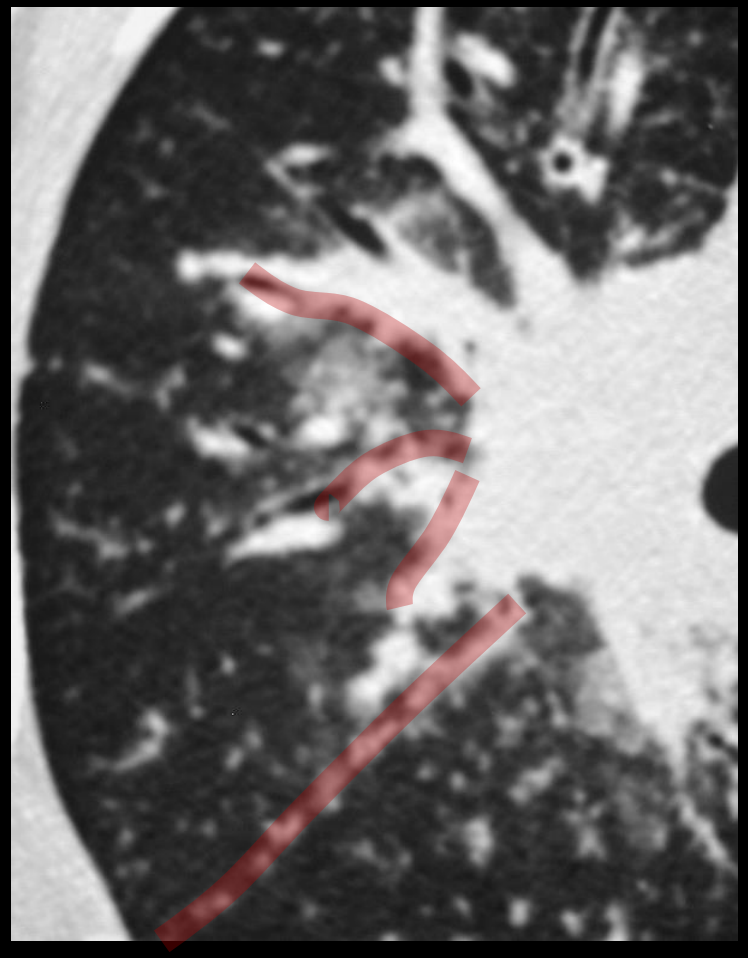

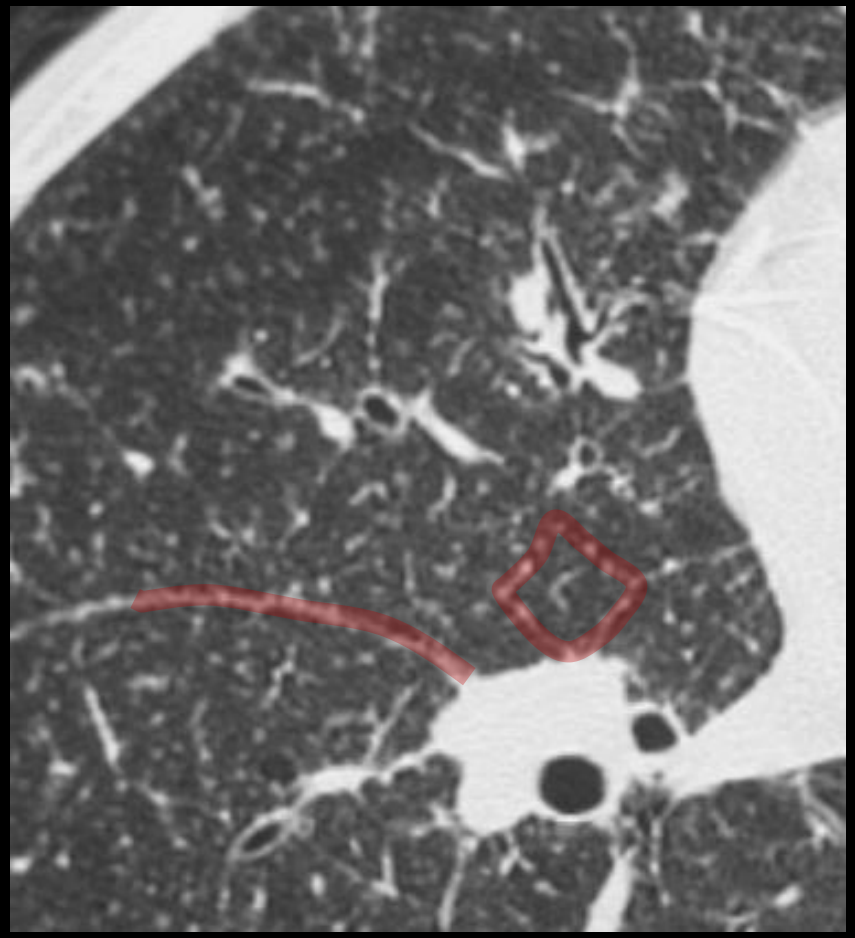

Distribution périlymphatique

- Sarcoidose
- Pneumoconioses
  - Silicose
  - Bérylliose
- Lymphangite carcinomateuse
- Amylose
- …

Distribution périlymphatique

Sarcoidose

- Le plus souvent le long des axes bronchovasculaires centraux et des scissures
- Parfois aspect perlé des septas interlobulaires
- Prédominance supérieure, patchy

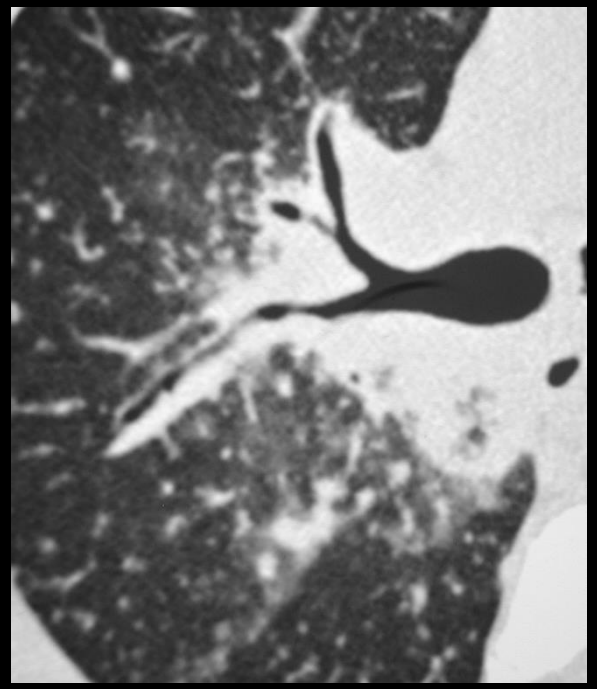

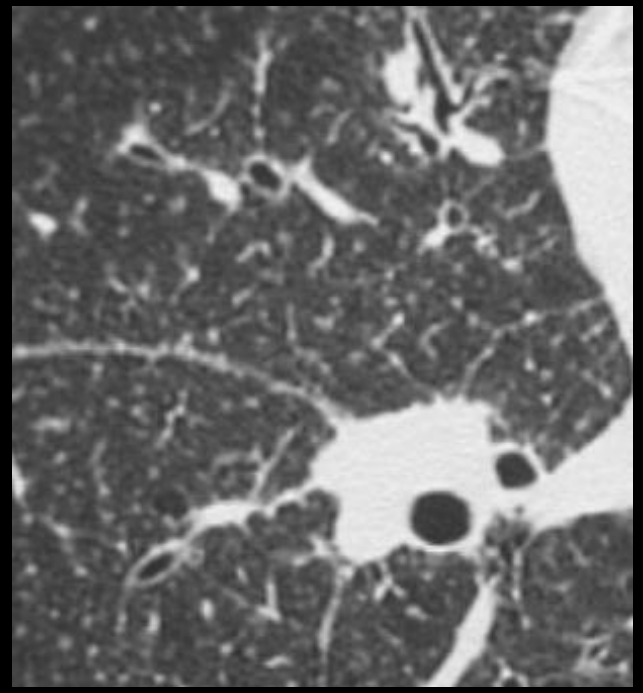

Distribution au hasard

- Miliaire tuberculeuse
- Miliaire carcinomateuse
- Miliaire fungique

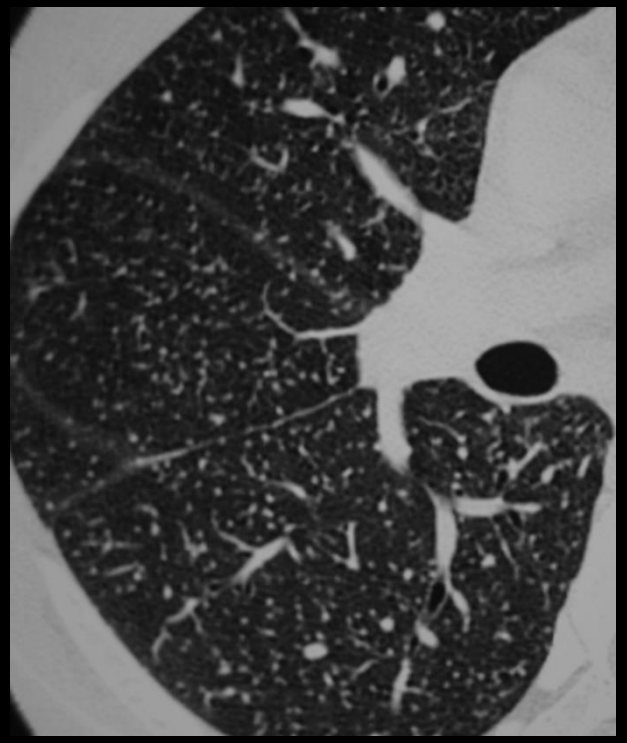

Miliaire tuberculeuse

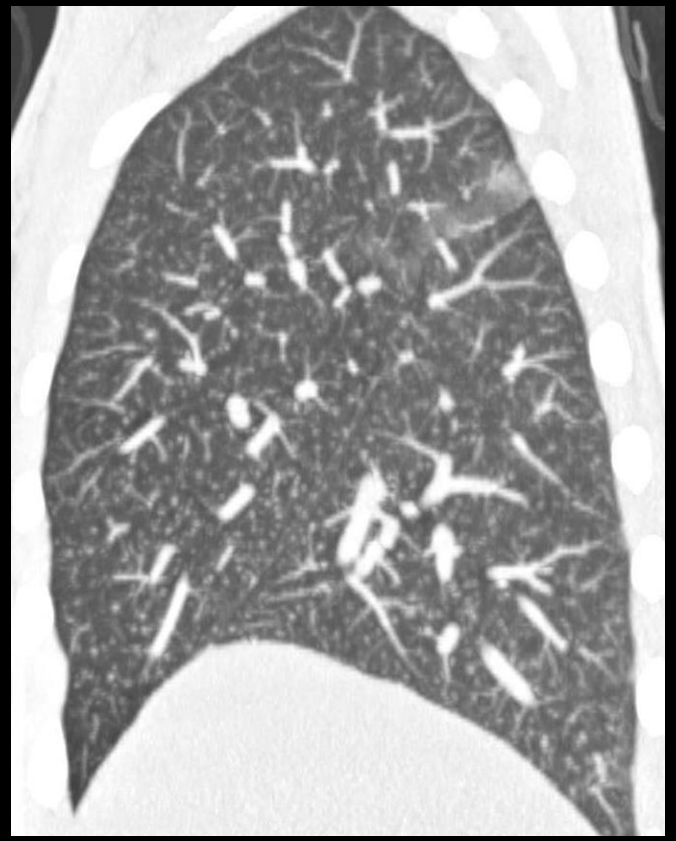

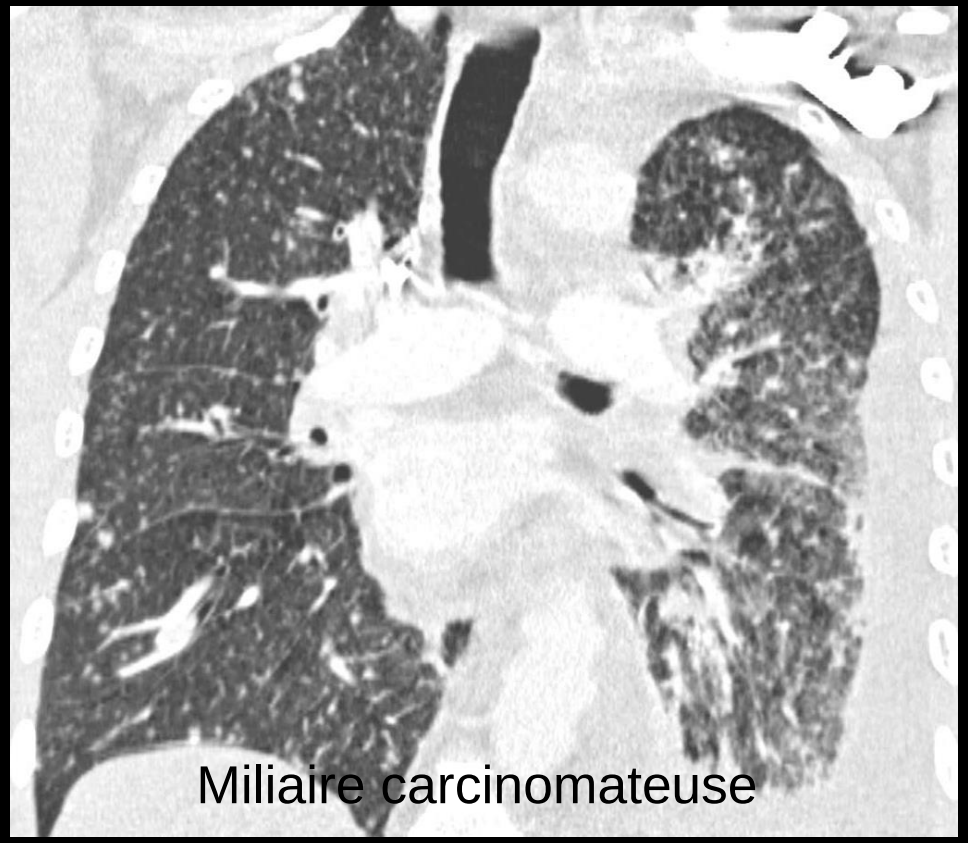

Miliaire carcinomateuse

Distribution mixte

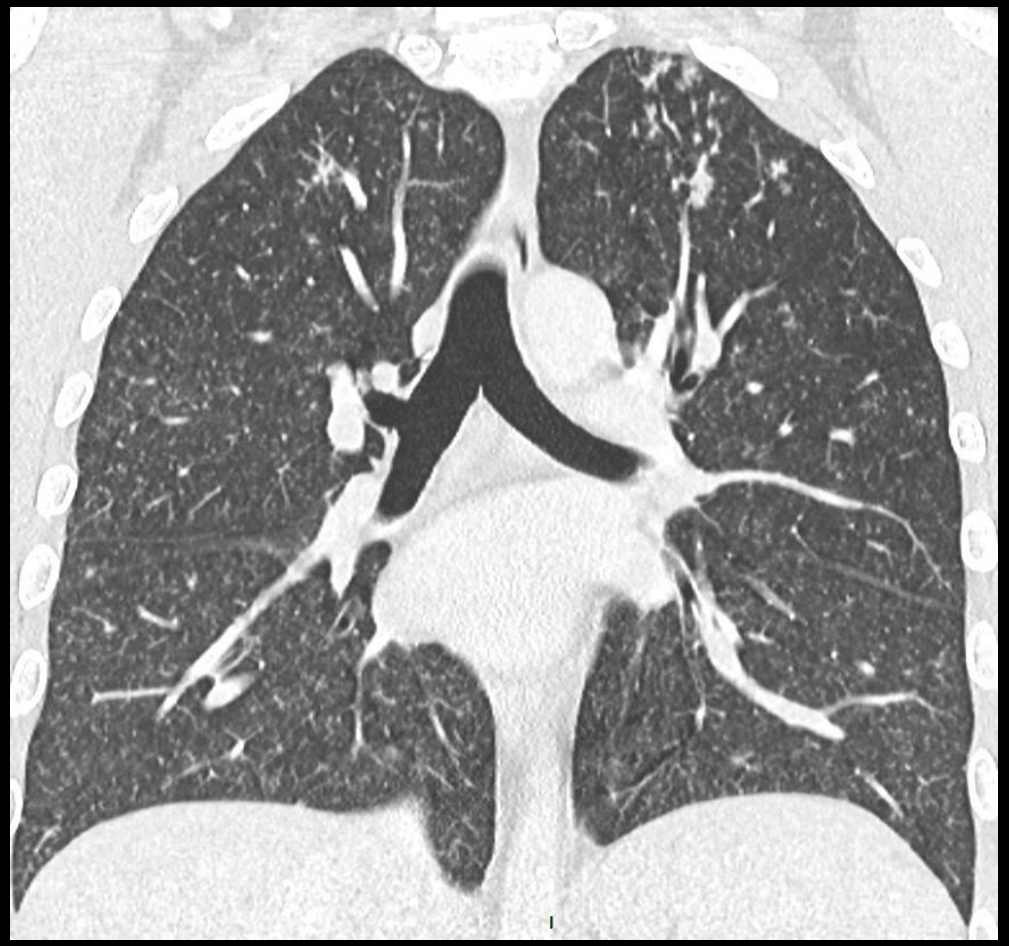

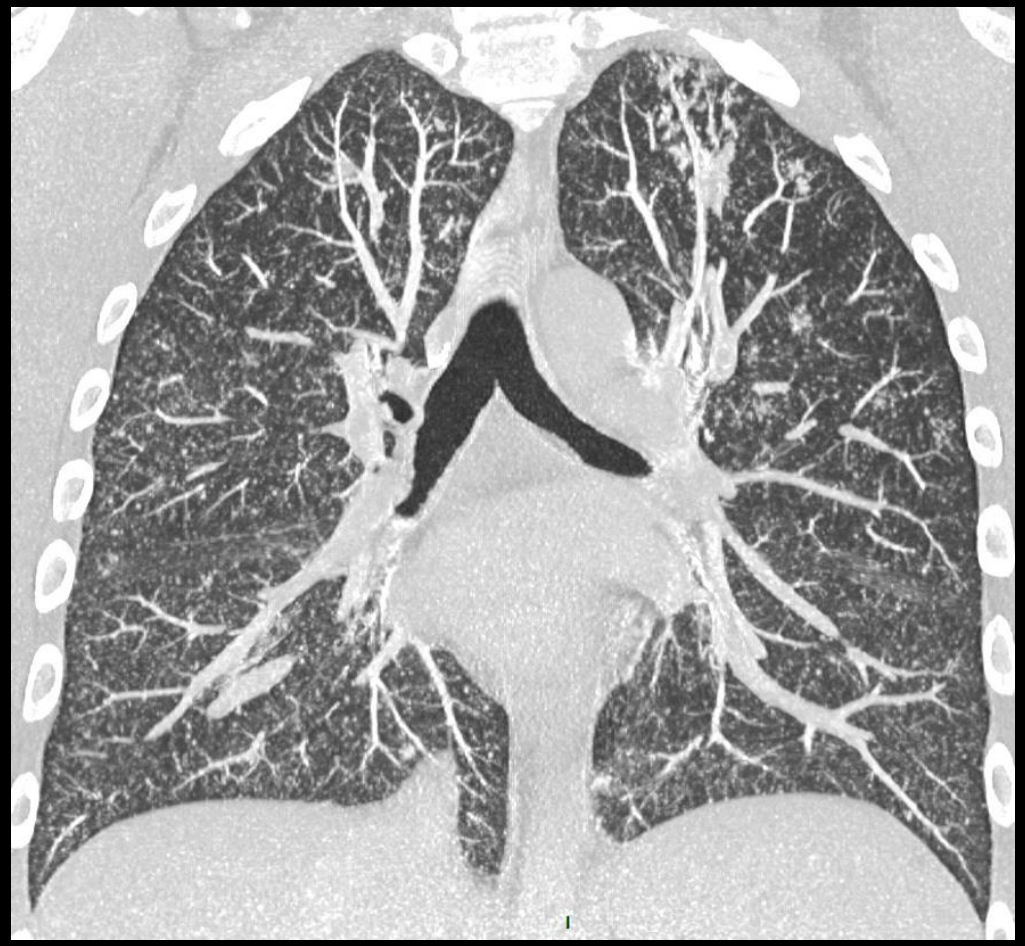

Au hasard et centrolobulaire, avec arbre en bourgeons

Opacités linéaires et réticulaires

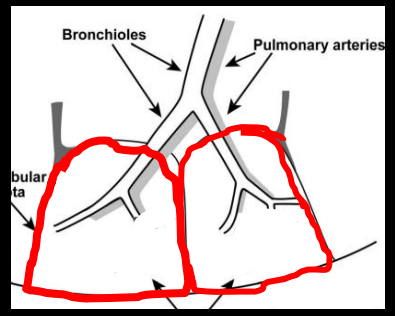

Septas

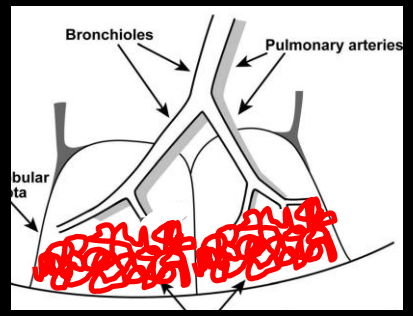

Intralobulaires



Rayon de miel



Bandes

Lisse



Nodulaire

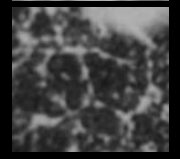

Irrégulier

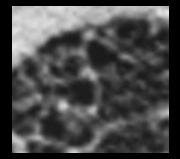

Avec fibrose

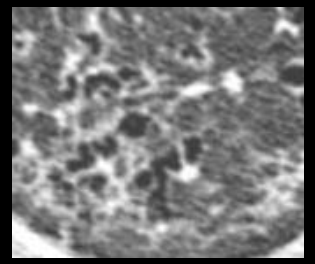

Sans fibrose

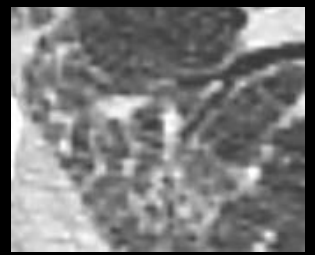

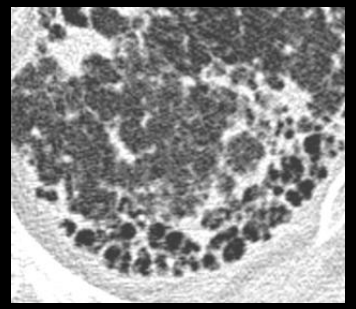

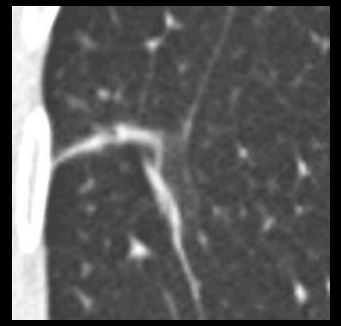

Epaississement septal

Régulier

- Œdème pulmonaire
  - Cardiogénique
  - Obstruction veineuse pulmonaire
- Hémorragie pulmonaire
- Lymphangite carcinomateuse
- Amylose
- ….

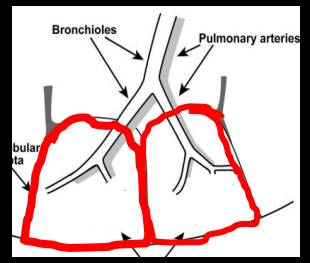

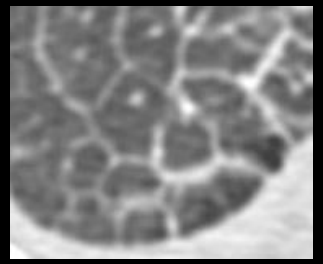

Nodulaire: maladies de distribution lymphatique

- Sarcoidose
- Lymphangite carcinomateuse
- …

Irrégulier: fibrose

- Sarcoidose
- Pneumopathie d'hypersensibilité fibreuse
- …

Atteinte septale prédominante

Œdème pulmonaire cardiogénique

Lymphangite carcinomateuse

Réticulations intralobulaires

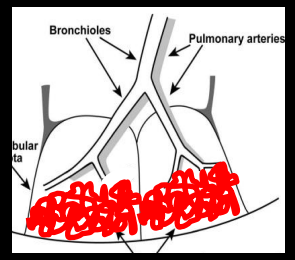

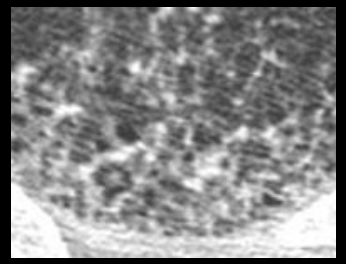

Avec signes de fibrose

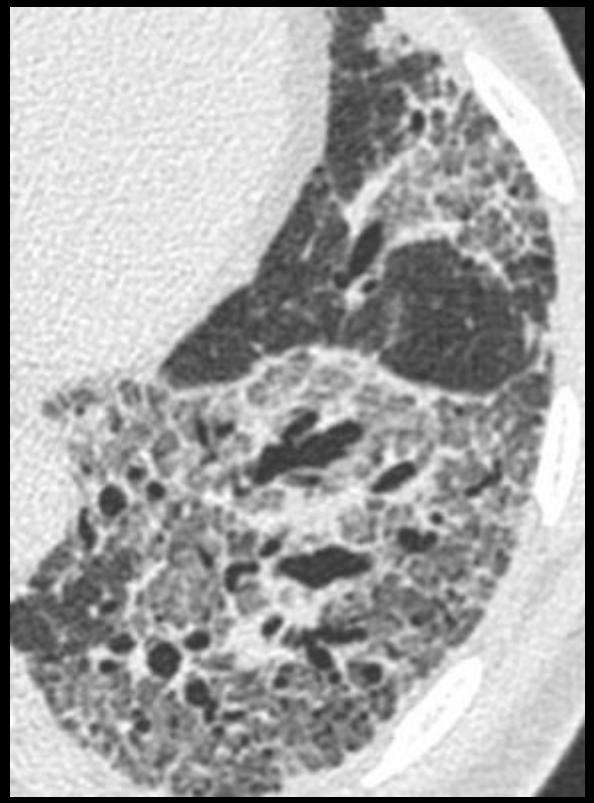

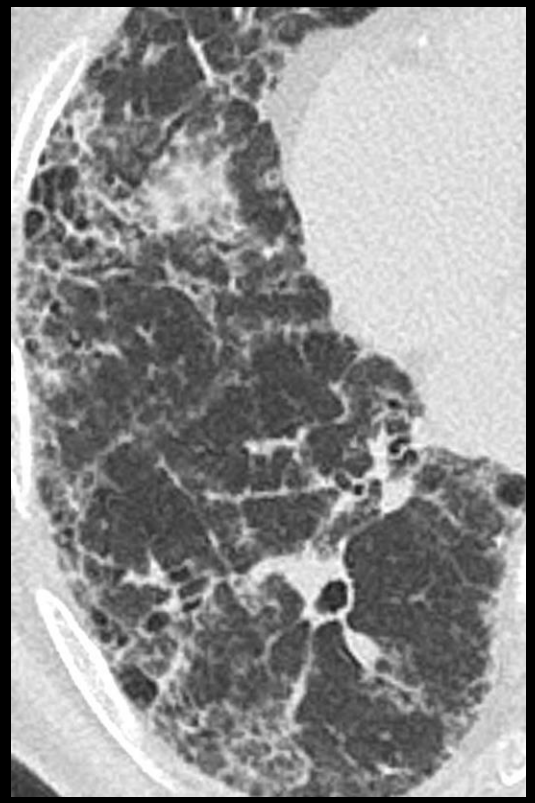

Sans signe de fibrose

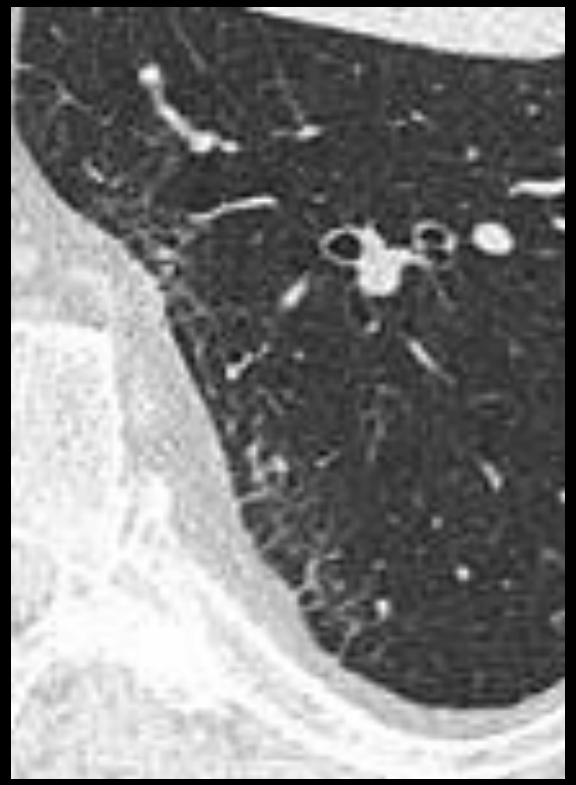

Rayon de miel

Signe formel de fibrose « end-stage »

Elément pronostique des PID fibrosantes

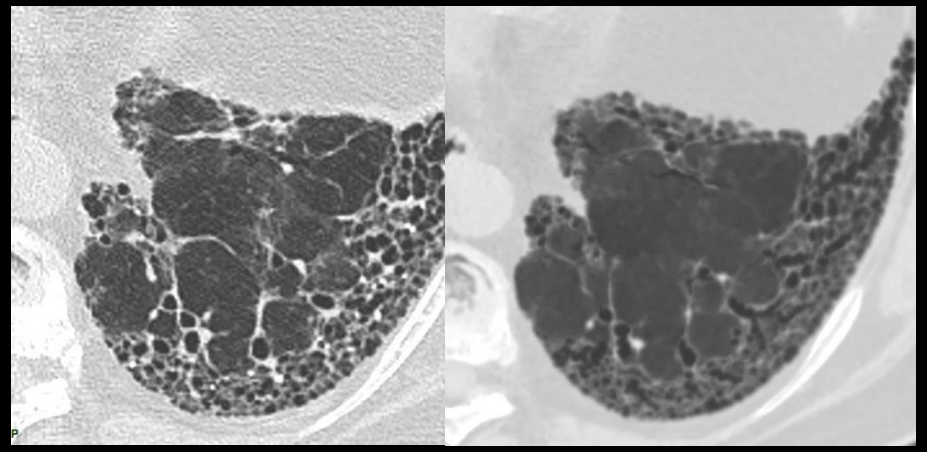

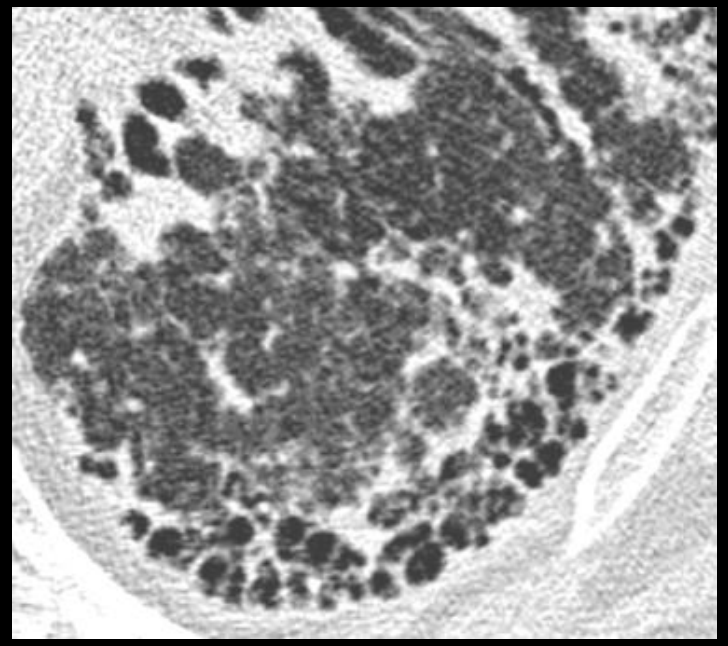

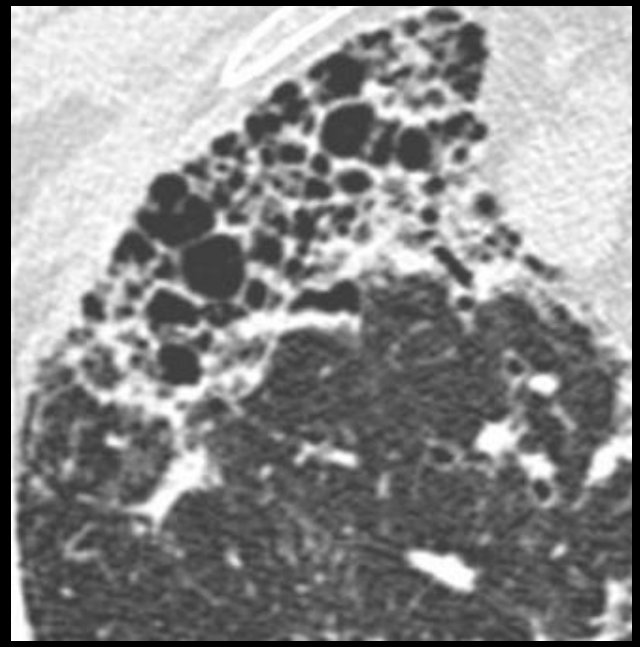

Tailles variables

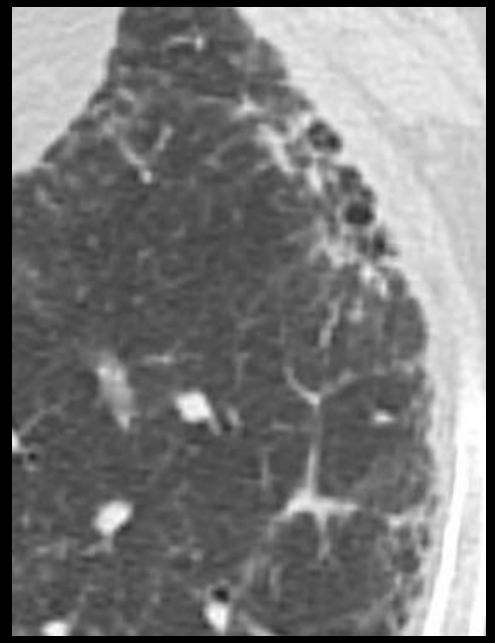

Mono-couche

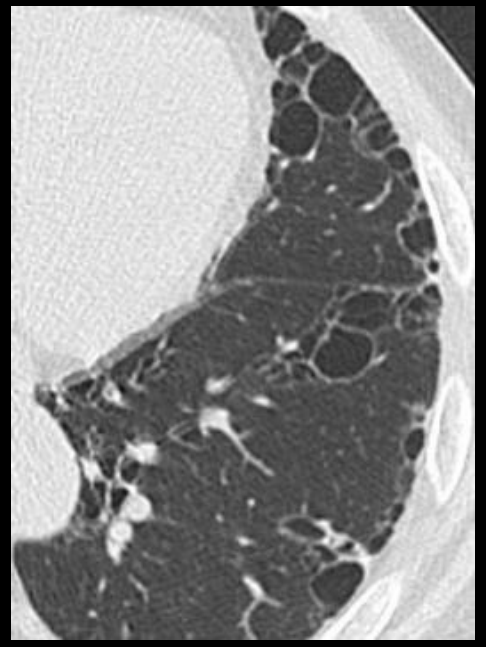

Macrokystique pur

- Regroupement d’espaces aériques
- Parois bien définies 1-3 mm
- Habituellement sous-pleural

Rayon de miel : attention aux pièges

Airspace enlargement with fibrosis

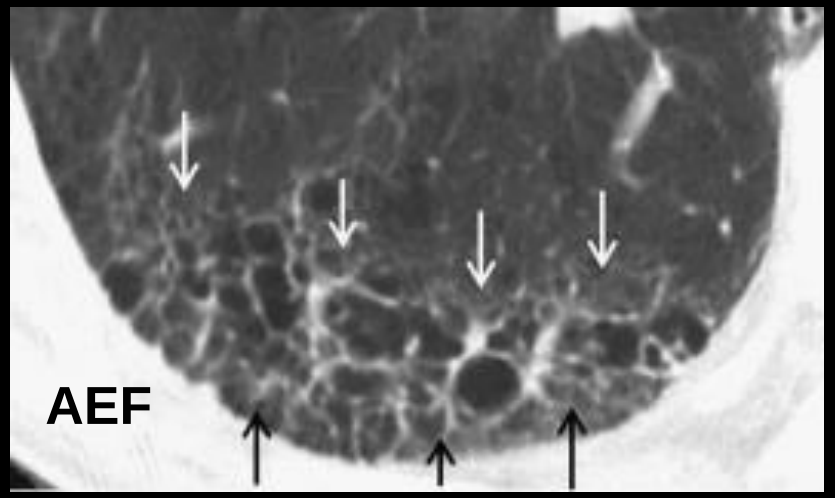

Watanabe Eur J Radiol 2015

- Légèrement à distance de la plèvre
- Parois <1 mm
- Pas de perte de volume

Comblement alvéolaire sur emphysème

Signes de fibrose

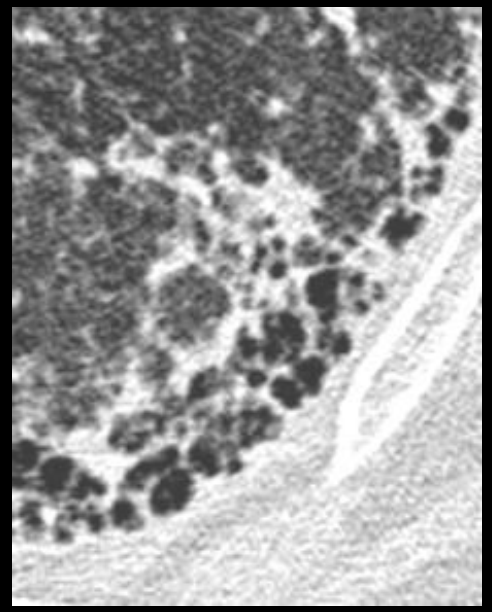

Rayon de miel

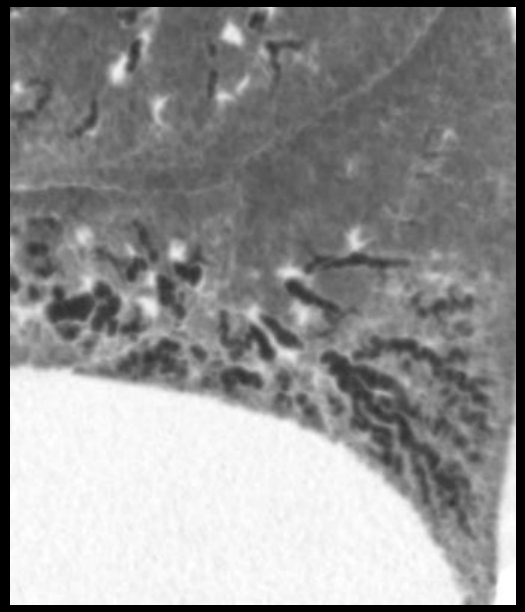

Bronchectasies de traction

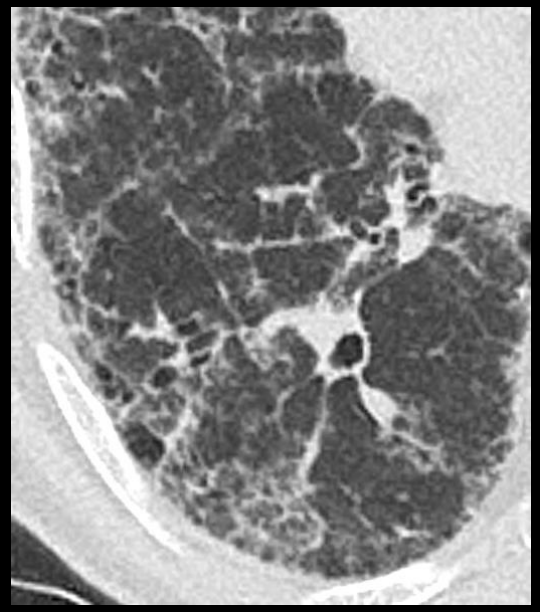

Réticulations irrégulières

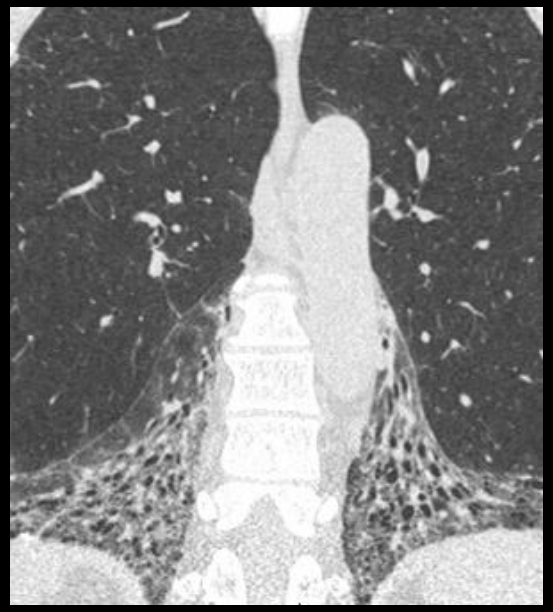

Perte de volume

Bronchectasies de traction

Dilatation des lumières bronchiques au sein de zones de verre dépoli / réticulations

Tortuosité dans les formes évoluées

Elément pronostique des PID fibrosantes

Périphériques

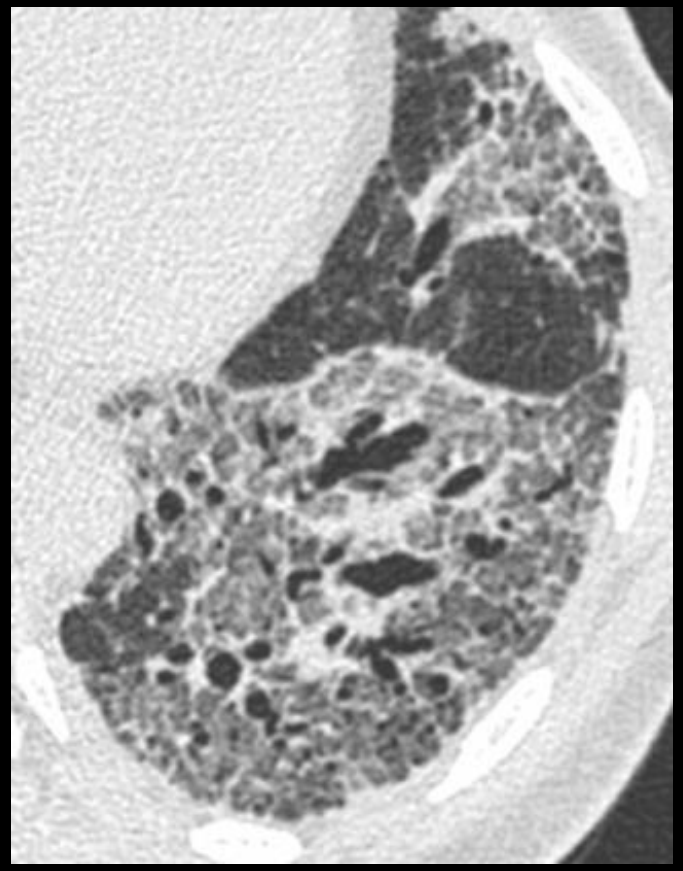

Centrales

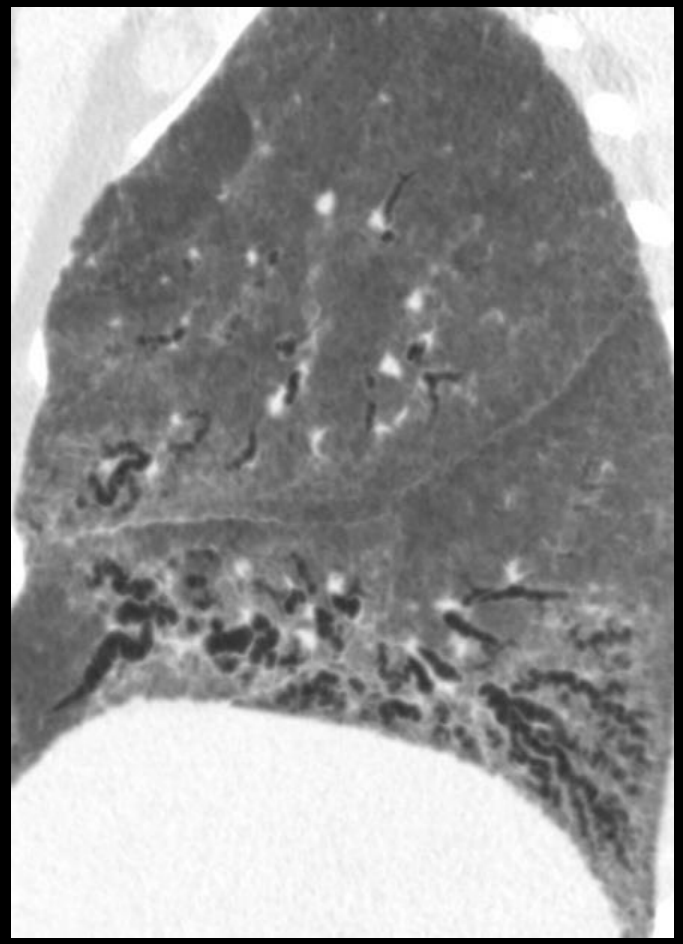

Intérêt du minIP

En conclusion

- Analyse sémiologique rigoureuse = étape indispensable de l'interprêtation
- Eviter les pièges de cause technique
- Utilisation en routine des post-traitements de base

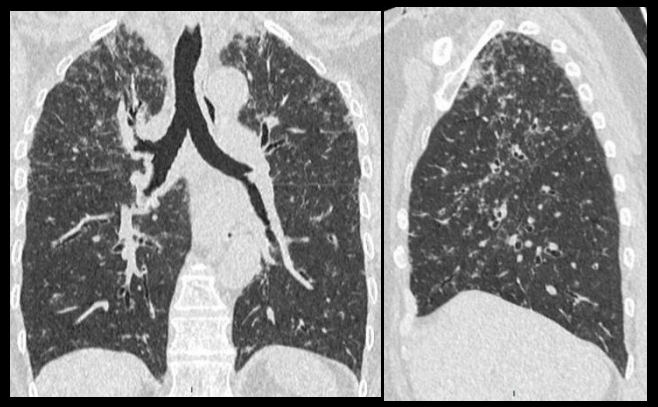

Distribution

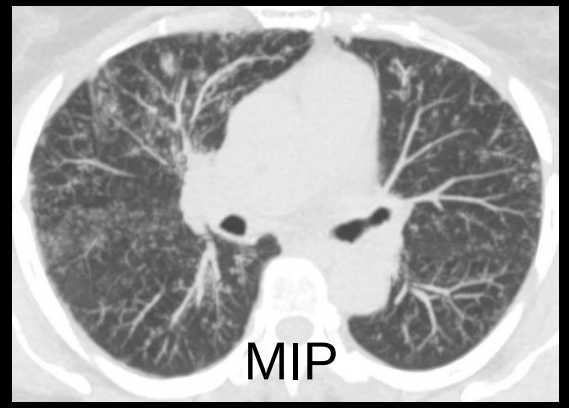

Nodules

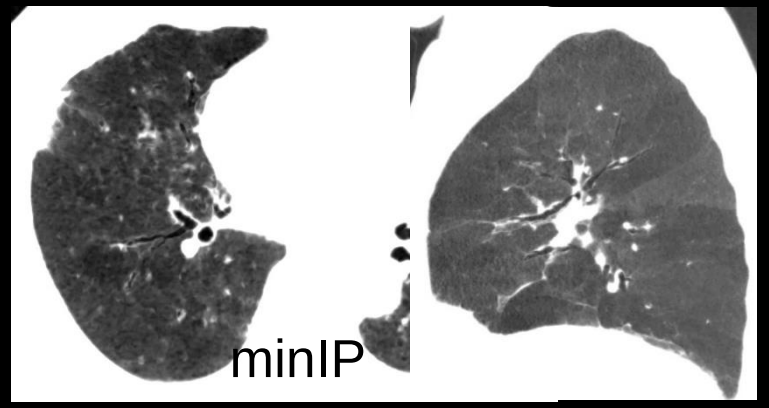

Mosaique
Bronchectasies/rayon de miel
Verre dépoli peu dense

- Intégration des données cliniques, environnementales, biologiques