Maladies Kystiques Pulmonaires

Abdellatif Tazi
Service de Pneumologie
Hôpital Saint-Louis, Paris, France

abdellatif.tazi@aphp.fr

Pas de conflit d'intérêt

Synopsis

- Définitions
- Démarche diagnostique
  - PID avec kystes associées
  - PID nodulo-kystiques
  - PID kystiques « pures »
    - ✓ LAM
    - ✓ HL pulmonaire
    - ✓ *BHD/DDCL*
- Synthèse

Définitions

- Diagnostic positif et caractérisation
  - TDM-HR pulmonaire ++

- Kyste
  - Hyperclarté parenchymateuse entourée d'une paroi fine: <2-4mm peut contenir du liquide ou du matériel solide

- Bulle: taille > 1cm, paroi < 1mm
- Bleb: bulle de taille < 1cm , sous pleurale ou pleurale, apicale
- Pneumatocèle: paroi fine, contexte, le plus souvent résolutif

- Cavité
  - Hyperclarté parenchymateuse entourée d'une paroi épaisse > 4mm
  - (condensation, masse, nodule) cavitaires

- Différencier de:
  - emphysème, bronchectasies kystiques
  - rayon de miel
  - (pneumothorax localisé)

Kystes

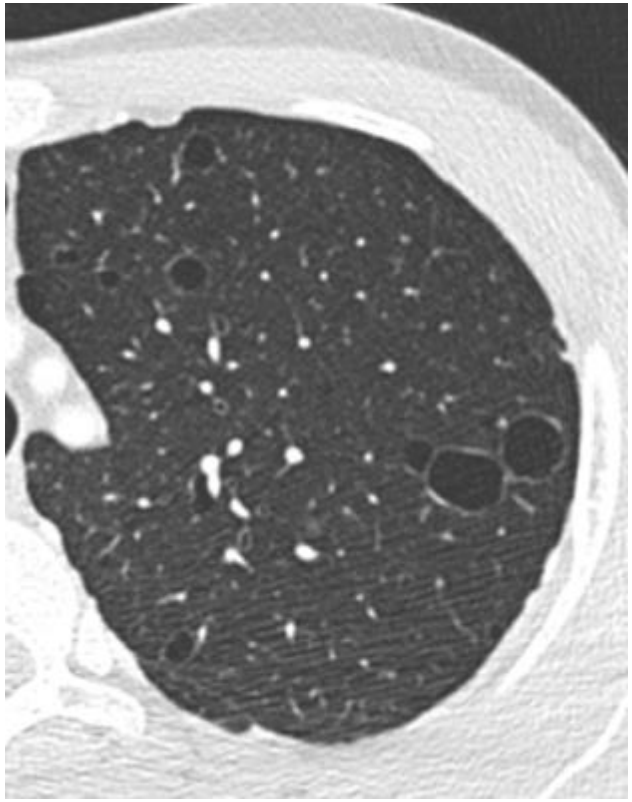

Bulles

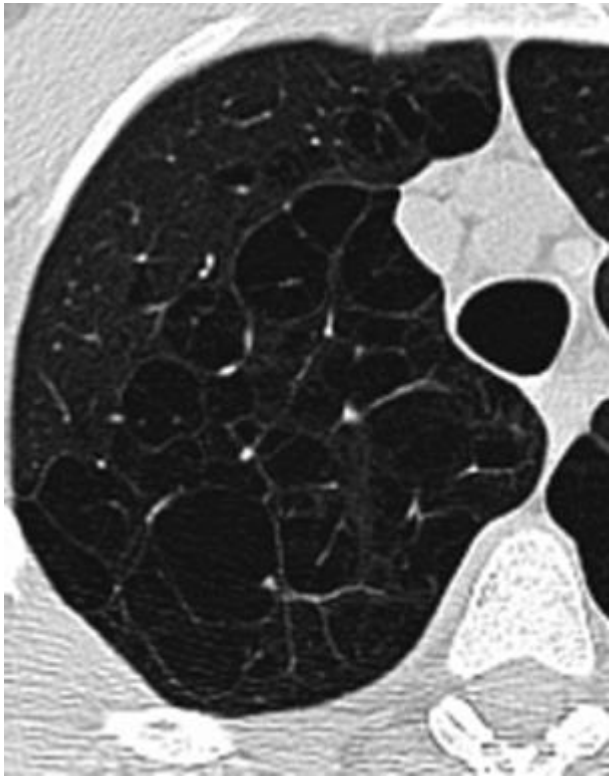

Cavités

PID Kystiques
Première approche

Diffuse Cystic Lung Disease at High-Resolution CT

Langerhans cell histiocytosis

Lymphangioleiomyomatosis

- Sporadic
- Associated with tuberous sclerosis complex

Follicular bronchiolitis and LIP

Amyloidosis, LCDD

Birt-Hogg-Dubé syndrome

Cystic metastases

Seaman et al. AJR 2011

- Analyse radiologique
  - distribution
  - anomalies associées
  - imagerie antérieure++
  - séquence évolutive

Kystes pulmonaires associées à une PID

Kystes ne sont pas la lésion prédominante

- Pneumopathie interstitielle lymphoïde (LIP)
  - Sjögren
  - Autres causes de LIP
- Pneumopathies d'hypersensibilité (PHS)
- Pneumopathie infiltrante macrophagique
  - RB/ILD-DIP (parfois HL sous-jacente)
- Pneumocystose
- Raretés
  - Tumeurs (sarcomes…..)
  - Amylose
  - Niemann Pick B, mastocytose….
  - ….
- Diagnostic repose sur autres lésions radiologiques, LBA, contexte.

LIP-Sjögren

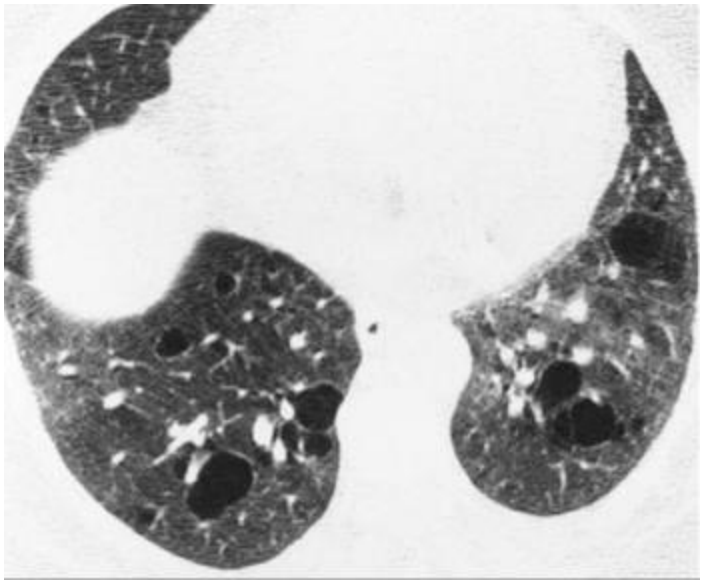

PHS

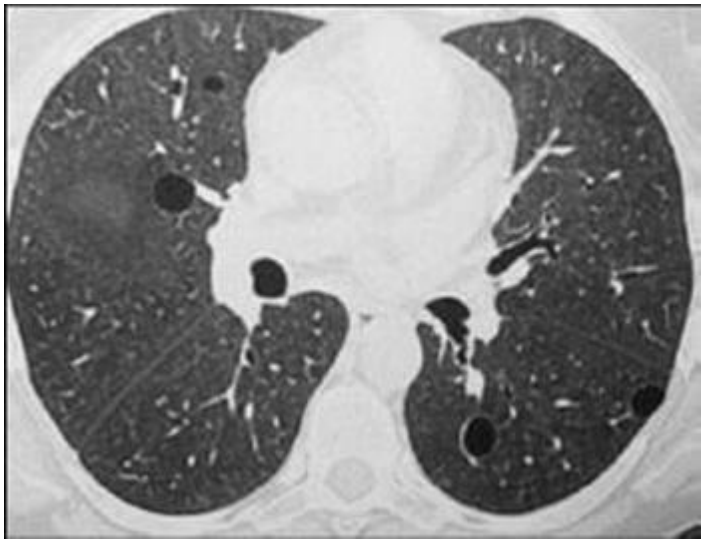

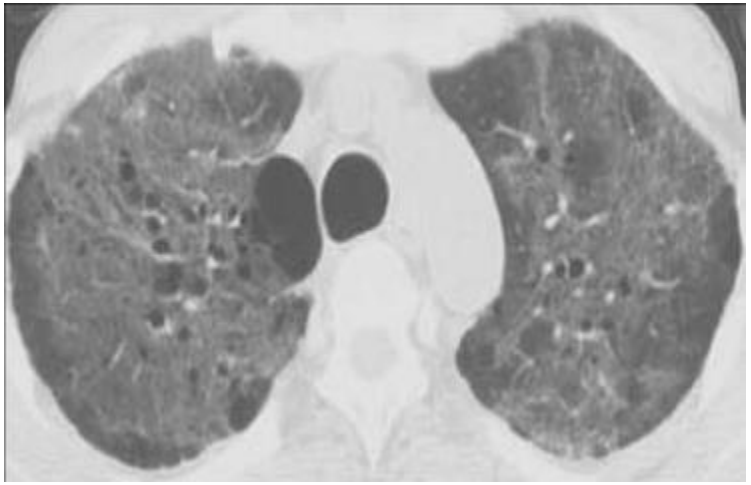

Pneumocystose

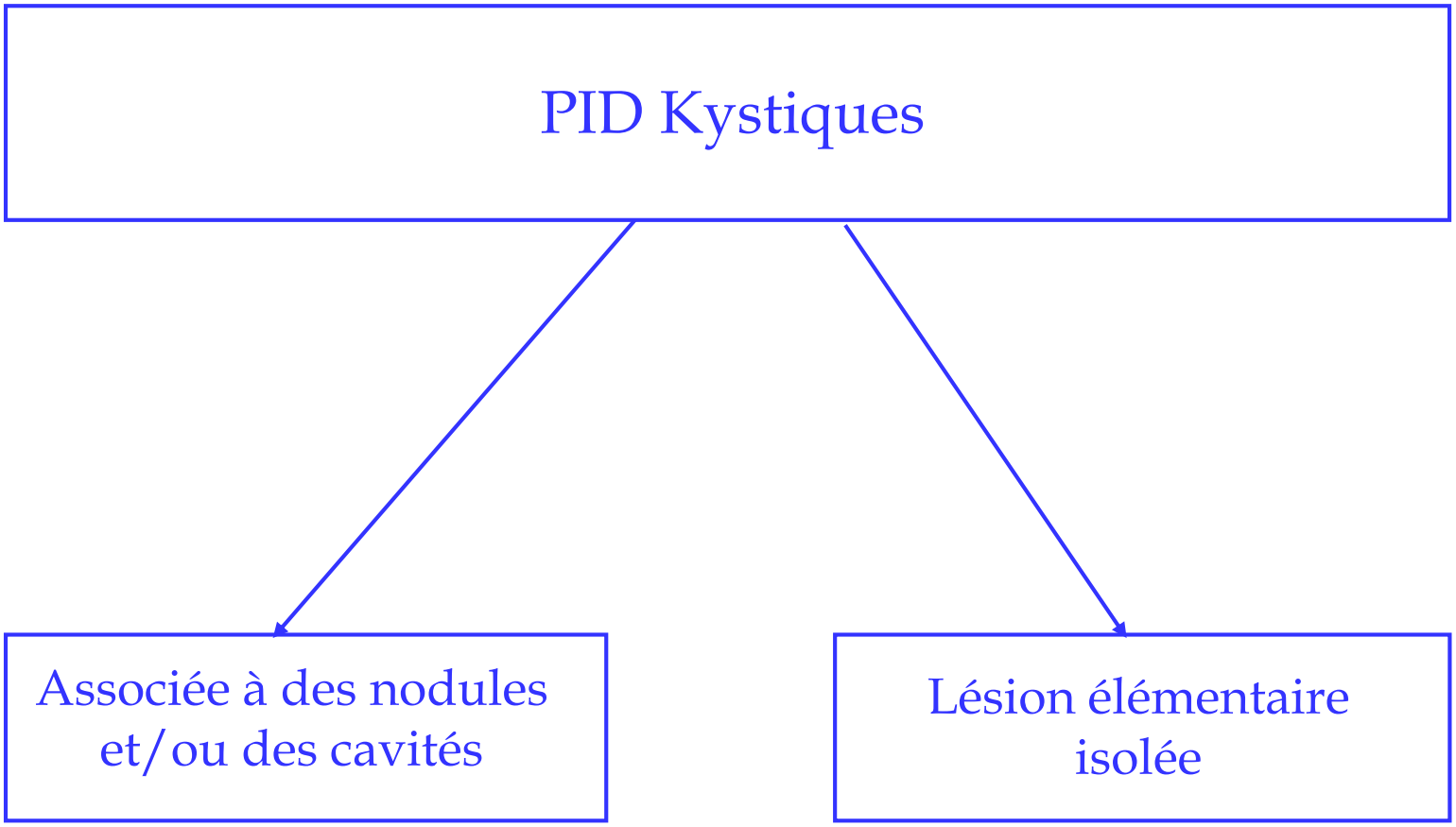
PID Kystiques
Associée à des nodules et/ou des cavités
Lésion élémentaire isolée

Kystes associées à des nodules et/ou cavités pulmonaires

- Infections
  - mycobactéries, mycoses endémiques (histoplasmose, coccidioidomycose…..)
  - *pneumocystis jiroveci* ++
- HL pulmonaire
- Métastases pulmonaires de certains cancers
- Amylose, dépôts de chaines légères
- ….
- (micronodules d'hyperplasie PII dans LAM/STB)
- Éléments d'orientation
  - tabac
  - pathologie connue (tumeur, hémopathie)
  - signes généraux
  - signes extra-thoraciques
  - immunodépression (lymphocytes sanguins), EPP
  - LBA++

Histiocytose Langerhansienne

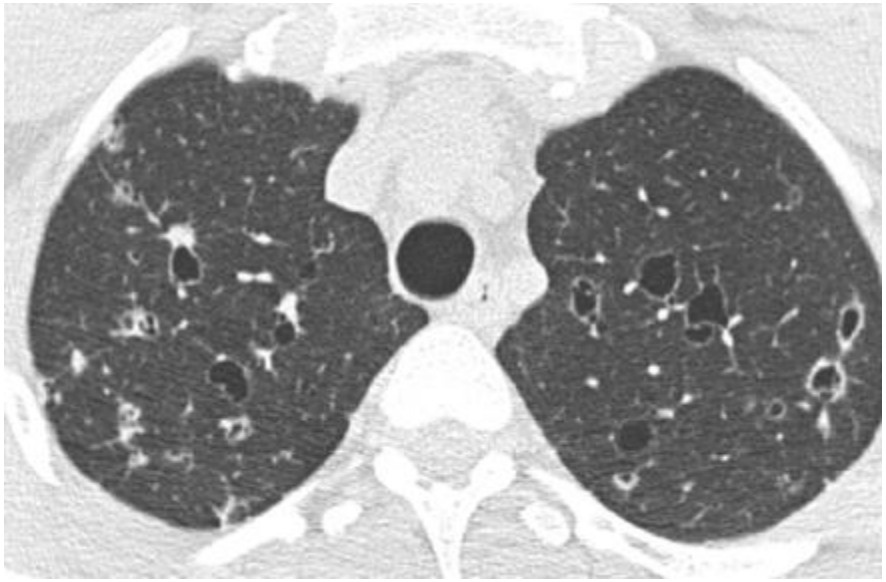

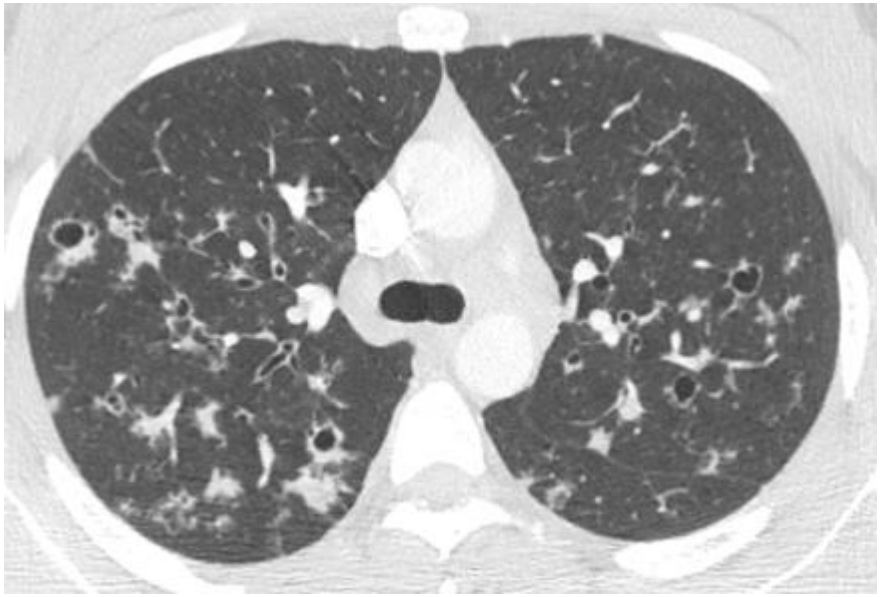

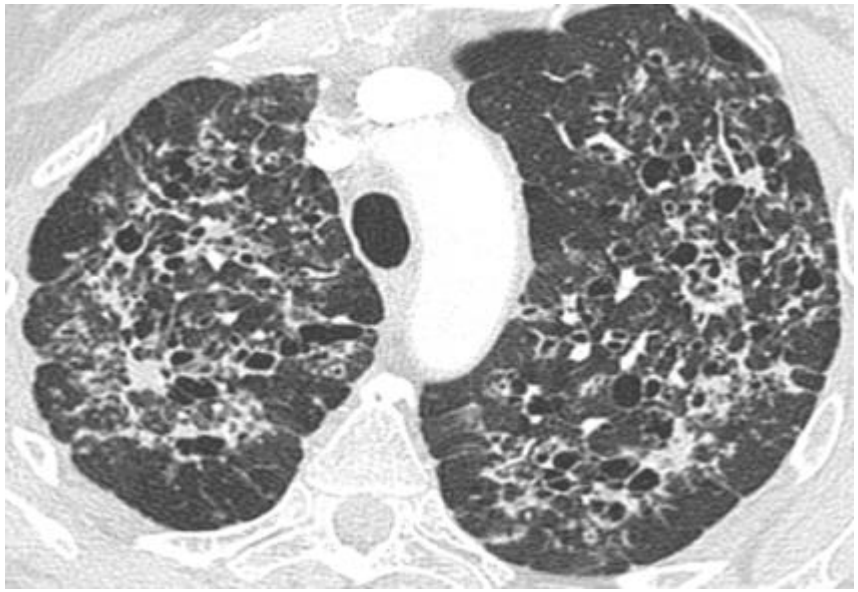

Pneumocytose

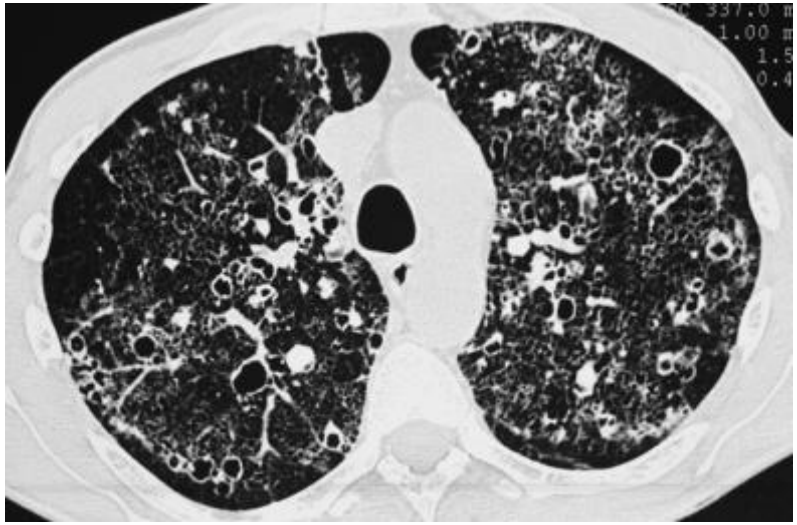

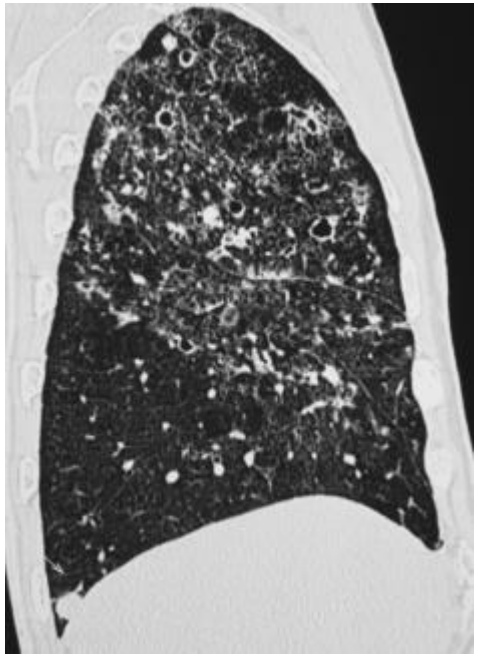

Métastases d'ADK colique

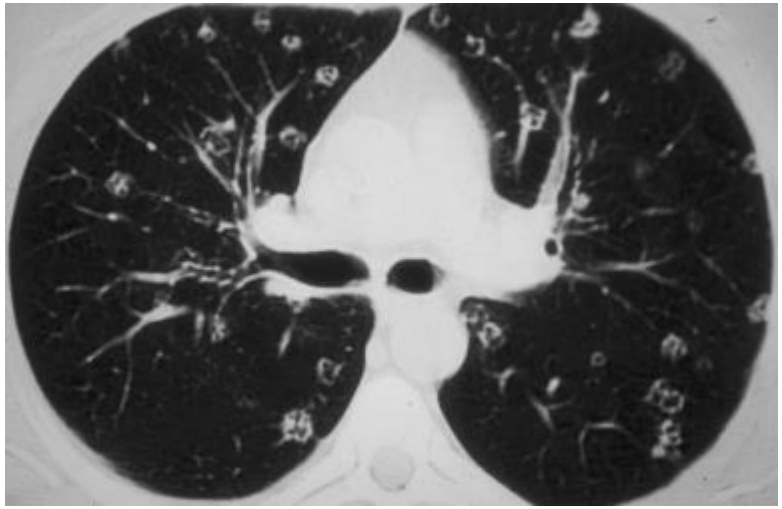

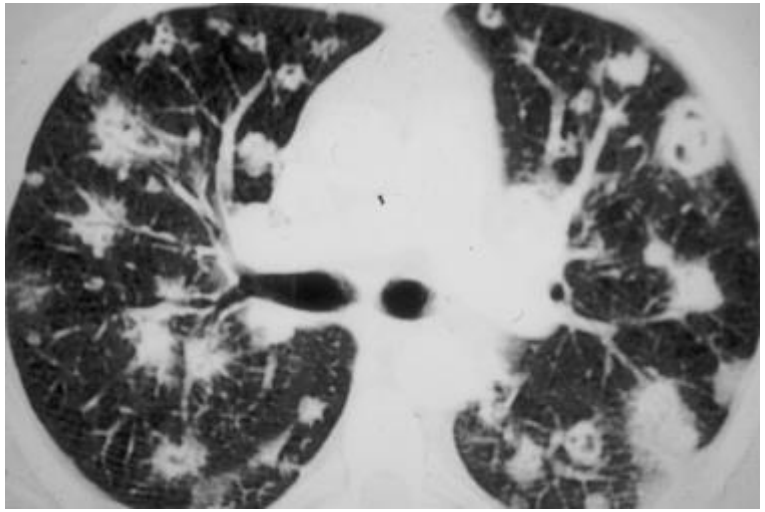

Sjögren + LIP + amylose + prolifération lymphoïde

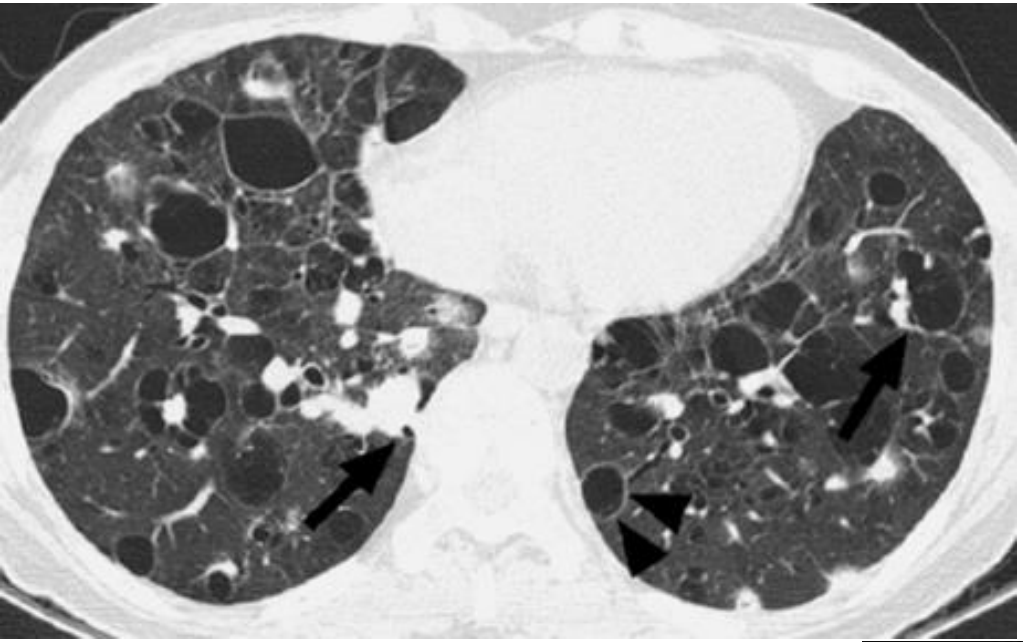

Pathologie pulmonaire kystique diffuse
Kystes seules lésions élémentaires

- Pièges diagnostiques
  - Emphysème
  - Bronchectasies (reconstructions)
- Lymphangioléiomyomatose pulmonaire (LAM)
  - sporadique
  - sclérose tubéreuse de Bourneville
- Histiocytose Langerhansienne pulmonaire (HL)
- Syndrome de Birt-Hogg-Dubé (BHD)
- Dépôts de chaines légères
- *LIP*
- Raretés
  - tumeurs (sarcomes, ORL, autres..)
  - neurofibromatose
  - ….

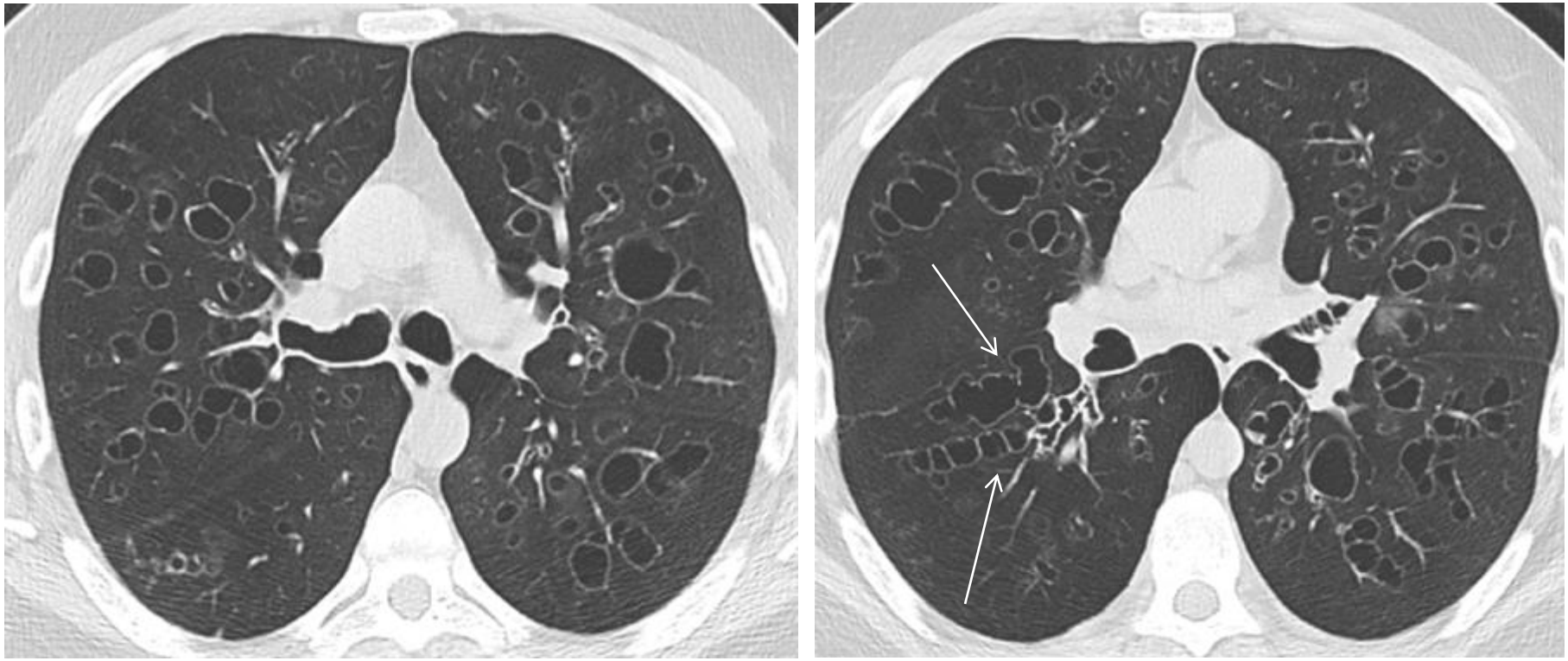

Bronchectasies

Lymphangioléiomyomatose (LAM)

- Pathologie rare de la femme jeune
  - médiane 35 ans
  - âge plus élevé dans séries récentes
  - cas post ménopausiques
- Dyspnée d'effort, toux
- PNO récurrent ++
- Hémoptysie, chylothorax, chyloptysie
- Atteintes extra thoraciques
  - formes sporadiques
  - sclérose tubéreuse de Bourneville
- EFR:
  - TVO (réversible), piégeage aérique, altération de la D_{LCO}

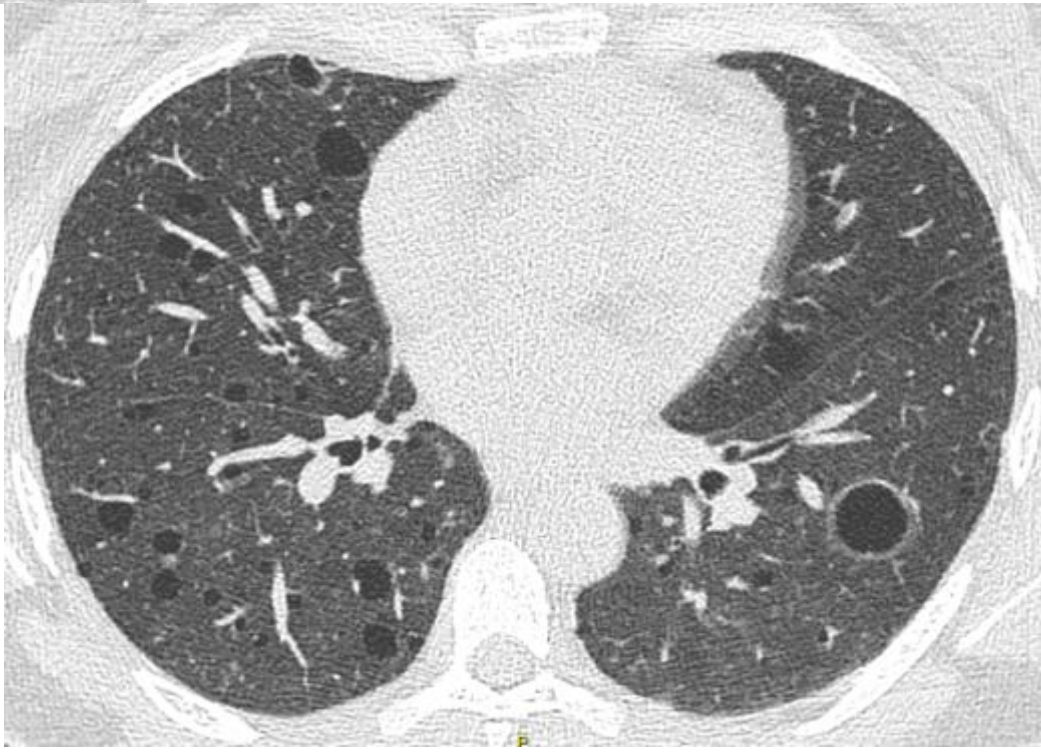

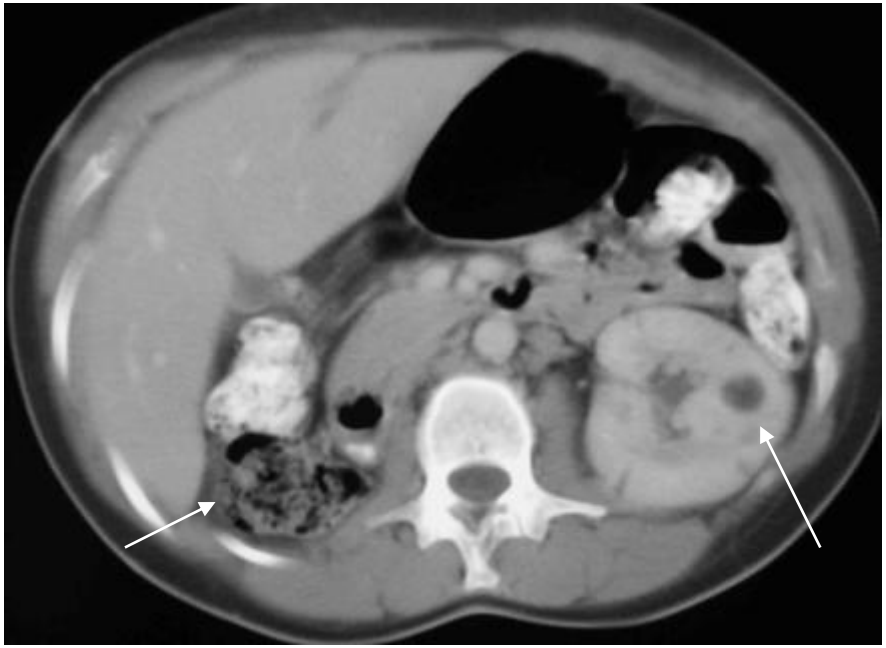

Tuberous sclerosis

Panel: Diagnostic criteria for tuberous sclerosis[7]

Major features

- Facial angiofibromas or forehead plaque pits in dental enamel
- Non-traumatic ungula or periungual fibroma
- Hypomelanotic macules (three or more)
- Shagreen patch (connective tissue nevus) migration lines
- Multiple retinal nodular hamartomas
- Cortical tuber
- Subependymal nodule
- Subependymal giant-cell astrocytoma
- Cardiac rhabdomyoma, single or multiple
- Lymphangiomyomatosis, renal angiomyolipoma, or both

Minor features

- Multiple, randomly distributed
- Hamartomatous rectal polyps
- Bone cysts
- Cerebral white matter radial
- Gingival fibromas
- Non-renal hamartoma
- Retinal achromic patch
- Confetti-like skin lesions
- Multiple renal cysts

Curatolo et al. Lancet 2008

Angiofibromes

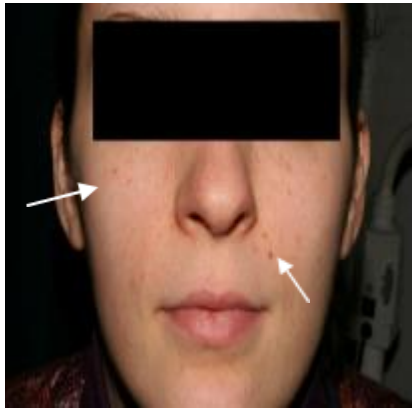

Plaques peau de chagrin

Fibromes péri-unguéaux

Anomalies de l'émail dentaire

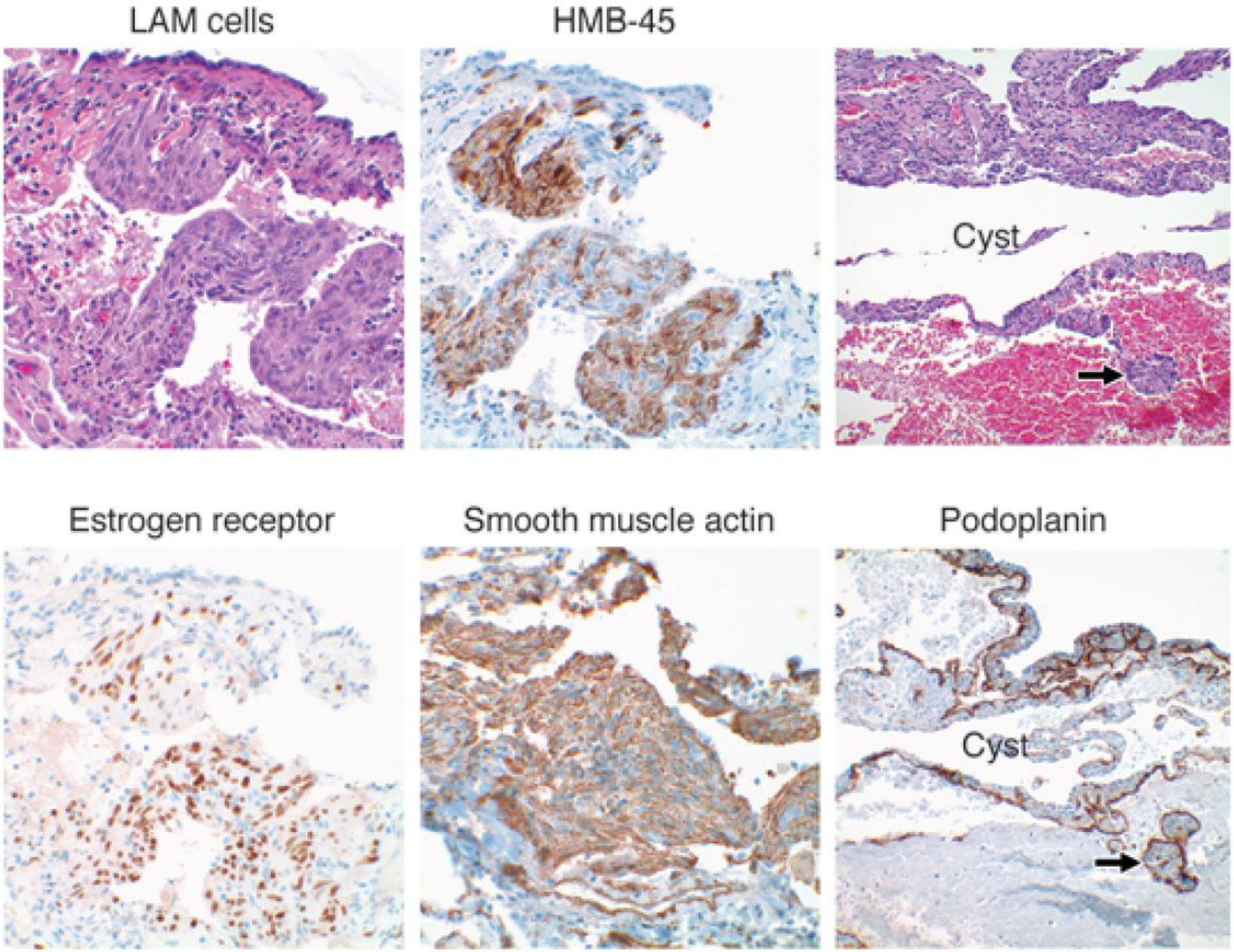

Henske & McCormack JCI 2012

Serum Vascular Endothelial Growth Factor-D Prospectively Distinguishes Lymphangioleiomyomatosis From Other Diseases

Young et al. Chest 2010

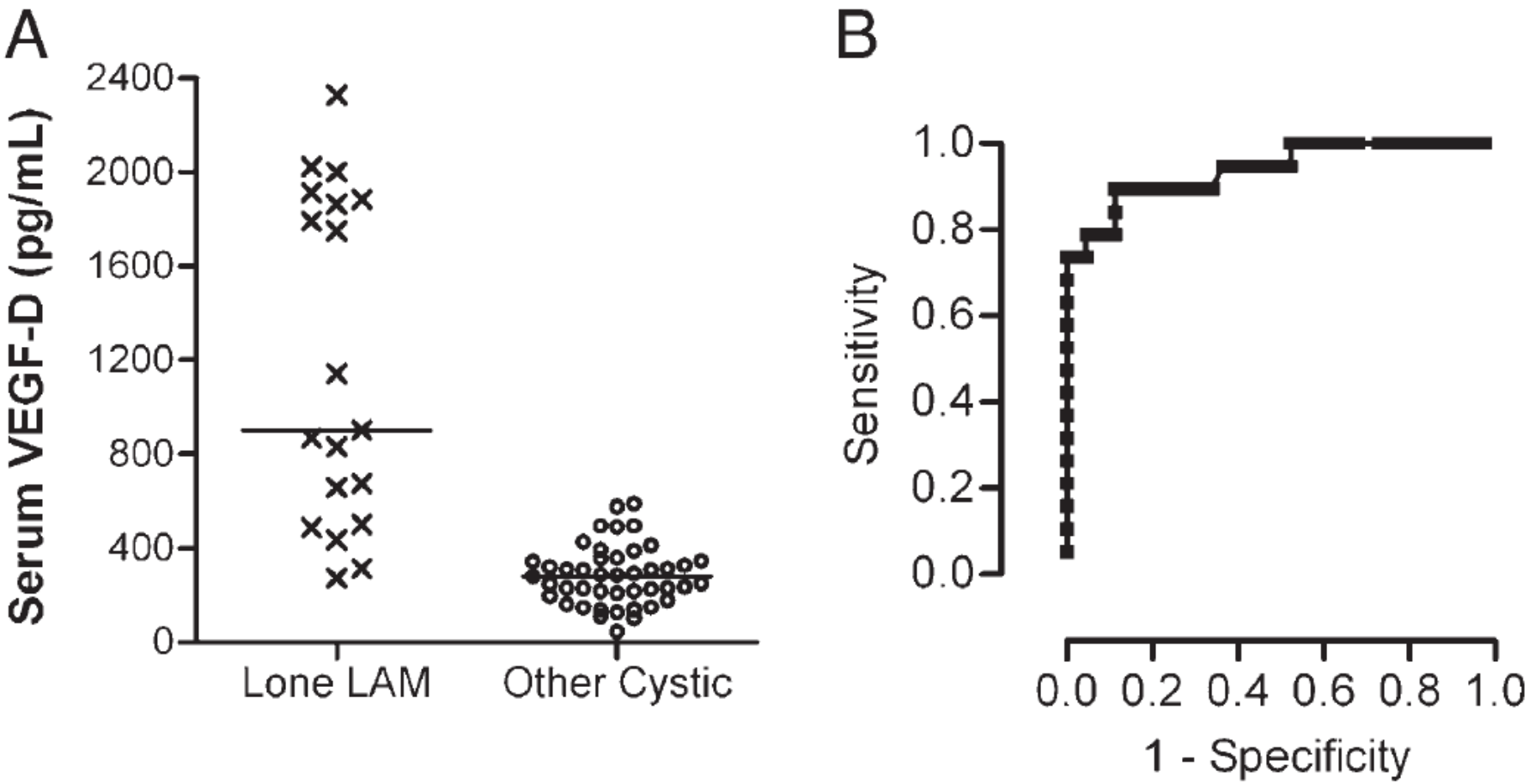

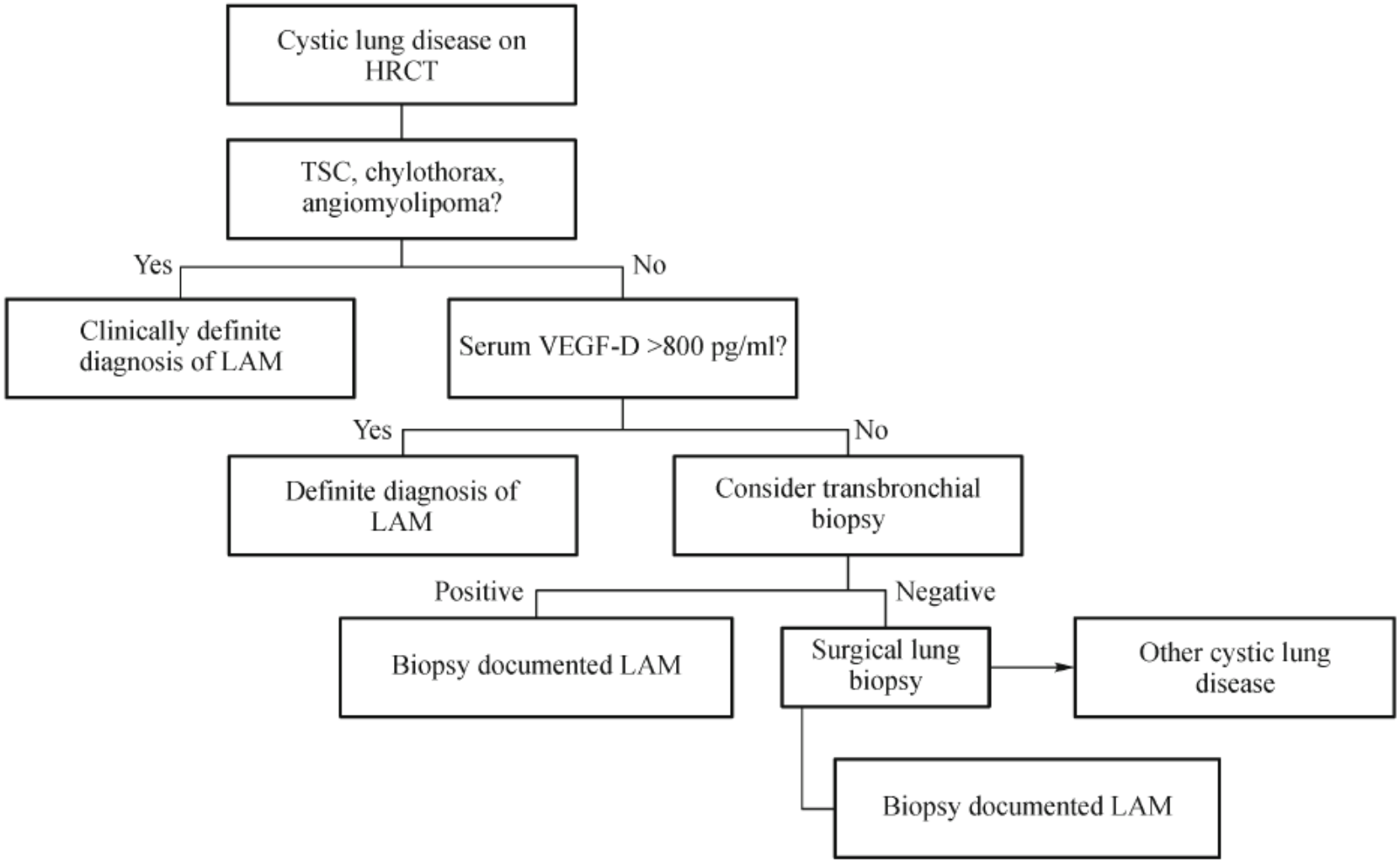

Fig. 6 Proposed diagnostic algorithm for females with cystic lung disease.

Meraj et al. Front Med 2012

Lymphangioleiomyomatosis — a wolf in sheep's clothing

JCI 2012

Elizabeth P. Henske[1] and Francis X. McCormack[2]

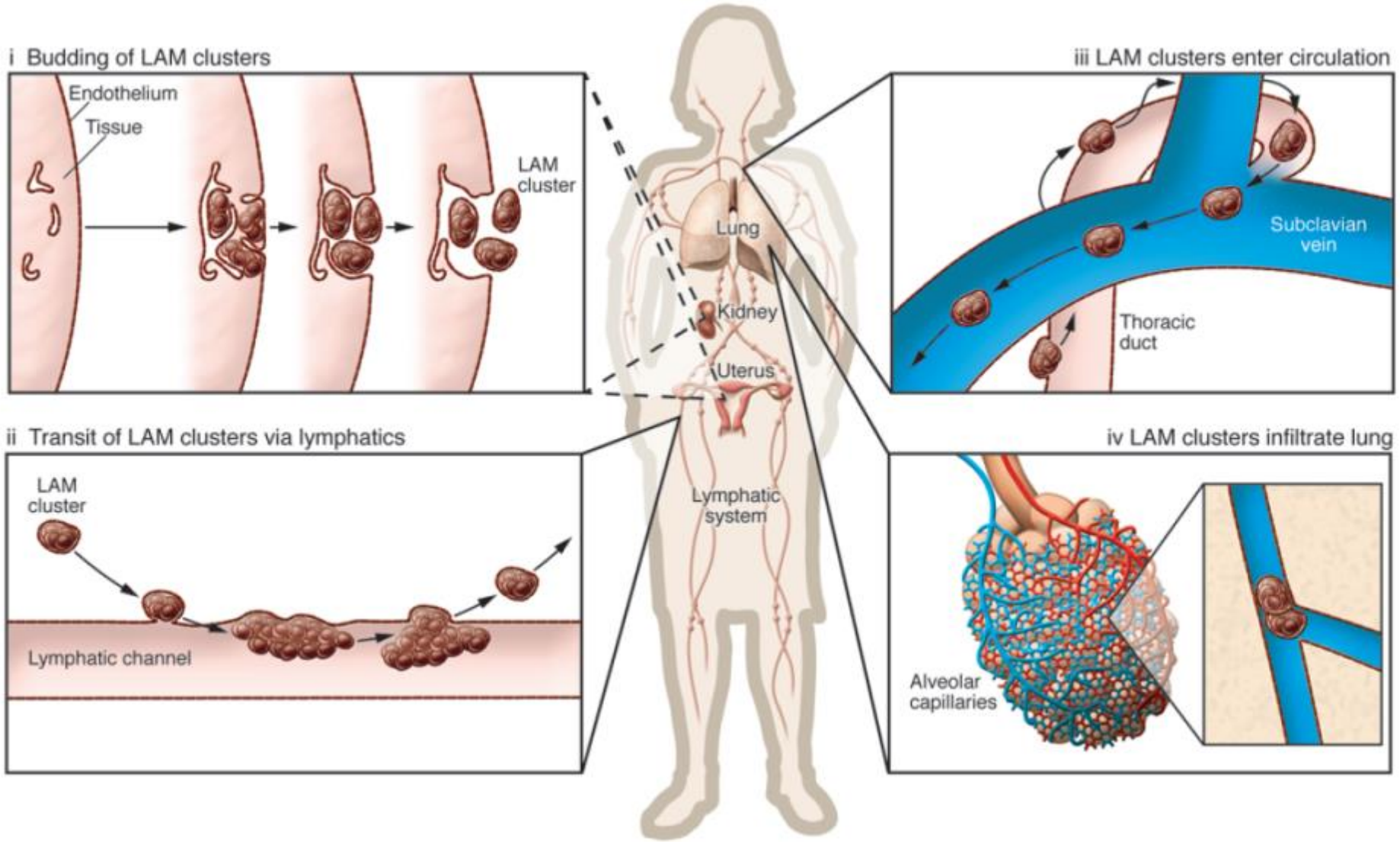

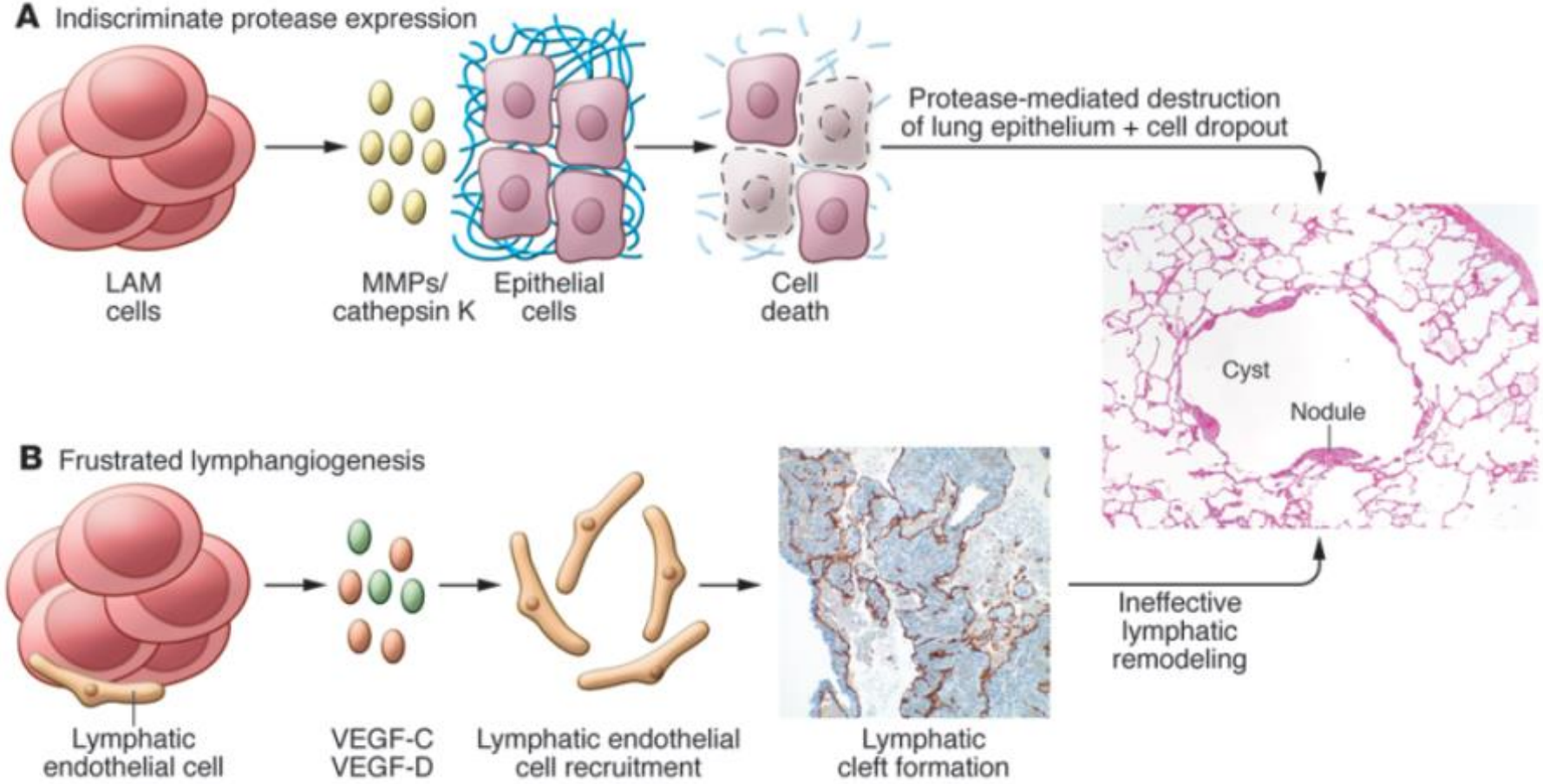
A Indiscriminate protease expression
LAM cells
MMPs/ cathepsin K
Epithelial cells
Cell death
Protease-mediated destruction of lung epithelium + cell dropout
Cyst
Nodule
B Frustrated lymphangiogenesis
Lymphatic endothelial cell
VEGF-C VEGF-D
Lymphatic endothelial cell recruitment
Lymphatic cleft formation
Ineffective lymphatic remodeling

Lymphangioleiomyomatosis — a wolf in sheep's clothing

JCI 2012

Elizabeth P. Henske[1] and Francis X. McCormack[2]

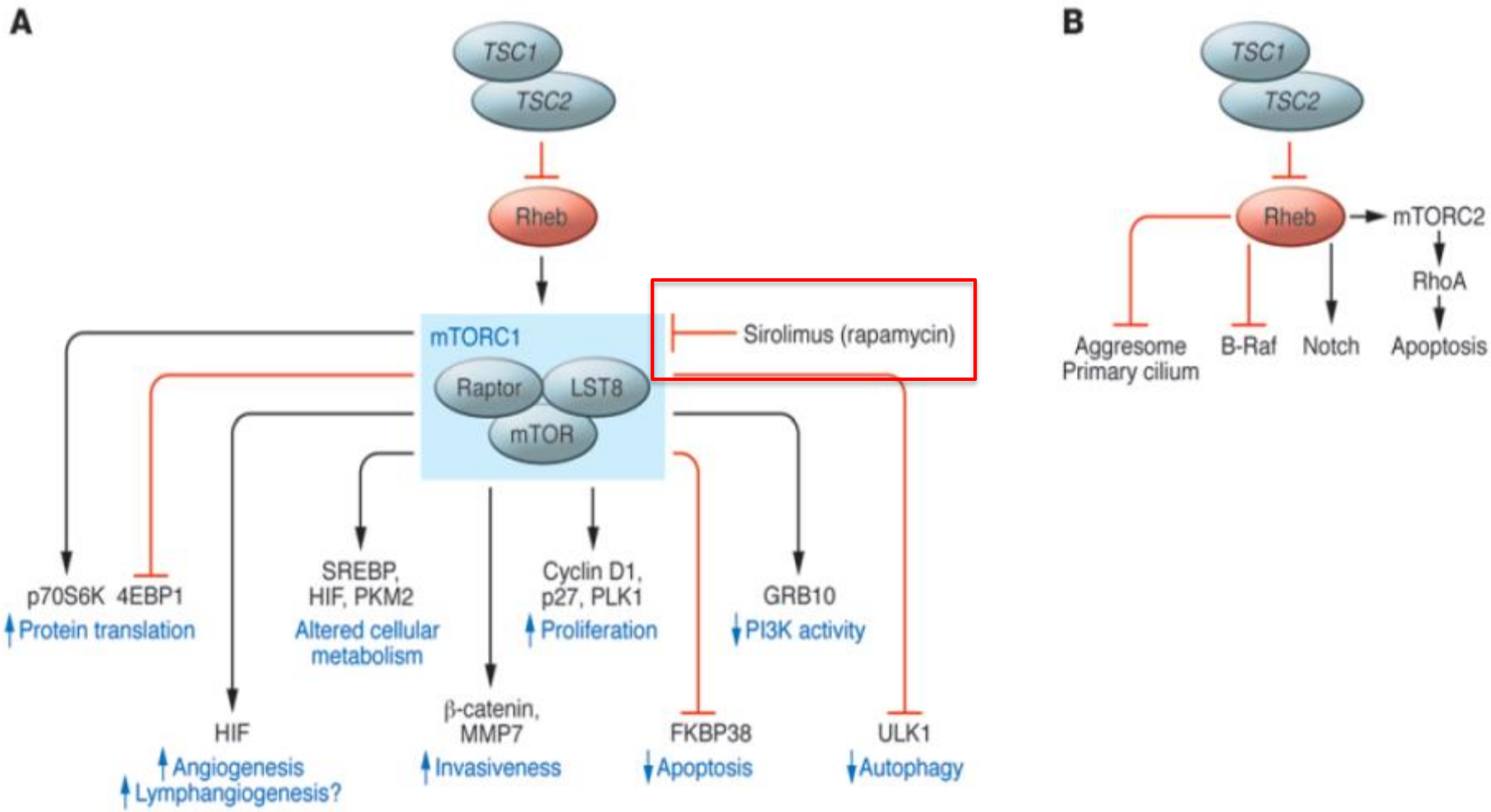

The NEW ENGLAND JOURNAL of MEDICINE

Efficacy and Safety of Sirolimus in Lymphangioleiomyomatosis

McCormarck et al. 2011

A

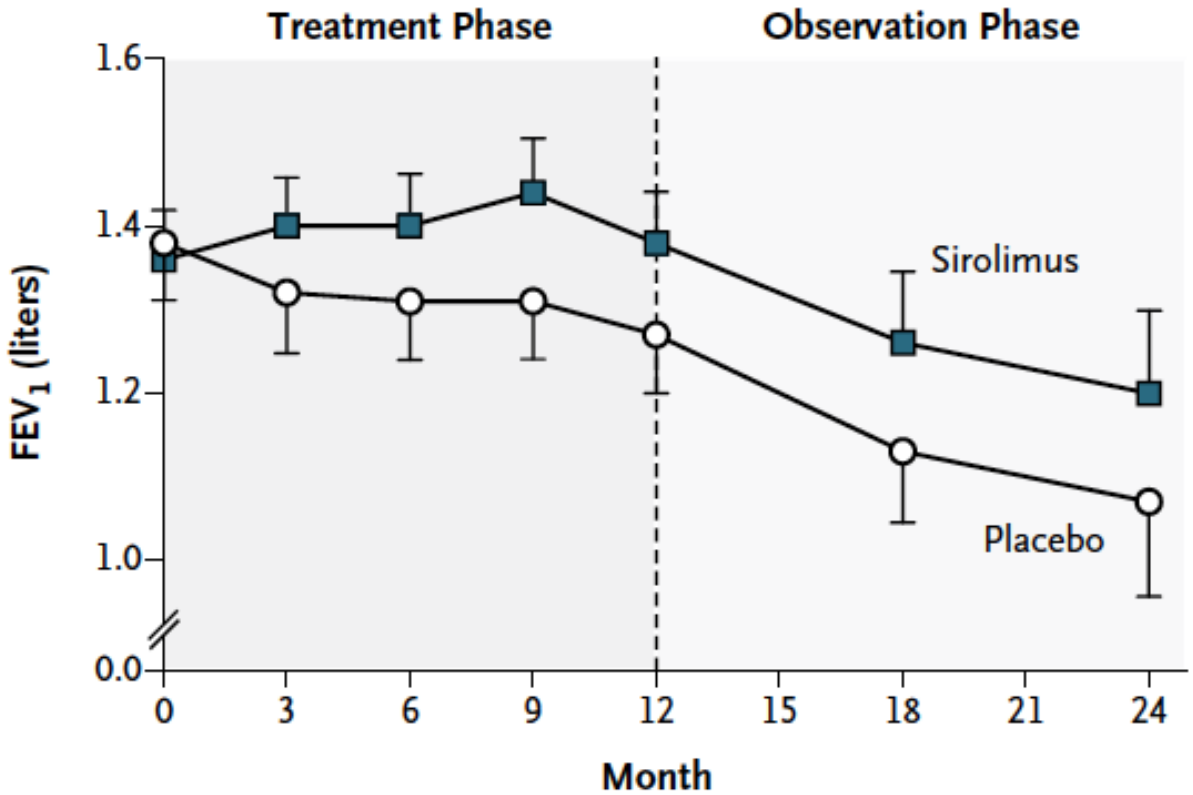

No. at Risk							
Sirolimus	46	43	41	38	41	21	14
Placebo	43	40	42	39	34	22	13

Serum VEGF-D concentration as a biomarker of lymphangioleiomyomatosis severity and treatment response: a prospective analysis of the Multicenter International Lymphangioleiomyomatosis Efficacy of Sirolimus (MILES) trial

Young L et al. ***Lancet Respir Med 2013***

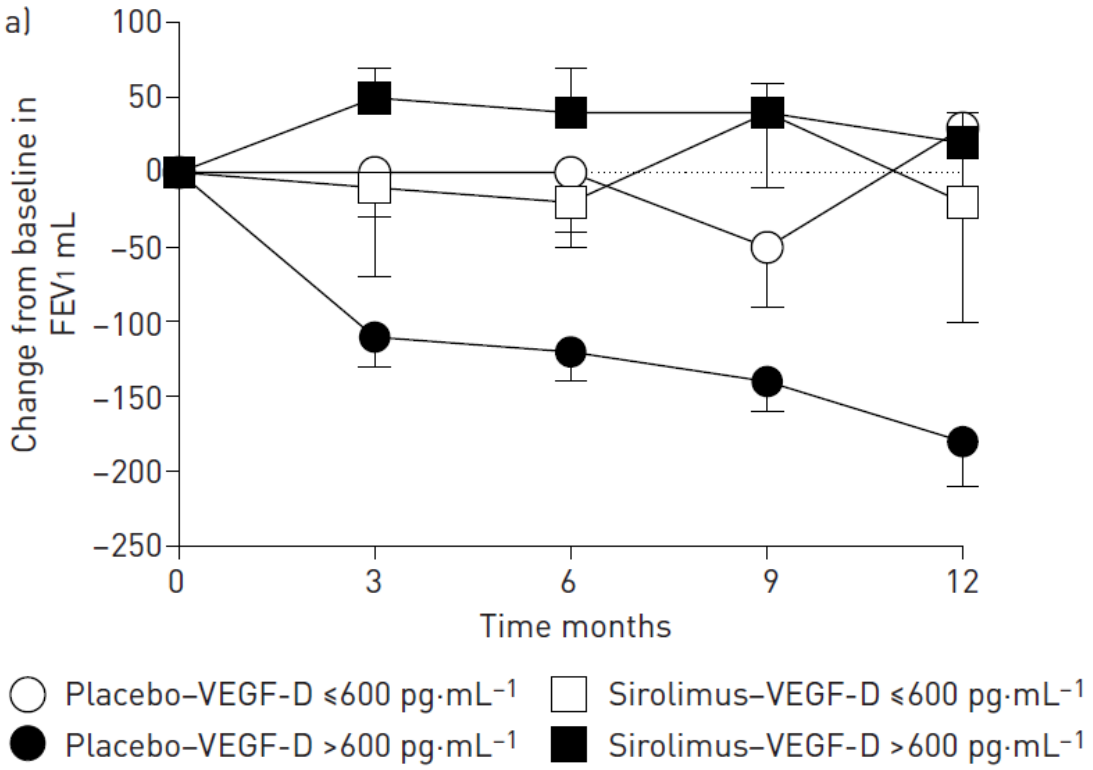

Gupta et al. ERJ 2019

Everolimus for angiomyolipoma associated with tuberous sclerosis complex or sporadic lymphangioleiomyomatosis (EXIST-2): a multicentre, randomised, double-blind, placebo-controlled trial *Bissler et al. Lancet 2013*

Everolimus for the treatment of lymphangioleiomyomatosis: a phase II study *Goldberg et al. ERJ 2015*

Sustained Effects of Sirolimus on Lung Function and Cystic Lung Lesions in Lymphangioleiomyomatosis *Yao et al. AJRCCM 2014*

Long-term efficacy and safety of sirolimus therapy in patients with lymphangioleiomyomatosis *Hu et al. OJRD 2019*

Prise en charge de la LAM

- Mesures générales (sevrage tabagique, vaccinations, activité physique adaptée, oxygénothérapie)
- Bronchodilatateurs inhalés (réversibilité TVO)
- Pneumothorax: prévention et prise en charge spécifique
  - voyages aériens
- Eviction estrogènes (contraception et post ménopause)
- Grossesse?
- Pleurésie chyleuse, angiomyolipomes, lymphangioleiomyomes
- Inhibiteurs de mTOR dans les formes progressives
- Transplantation pulmonaire
- Prise en charge multidisciplinaire

HL pulmonaire de l'adulte

- PID kystique diffuse rare, sporadique
- Infiltration et destruction de la paroi des bronchioles distales par des cellules *CD1a+/langerine+*
  - atteinte variable des autres compartiments pulmonaires (interstitiel, vasculaire): diversité des phénotypes cliniques
- Sujets jeunes des 2 sexes (20-40 ans)
- >90 fumeurs ou ex-fumeurs
  - ≃20% cannabis (registre CRMR)
- Prévalence inconnue (sous-estimée)
  - ≃3-5% des PID
  - rareté chez les sujets de peau noire
  - bien décrite chez les sujets asiatiques

Vassallo R, Harari S, Tazi A. Thorax 2017

The natural history of adult pulmonary Langerhans cell histiocytosis: a prospective multicentre study

Tazi et al. OJRD 2015

Table 1 Baseline characteristics of the patients*

Characteristic	N = 58
Age, yrs	35.6 ± 10.8
Female sex, n (%)	31 (53)
Race, n (%)	
White	55 (95)
Other	3 (5)
Smoking history, pack-years	21 ± 17
At diagnosis, n (%)	
Current smokers	56 (97)
Ex-smokers	2 (3)
Clinical features, n (%)	
Asymptomatic	21 (36)
Cough	30 (52)
Dyspnoea	26 (45)
NYHA class II/III	23/2
History of pneumothorax	11 (19)
Constitutional symptoms†	6 (10)

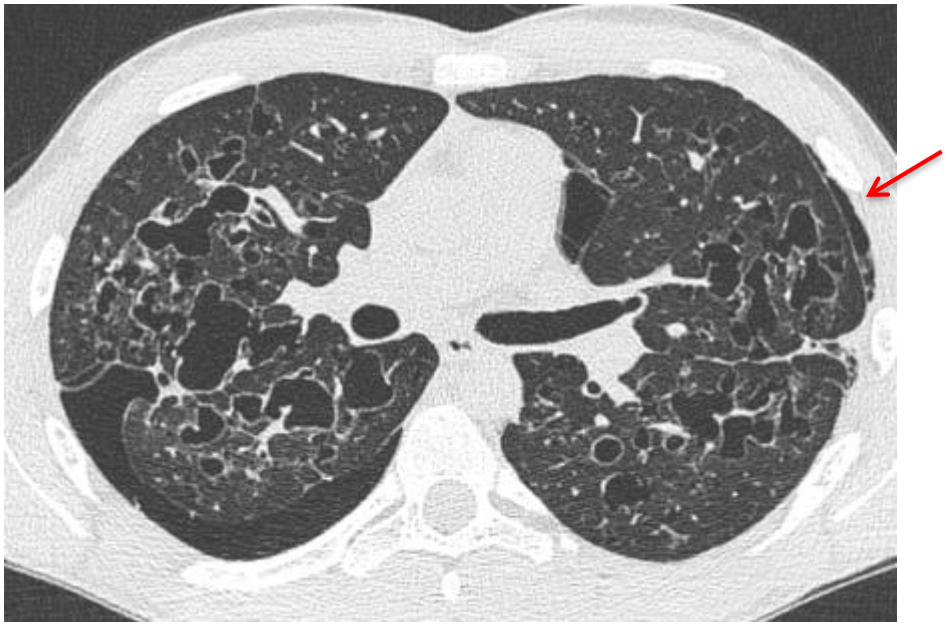

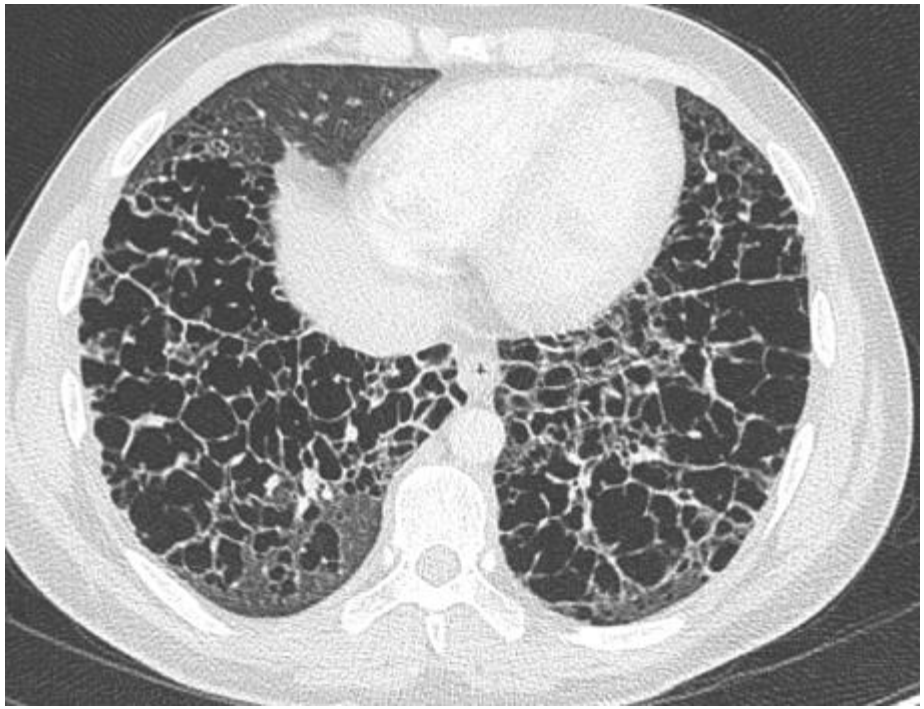

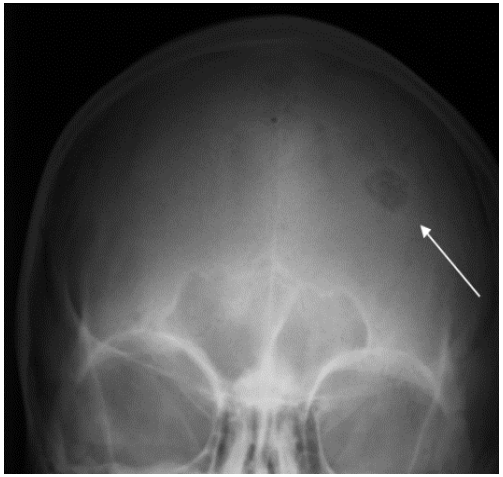

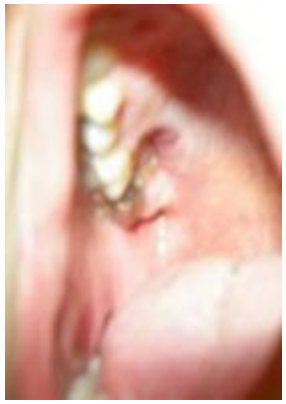

Syndrome polyuro-polydipsique

Normal lung function, n (%)	7 (12)
Restriction, n (%)‡	5 (9)
Obstruction, n (%)‡	15 (26)
Bronchial hyperreactivity, n (%)‡	6 (10)
DL_{CO} <80% predicted, n (%)‡	49 (87)

TABLE 1 The characteristics of the patients at the time of their pulmonary Langerhans' cell histiocytosis diagnosis

Characteristic	Subjects
Subjects n	49
Age yrs	30.5±7.2
Male sex	24 (49)
TLC# % pred	100.4±16.5
FVC % pred	89.1±18.6
RV# % pred	129.4±47.8
RV/TLC# % pred	126.5±38.0
FEV_1 % pred	77.6±21.9
FEV_1/FVC%	72.8±12.6
$DL_{,CO}$% of pred (n=42)	62.8±22.6

Tazi et al. ERJ 2012

Altération de la fonction respiratoire (TVO++) corrélée à l'étendue des kystes pulmonaires

Fibroscopie/LBA

- Macroscopie normale/inflammation (tabac)
- Biopsies bronchiques : diagnostics ≠
- BTB: rendement diagnostique=15-50%
- LBA
  - alvéolite macrophagique (consommation tabac quotidienne)
  - augmentation discrète des éosinophiles (≤10%)
  - pas lymphocytaire
- Augmentation des cellules CD1a+ (langerine)
  - pièges techniques
  - ≥ 5% CD1a+: minorité de cas
- Eliminer infection (signes généraux)

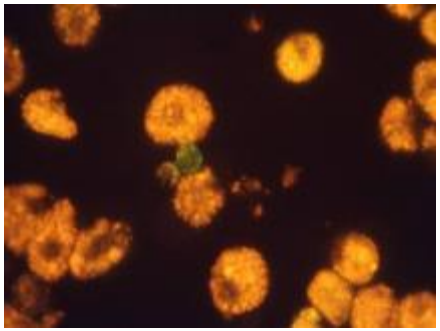

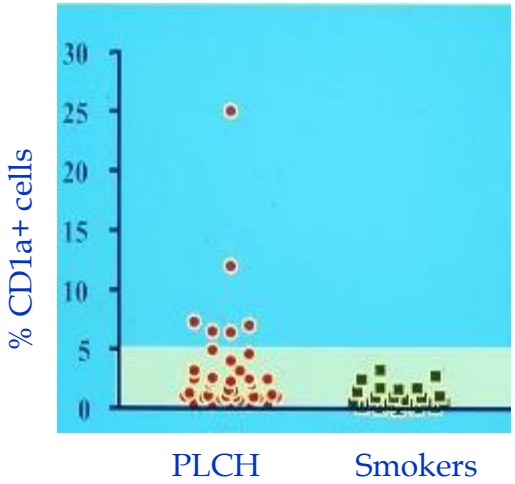

Lommatzsch et al. Respir Med 2016
Baqir et al. J Bronchol Intervent Pulmonol 2013
Harari et al. Respir Med 2012
Smetana et al. Virchows Arch 2004
Tazi et al. Thorax 2000

Histopathologie

- Lésions focales, d'âge différent, bronchiolo-centrées
- Extension aux alvéoles adjacents, artérioles et parfois veinules
- Orientation TDM ++ (nodules) (VATS)
- Fragment tissulaire de taille suffisante
- Immuno-histochimie
  - CD1a, langerine (PS100 non spécifique)
- *Mutations*
- (congélation)

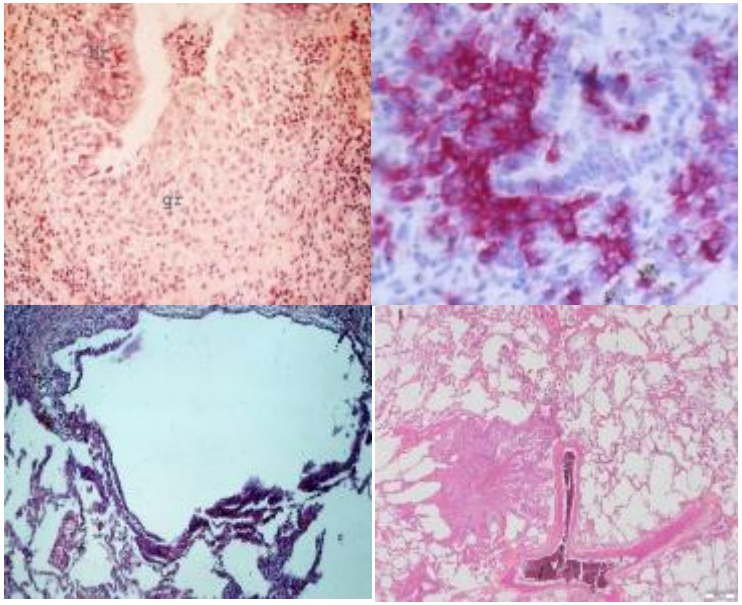

Bilan initial et modalités de suivi

- Examen clinique complet, y compris stomatologique ++
- NFS plaquettes, CRP, ionogramme sanguin urée, créatinine, bilan hépatique, EPP
- *Osmolarité des urines du matin??*
- *Radiographies du squelette entier avec panoramique dentaire??*
- Echo-doppler cardiaque de référence?
- Fonction des localisations
- Suivi systématique tous les 3 à 6 mois pendant les 2 premières années
  - clinique, radiographie de thorax, fonction ventilatoire ++
  - baisse isolée ou disproportionnée de D_{LCO}: écho cœur (HTP)

Evolution spontanée

- Très variable, difficile à prévoir au diagnostic (sauf HTP sévère)

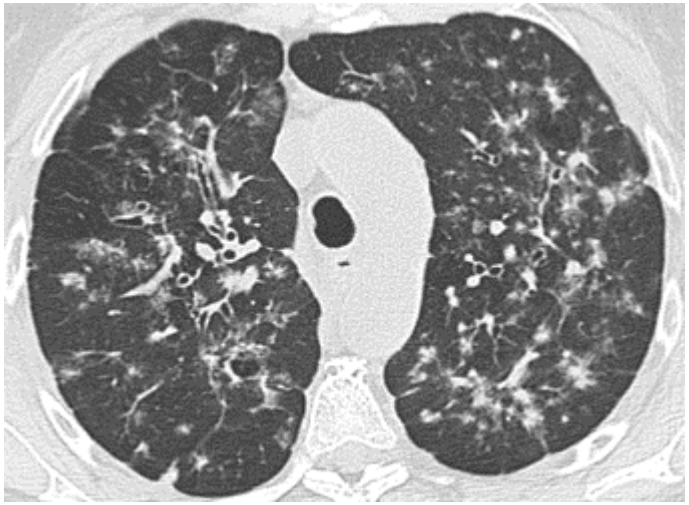

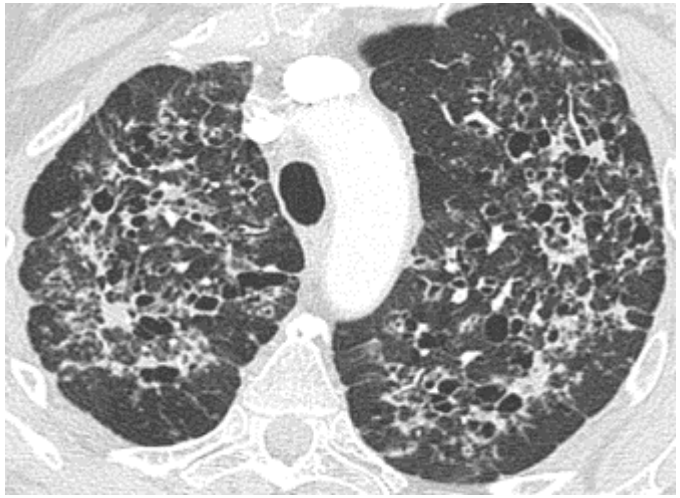

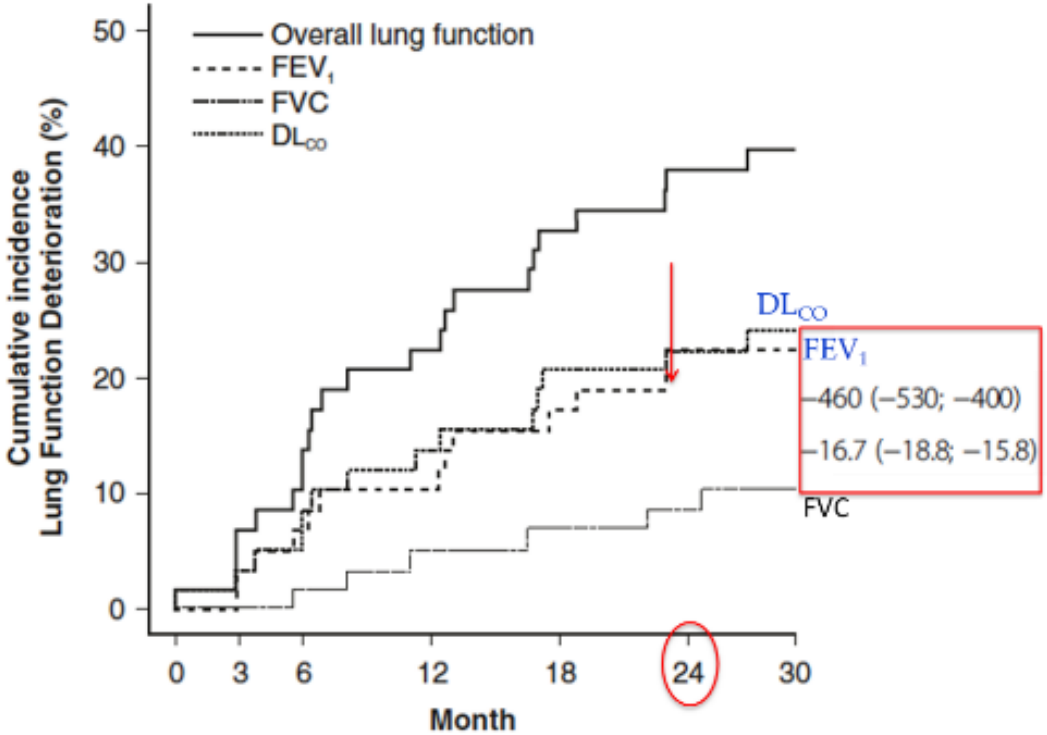

Tazi et al. OJRD 2015

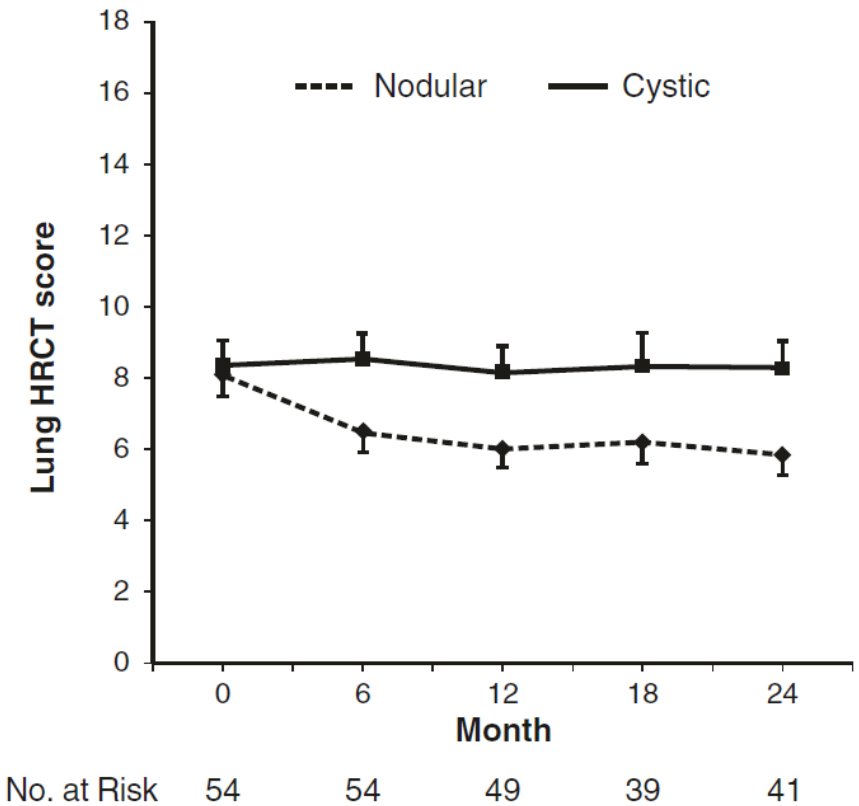

Hypertension Pulmonaire

- Patient de 58 ans, diagnostic histologique en février 04 par biopsie chirurgicale

	Décembre 03	Juillet 04	Octobre 04
Dyspnée NYHA	II	III	III
VEMS	94 %	100 %	98 %
CV	86 %	90 %	101 %
Tiffeneau	77 %	75 %	73 %
TLCO	66 %	39 %	41 %
PaO_2	72 mmHg	64 mmHg	53 mmHg

- Échographie cardiaque octobre 04: « normale », IT non mesurable
- KT droit novembre 2004: PAPm à 41 mmHg, IC à 3 l/min/m^2

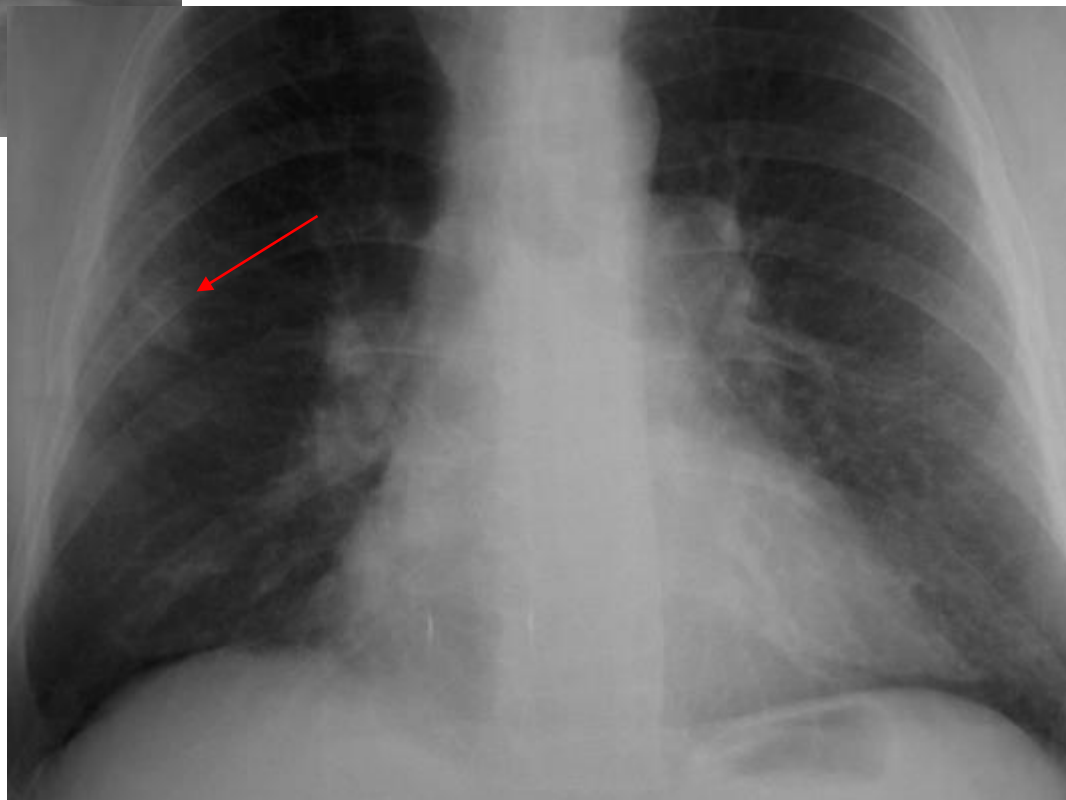

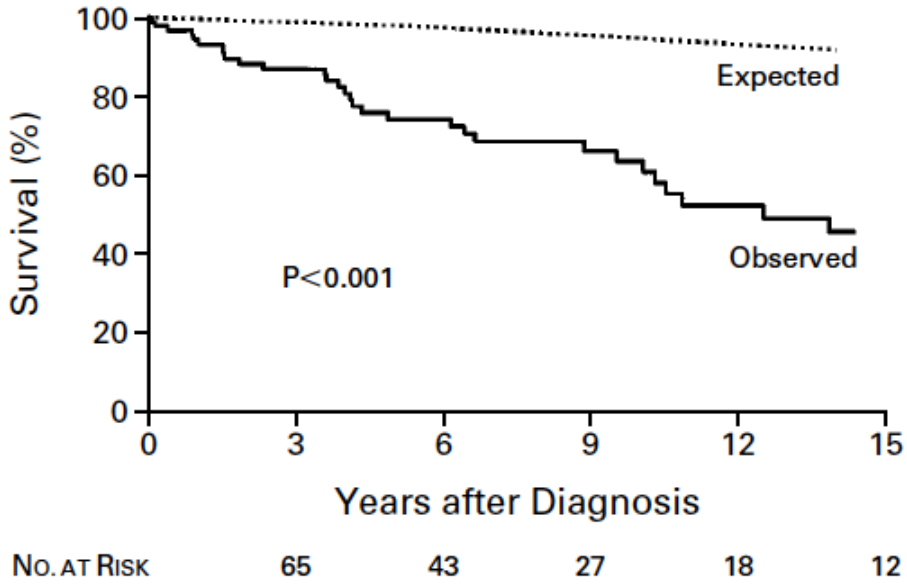

Vassallo et al. N Engl J Med 2002

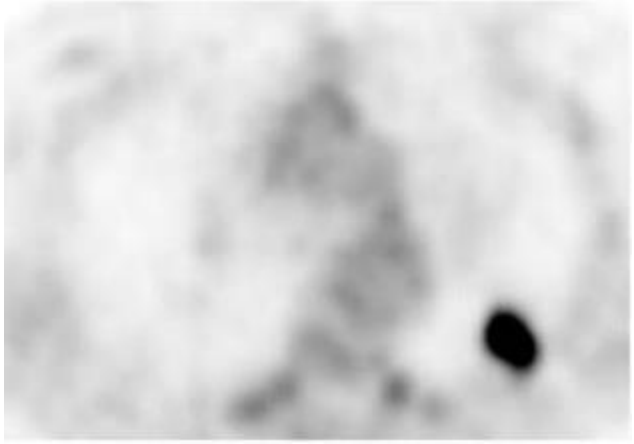

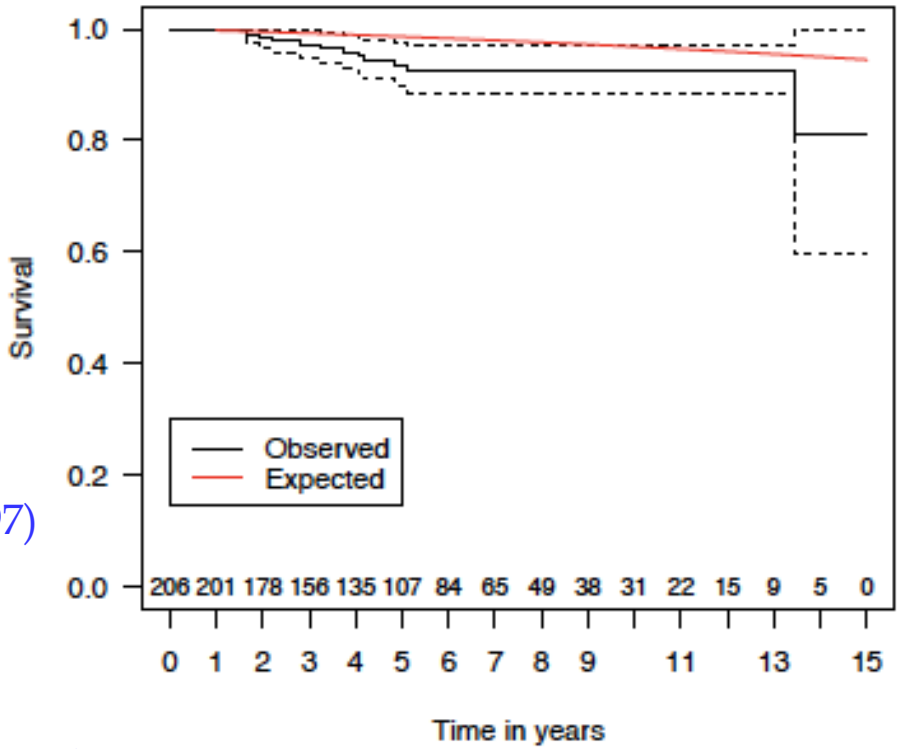

Probabilité de survie à 10 ans: 93%; 95%IC (89; 97)

SMR: 4.32; 95%IC (2.29; 8.17)

12 (6%) patients sont décédés durant l'étude, 6 (50%) avec IRC.

Benattia et al. en préparation

Traitement de l'HL pulmonaire

- Stabilisation ou régression spontanée fréquente
  - poussées
- Sevrage tabagique +++
  - diminue le risque de dégradation ultérieure de la fonction respiratoire
  - BPCO, pathologie cardiovasculaire, KBP
  - seule mesure chez 28/40 patients *(Elia et al. Eur J Intern Med 2015)*
  - programmes dédiés (prise en charge addictologique, psychologique)++ *(Bugnet et al. en révision)*
- *Essai de corticoïdes+β2 mimétique inhalés*
- Traitement spécifique du pneumothorax *(Le Guen et al. OJRD 2019)*
- Prévention et traitement précoce des infections respiratoires (vaccinations)
- *Corticothérapie orale :*
  - en pratique pas d'effet sur fonction respiratoire
- *Vinblastine peu ou pas efficace (Tazi et al. OJRD 2017)*
- Réhabilitation respiratoire, oxygénothérapie
- Parfois traitements anti-HTAP (centres experts) *(Le Pavec et al. Chest 2012)*
- Transplantation pulmonaire (rechutes) *(Dauriat et al. Transplantation 2006)*

Cladribine dans l'HLP

- 2-CDA: analogue des purines
- Toxique sur monocytes, lymphocytes, progéniteurs myéloïdes, et CD sanguines
- Très immunosuppresseur (lymphopénie prolongée)
- Traitement de 2ème ligne de HL systémique *(Neel et al. BJH. Sous presse)*
- Plusieurs cas rapportés
  - *Aerni et al. Respir Med 2008*
  - *Lazor et al. Thorax 2009*
  - *Lorillon et al. AJRCCM 2012*
  - *Grosbost et al. OJRD 2014*
  - *Epaud et al. ERJ 2015*
  - *Nasser et al. ERJ Open Res. 2018*

Cladribine Is Effective against Cystic Pulmonary Langerhans Cell Histiocytosis

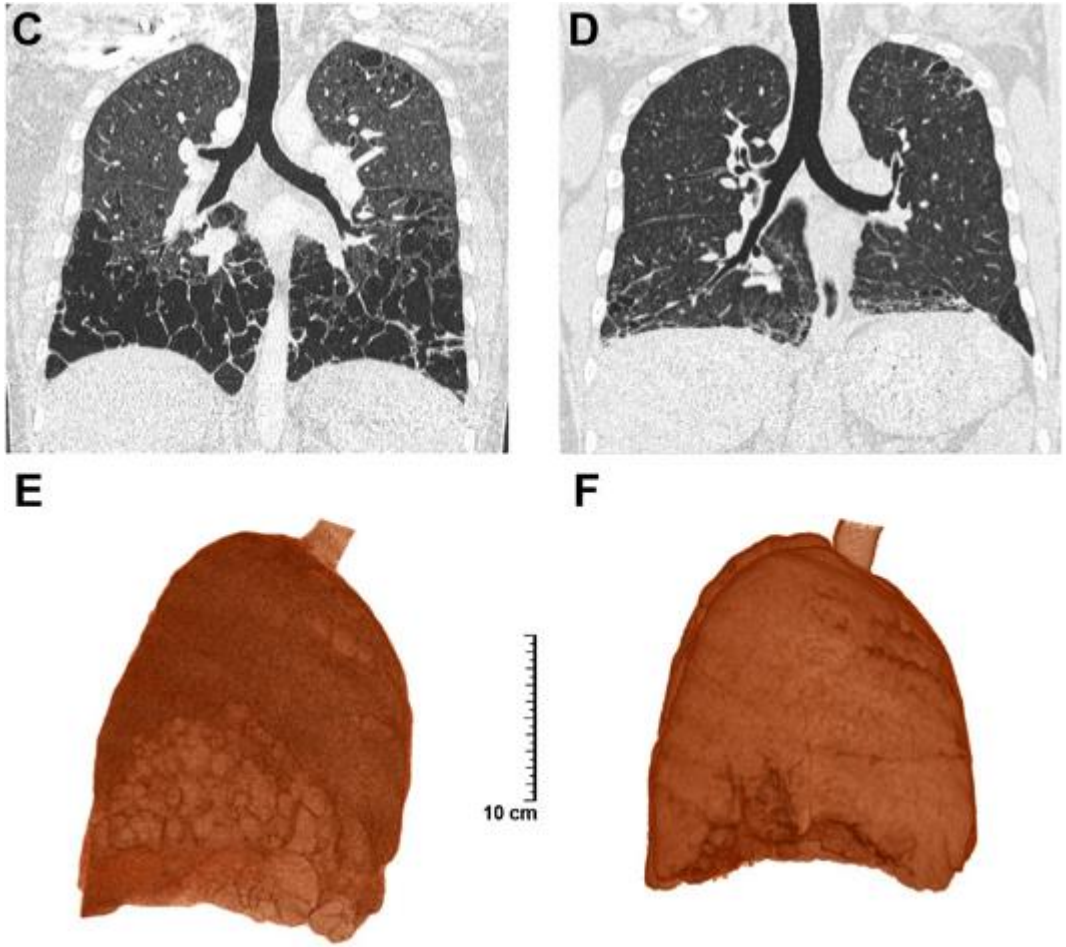

Lorillon et al. AJRCCM 2012

Avant traitement

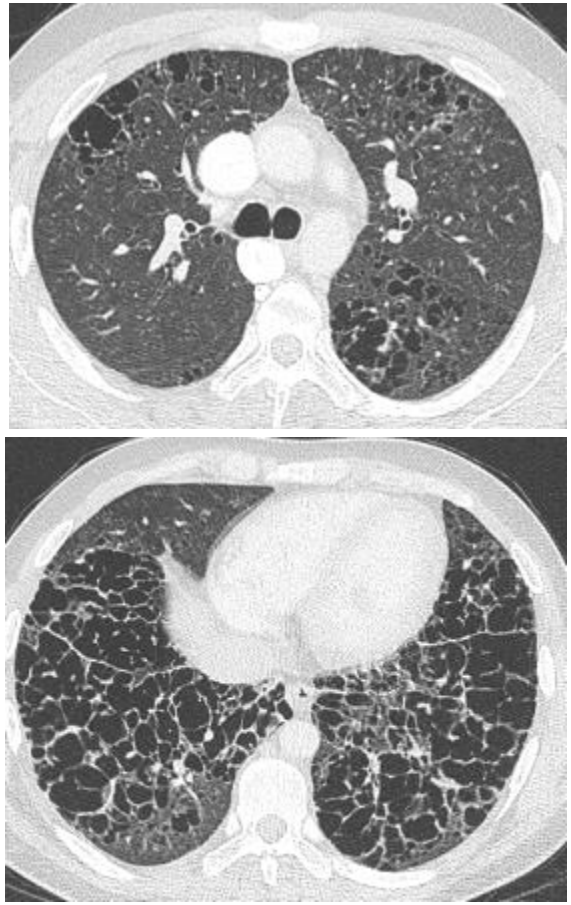

6 mois après traitement

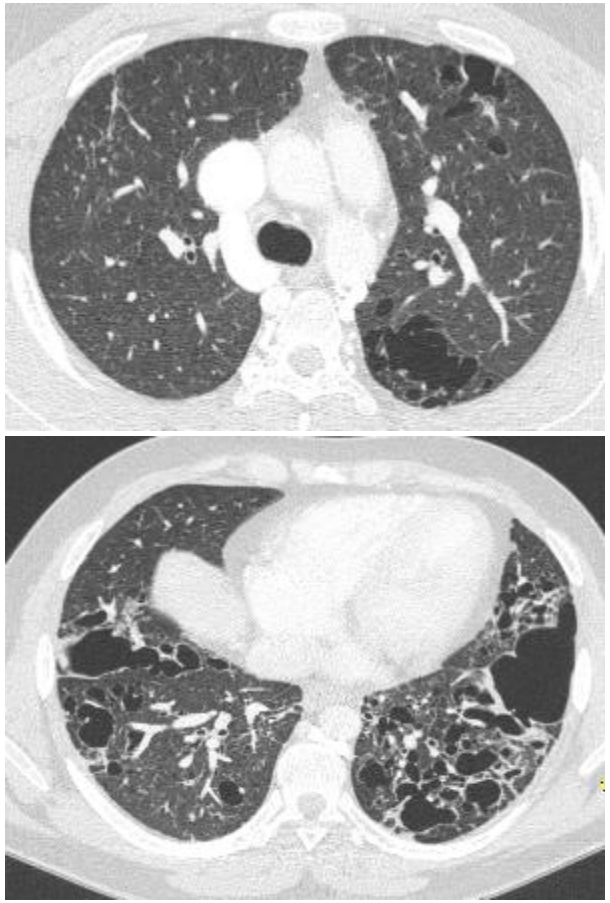

4 ans après traitement

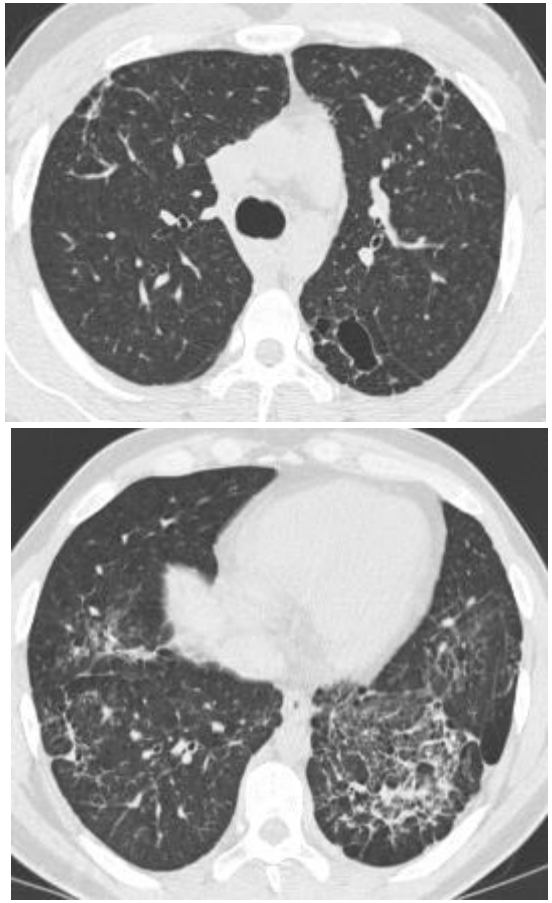

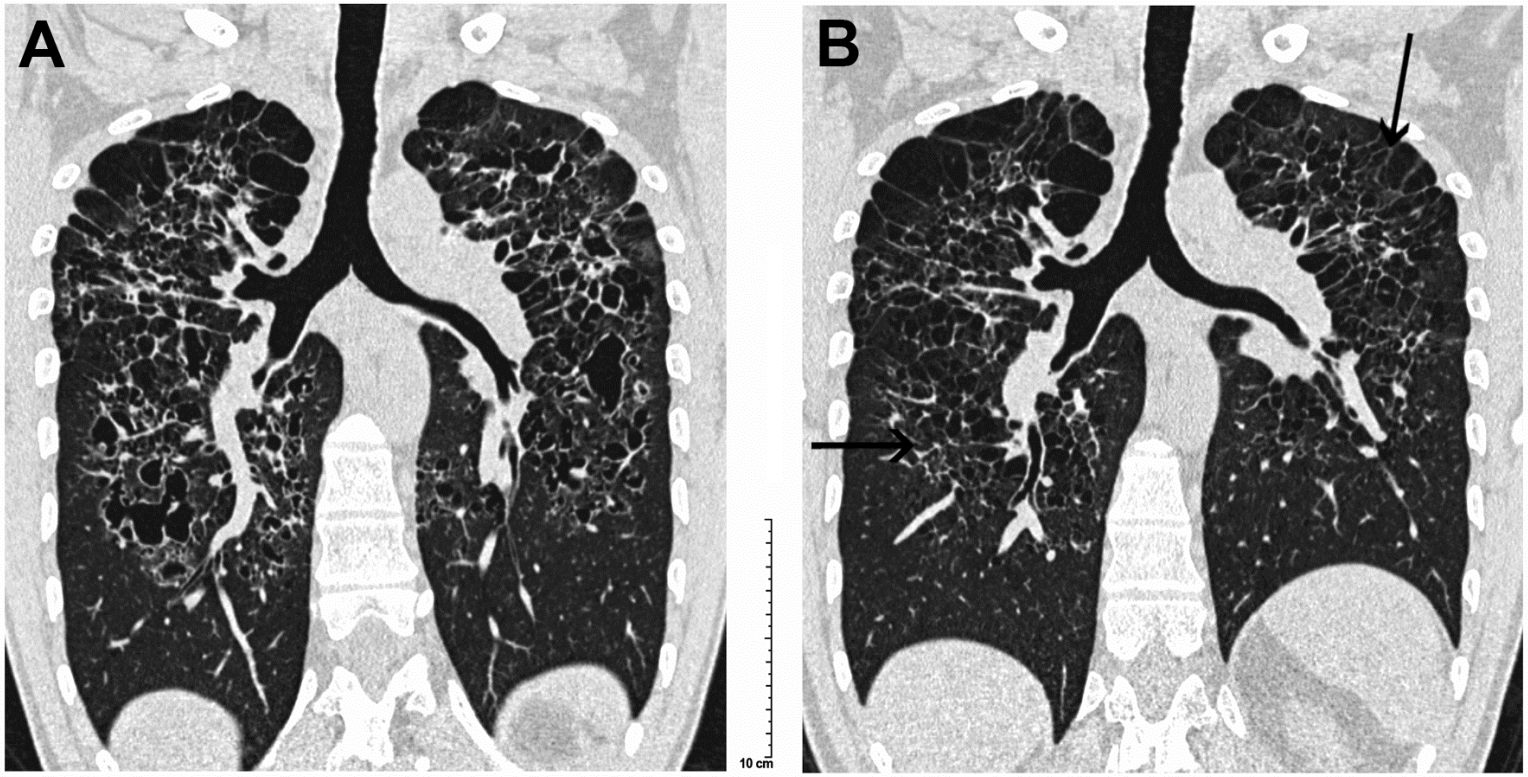
A
B
10 cm

	Patient 1				Patient 2				Patient 3			
PFTs	M0	M6	M12	M48	M0	M6	M21*	M48	M0	M6	M16	M-48
TLC	6360	6800	7130		7240	6810	7260	7820	5000	4170	4980	4940
%	73	78	83		93	88	93	100	80	67	79	78
VC	3830	4320	4700		4610	3920	3850	3380	3060	2660	3030	3450
%	57	65	71		80	69	68	60	63	55	63	72
RV	2520	2470	2430		2630	2890	3530	4440	1930	1510	1950	1520
%	133	130	126		134	146	181	217	128	100	129	97
FEV_1	2520	3090	2940	3000	3790	2700	2470	2180	1840	2300	2550	3030
%	42	53	51		78	56	52	46	46	57	63	78
FEV_1/VC	66	72	63		82	67	64	58	73	86	84	88
DL_{CO} %	22	23	26		24	35	35	35	53	53	45	61

*2 cycles supplémentaires de cladribine

ECLA study NCT01473797

H&E

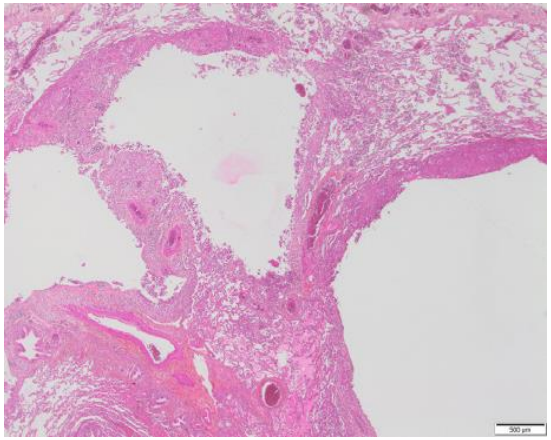

H&E

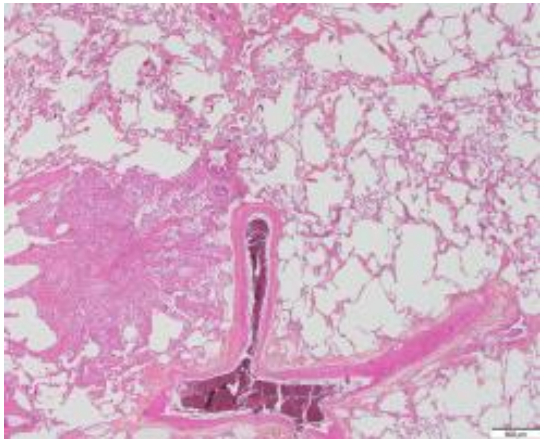

CD1a

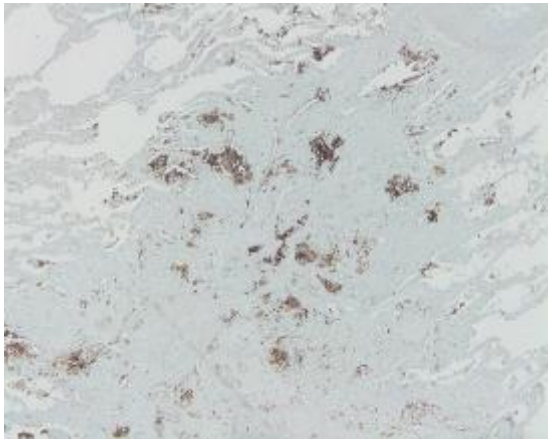

Table 4. Lung function outcome of treated LCH patients with lung involvement compared to PET-CT findings.

Patient	HRCT pattern Nodular/cystic (score)	PFTs*	PET-CT n°1 ^{18}F-FDG uptake	Treatment	PFT outcomes**	PET-CT n°2 ^{18}F-FDG uptake	Treatment	PFT outcomes	PET-CT n°3 ^{18}F-FDG uptake
1	Thin-walled cysts (0,4)	Normal	No	Prednisone Vinblastine	Normal	No	Cladribine	Normal	No
3	Thick- and thin-walled cysts (3,22)	FVC 57% FEV_1 44% DL_{CO} 40%	No	No	Stable	No	Cladribine	Stable	No
6	Thick- and thin-walled cysts (6,19)	DL_{CO} 48%	No	Cladribine	Improved	No	NA	NA	NA
7	Thick- and thin-walled cysts (0,24)	FVC 47% FEV_1 33% DL_{CO} 43%	No	Prednisone Vinblastine	Deteriorated	No	Cladribine	Improved	No
12	Thick-walled cysts (0,14)	FVC 52% FEV_1 40% DL_{CO} 22%	Yes	Cladribine	Improved	No	No	Stable	No

Obert et al. Eur J Nucl Med Mol Imaging 2017

Pathogénie de l'HL

- Accumulation de cellules CD1a+ (langerine+) : recrutement
- Résistance à l'apoptose, sénescence
- Degrés variables d'activation des cellules
- Microenvironnement inflammatoire++
- Destruction paroi bronchiolaire
  - effets direct, MMP…?
- Rôle du tabac
  - recrutement de cellules dendritiques vers le poumon
  - "trigger"
- Néoplasie myéloïde de gravité variable
  - Mutations BRAF et activation voie MAPK

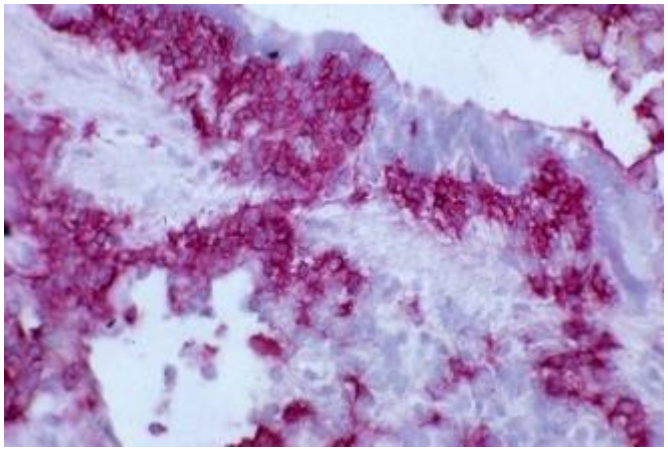

Recurrent *BRAF* mutations in Langerhans cell histiocytosis *Blood 2010*

Gayane Badalian-Very,[1-3] Jo-Anne Vergilio,[4,5] Barbara A. Degar,[6-8] Laura E. MacConaill,[9] Barbara Brandner,[1-3] Monica L. Calicchio,[4] Frank C. Kuo,[5,10] Azra H. Ligon,[5,10,11] Kristen E. Stevenson,[12] Sarah M. Kehoe,[9] Levi A. Garraway,[1-3,9,13] William C. Hahn,[1-3,9,13] Matthew Meyerson,[1,2,9,13] Mark D. Fleming,[4,5] and Barrett J. Rollins[1-3]

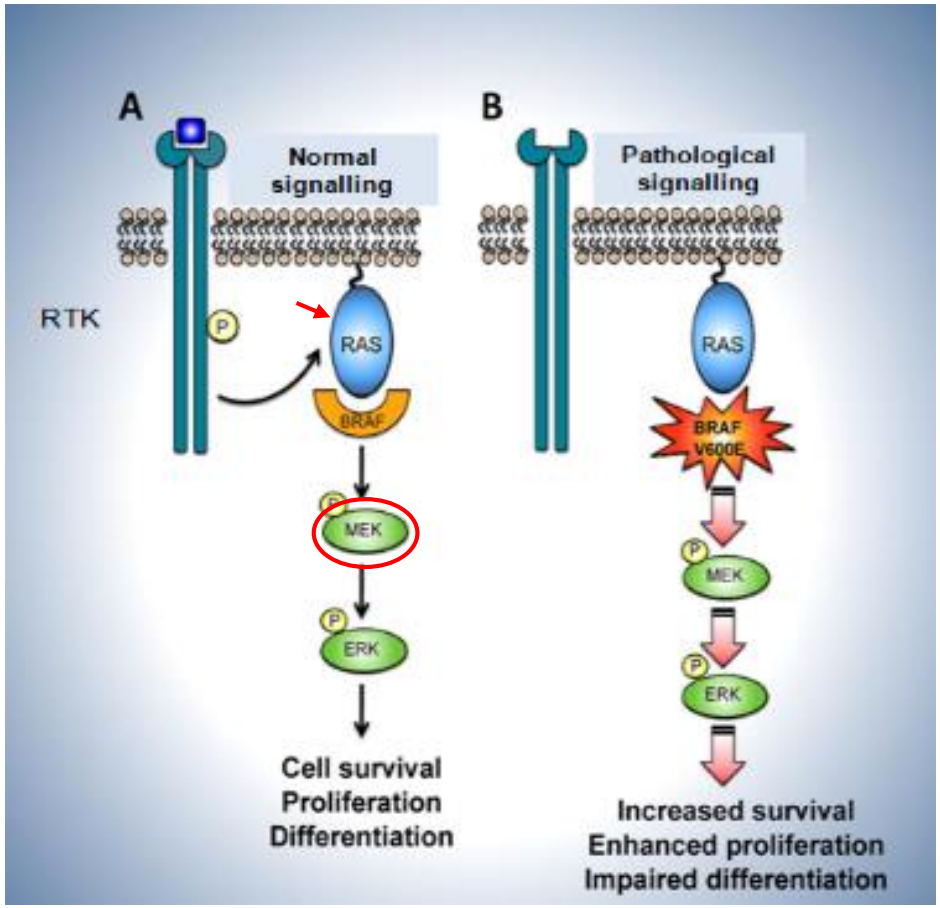

Nichols KE and Arceci RJ Blood 2010

p-MEK

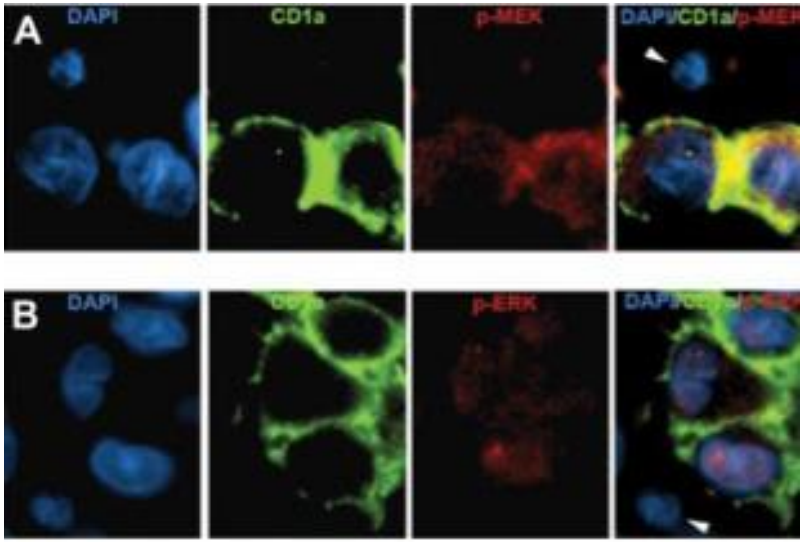

p-ERK

Brown et al. Blood 2014
Chakraborty et al. Blood 2014
Mourah et al. ERJ 2016

MAPK status of adult PLCH lesions

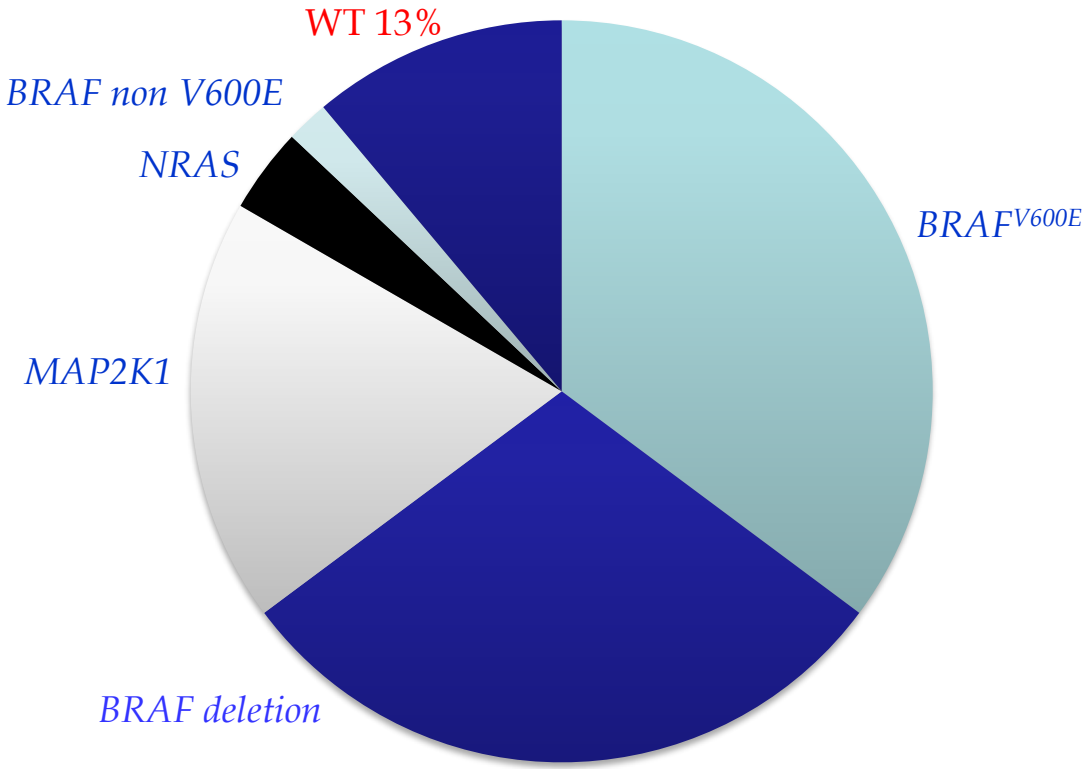

Jouenne et al. ERJ 2019

Traitements ciblés dans l'HL

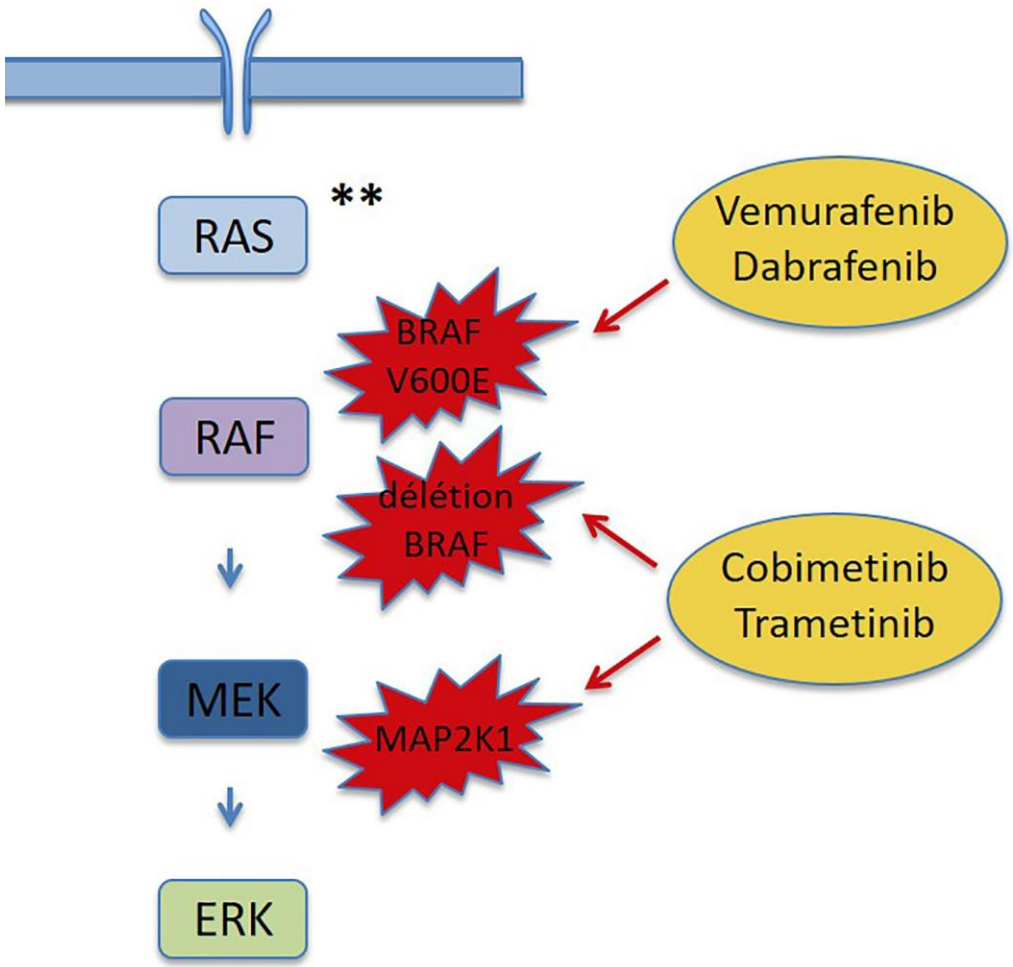

Response to Trametinib of a Pulmonary Langerhans cell Histiocytosis Harboring a MAP2K1 deletion

Lorillon et al. AJRCCM 2018

cladribine

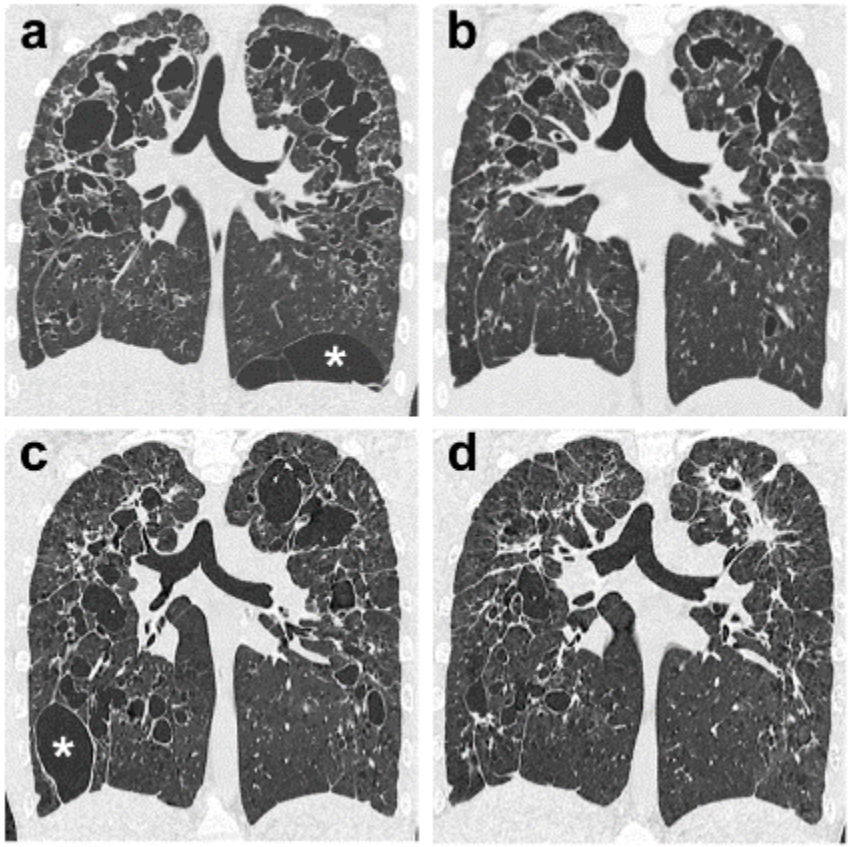

trametinib

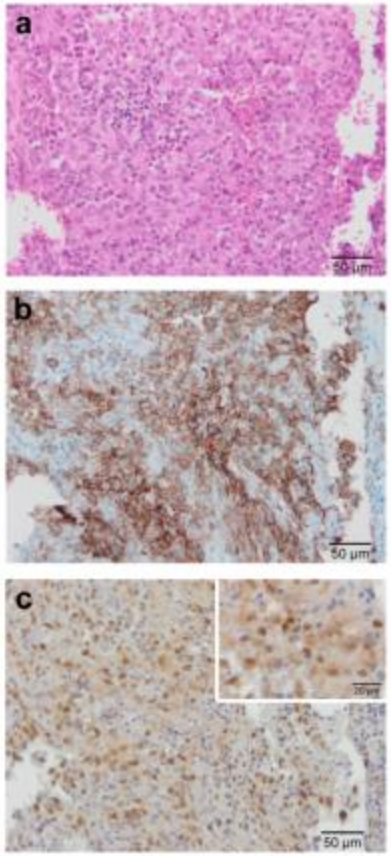

HES

CD1a

p-ERK

Lung Cysts, Spontaneous Pneumothorax, and Genetic Associations in 89 Families with Birt-Hogg-Dubé Syndrome *Toro et al. AJRCCM 2007*

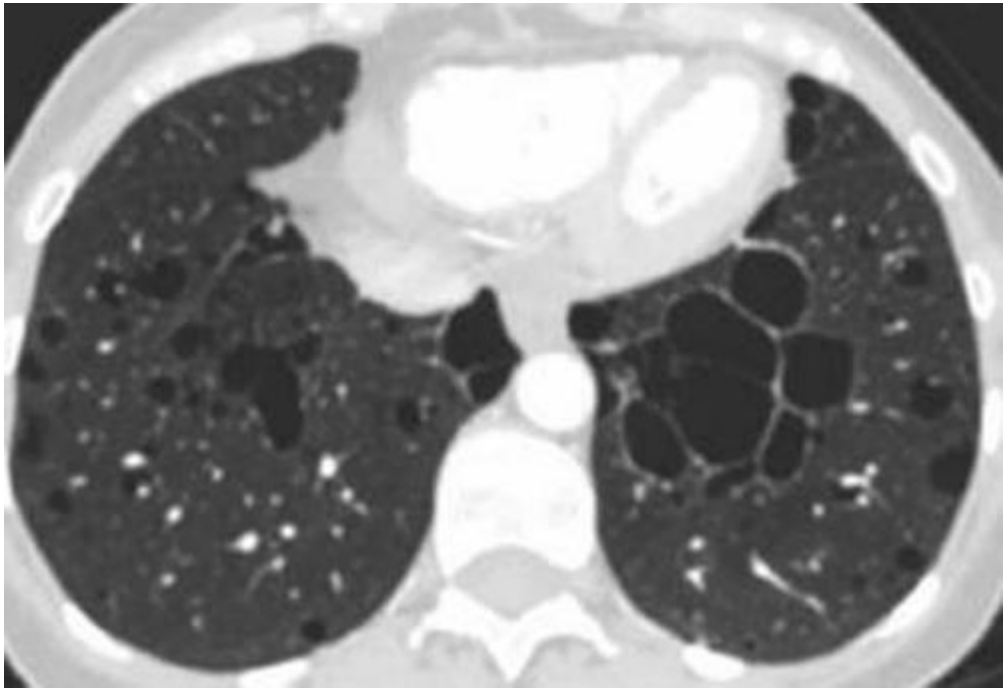

- génodermatose
- autosomique dominante
- lésions cutanées (fibrofolliculomes)
- tumeurs rénales (autres)
- kystes pulmonaires, pneumothorax
- mutation du gène de la folliculine

Enquête familiale++

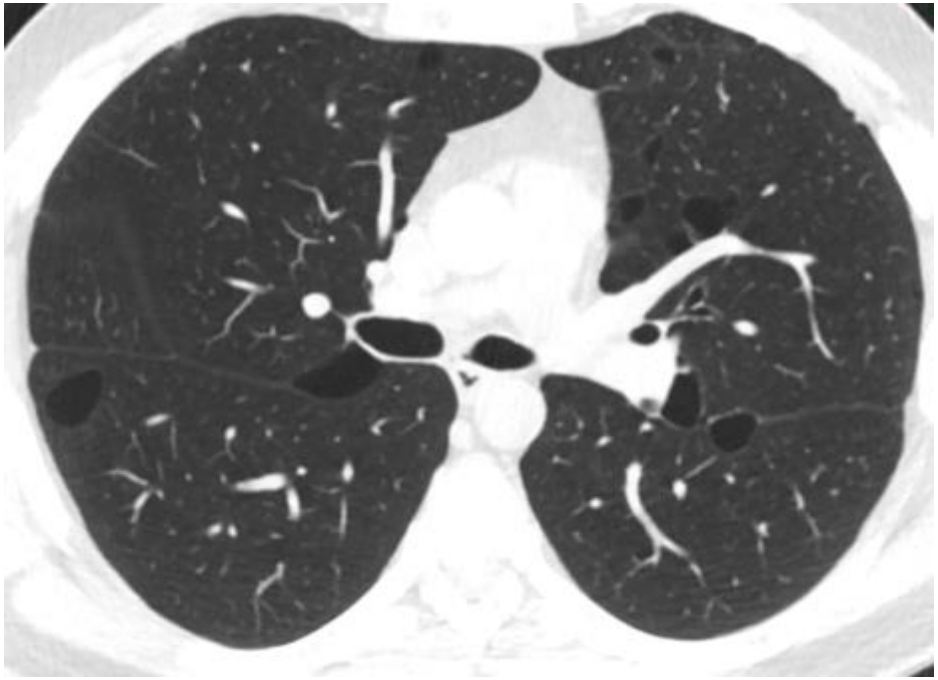

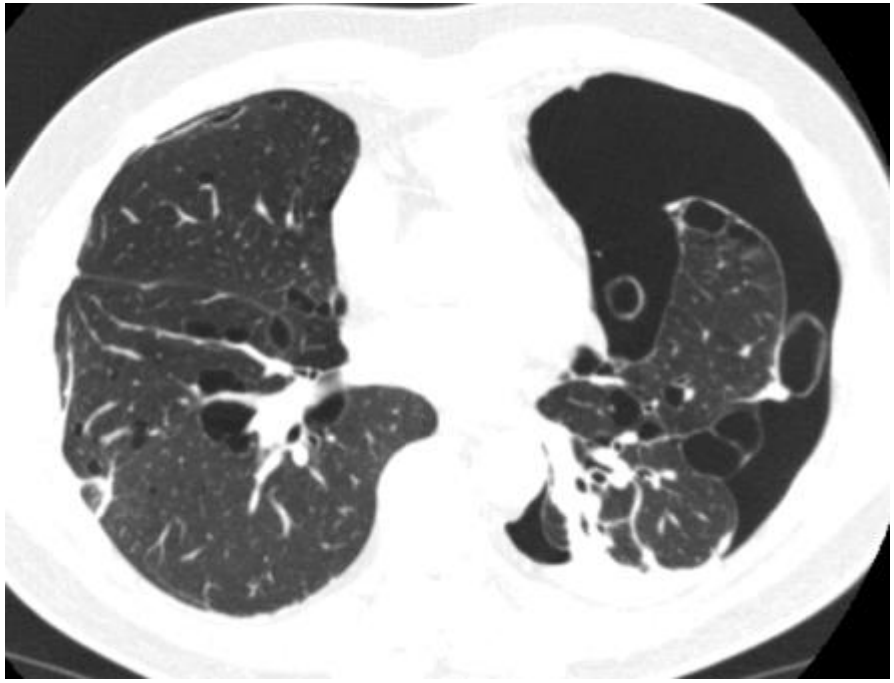

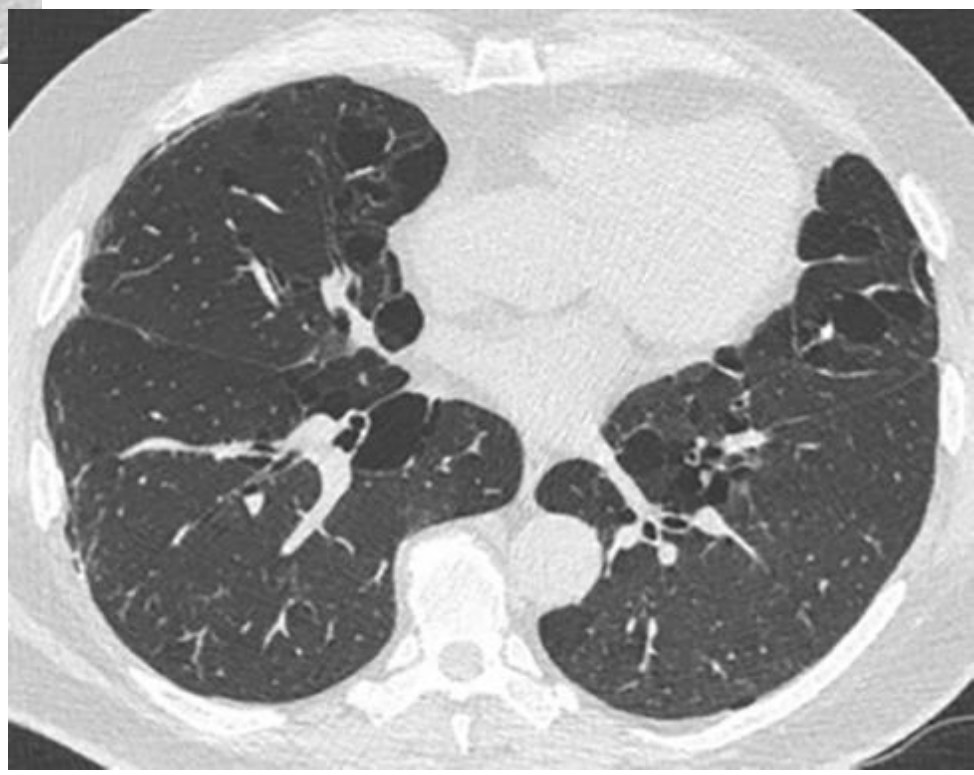

Pulmonary Cystic Disorder Related to Light Chain Deposition Disease

Colombat et al. AJRCCM 2006

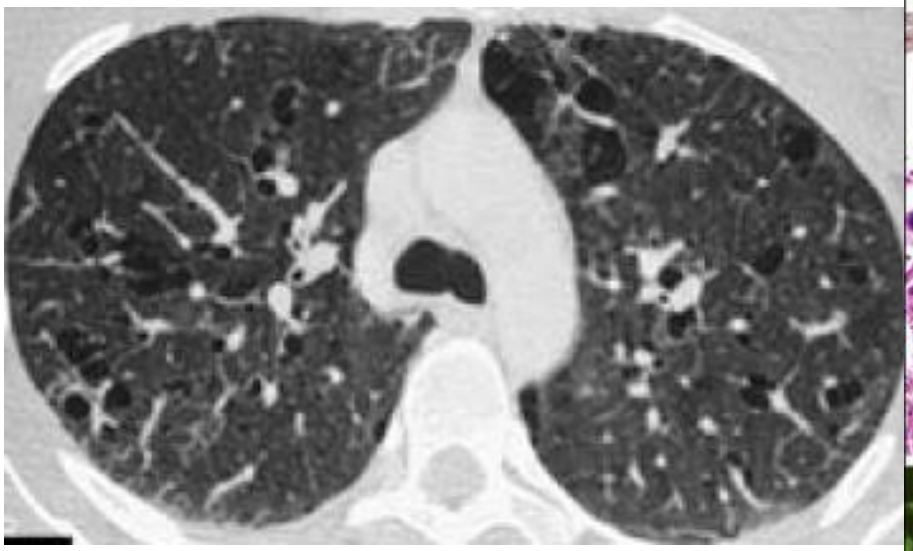

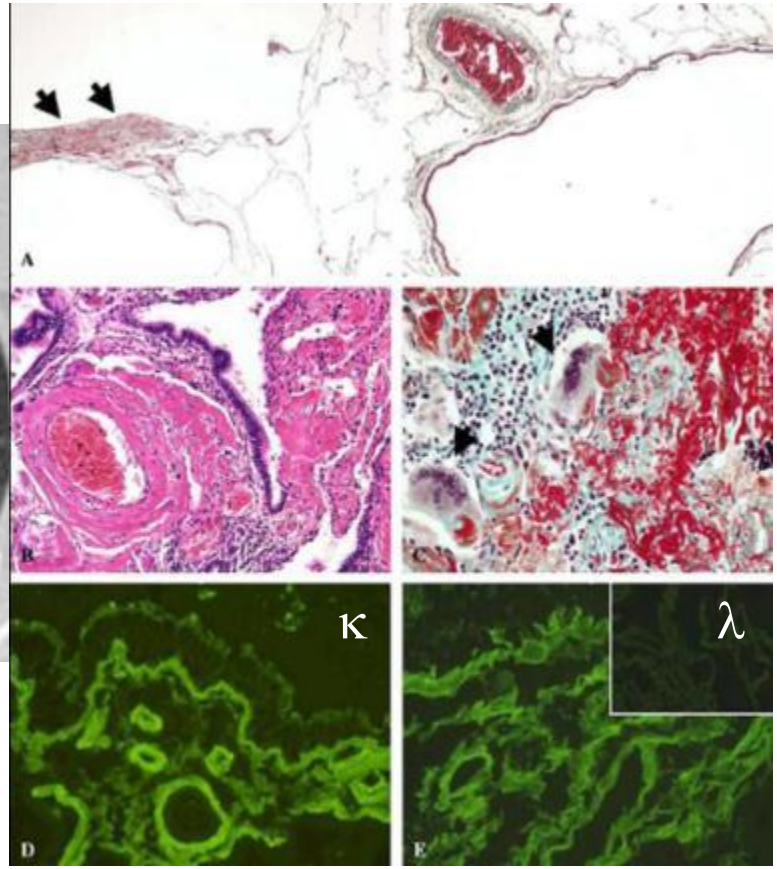

Primary cystic lung light chain deposition disease: a clinicopathologic entity derived from unmutated B cells with a stereotyped IGHV4-34/IGKV1 receptor

Colombat et al. Blood 2008

Sjögren + LIP kystique pure

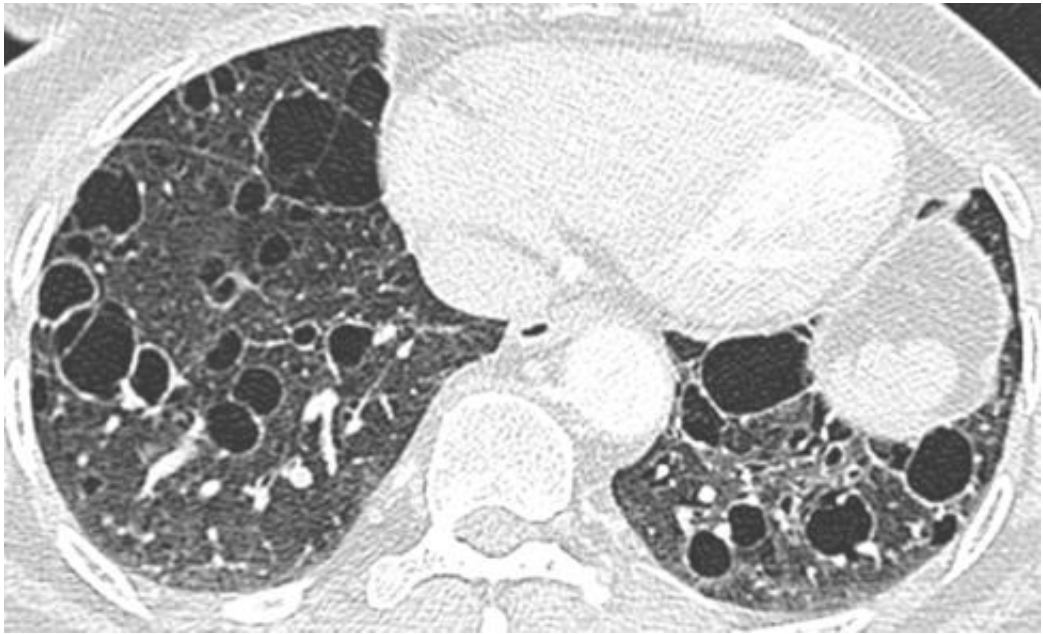

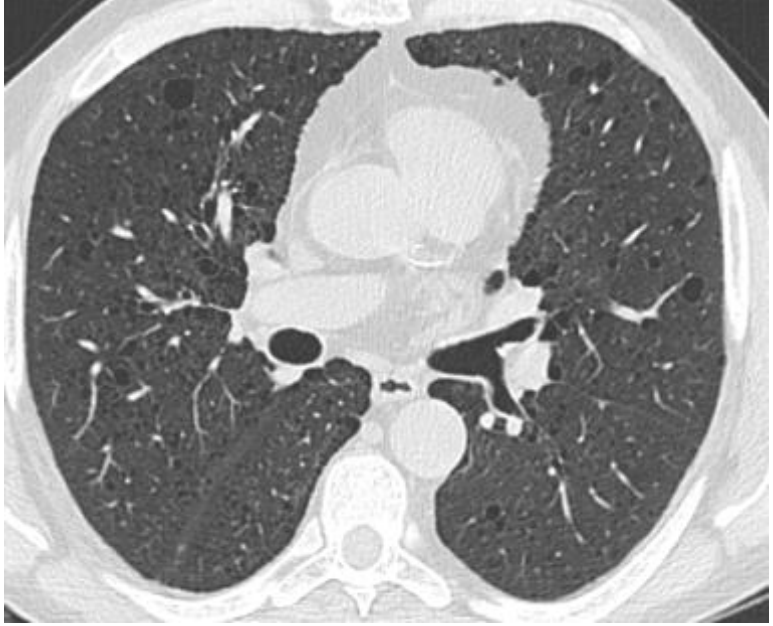

Neurofibromatose

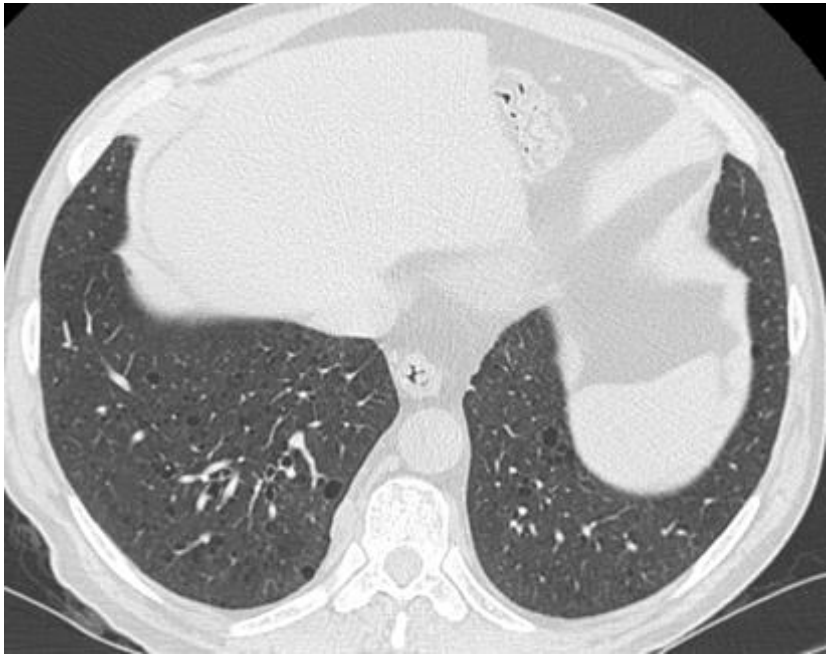

Pathologie Pulmonaire Kystique Diffuse
Approche diagnostique en pratique (1)

- Sexe
- Age
- Tabagisme
- Famille
  - STB
  - BHD
- Signes généraux: attention aux infections (PCJ)
- Signes radiologiques thoraciques associés
  - nodules, cavités (verre dépoli, épaississements septaux…)
  - pleurésie, atteinte costale
- Imagerie antérieure et séquence évolutive
  - nodules → cavités précédant les kystes
  - inverse?

Pathologie Pulmonaire Kystique Diffuse
Approche diagnostique en pratique (2)

- Anomalies extra-thoraciques
  - Rein
    - LAM++/STB
    - BHD
  - Lymphangioléiomyomes, ggs abdominaux
    - LAM/STB
  - Peau
    - STB
    - HL
    - BHD
    - Rarement sarcome, NF…
  - Os
    - HL++
    - (tumeurs malignes)
  - Hypophyse
    - Diabète insipide: HL

TDM/IRM abdomen pelvis

- Pathologie associée connue++

Pathologie Pulmonaire Kystique Diffuse
Approche diagnostique en pratique (3)

- Biologie
  - Lymphocytes sanguins
  - EPP; immunofixation; (dosage chaînes légères)
  - Urines: EP, immunofixation
  - VEGF-D
  - (α1 AT)

- Fibroscopie bronchique
  - Biopsie de lésion
  - B. transbronchiques (risque PNO)
  - Si LBA
    - ✓ alvéolite macrophagique (tabac) ou non

- Génétique
  - Folliculine
  - Mutations TCS2/TCS1

Pathologie Pulmonaire Kystique Diffuse
Biopsie pulmonaire chirurgicale

- Absence d'argument indirect pour diagnostic
- Risque, degré d'altération de la fonction respiratoire
- Conséquences sur la prise en charge
- Quand réalisée:
  - Etude exhaustive du prélèvement
  - Coloration spéciales
    - Rouge congo si dépôts
    - (PAS-Grocott)
  - Immunohistochimie
    - HMB-45 (actine, cathepsine K, ER, ..)
    - CD1a, mutations
    - Chaînes légères κ/λ
  - Fragment dans glutaraldéhyde (μe)
  - Congélation++

Bibliographie

- *Gupta et al. Diffuse cystic lung disease Part 1 & 2. AJRCCM 2015*
- *Raoof et al. Cystic lung diseases. Algorithmic approach. Chest 2016*
- *Johnson SR et al. Lymphangioleiomyomatosis. Clin. Chest Med. 2016*
- *Vassallo R, Harari S, Tazi A. Current understanding and management of pulmonary Langerhans cell histiocytosis. Thorax 2017*
- *Gupta N, Sunwoo BY, Kotloff RM. Birt-Hogg-Dubé Syndrome. Clin. Chest Med. 2016*
- *Khawaja A, Arrossi AV, Kotloff RM. Shedding light on cystic lung diseases. Annals ATS 2019*