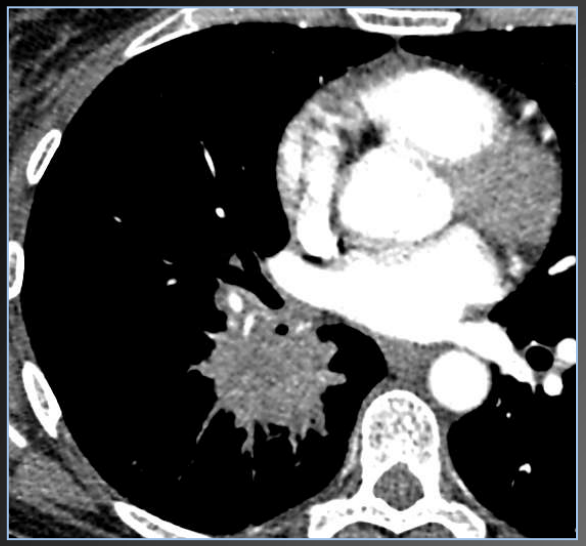

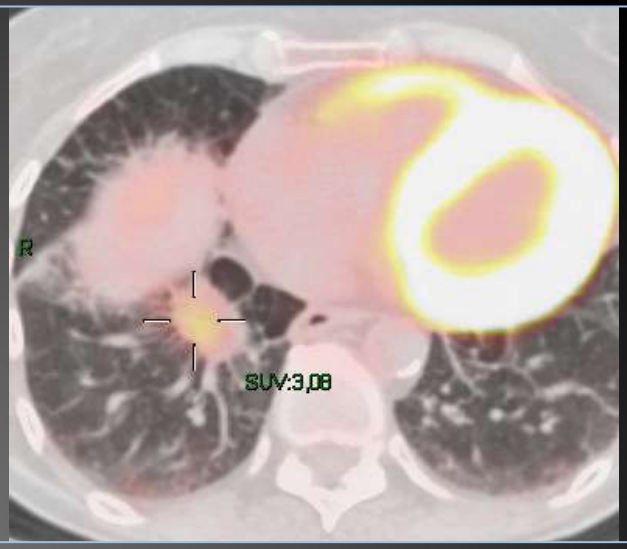

Les pièges de l'imagerie thoracique dans la prise en charge des cancers du poumon

Marie-pierre REVEL
Hôpital Cochin

PIEGES

- CARACTERISATION TUMORALE
- STAGING INITIAL
- EVALUATION DE LA REPONSE THERAPEUTIQUE
- SUIVI SOUS TRAITEMENT

CARACTERISATION TUMORALE

- Fausses images tumorales, faux positifs de TEP
  - Pneumopathies lipidiques de forme pseudo tumorales
  - Atélectasies par enroulement
- Formes pseudo pneumoniques
  - Adénocarcinomes mucineux

Image spiculée du lobe moyen

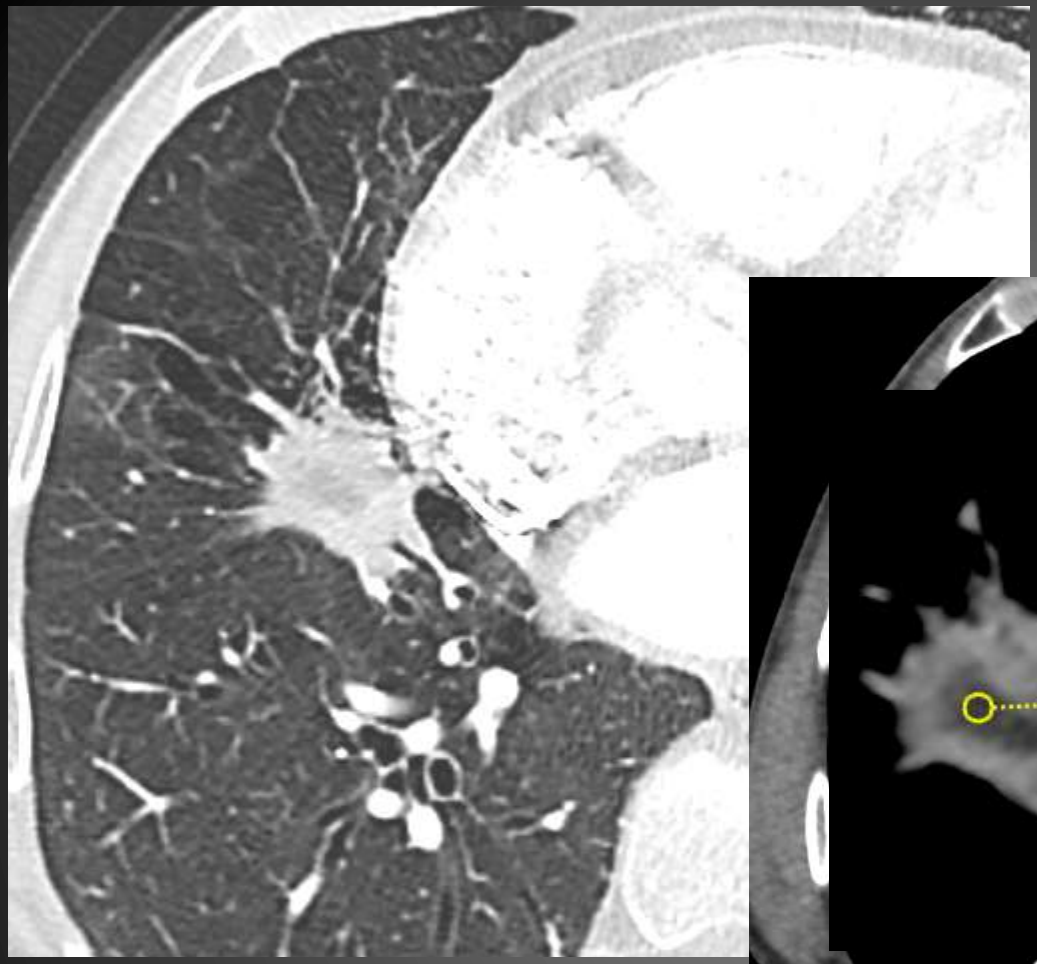

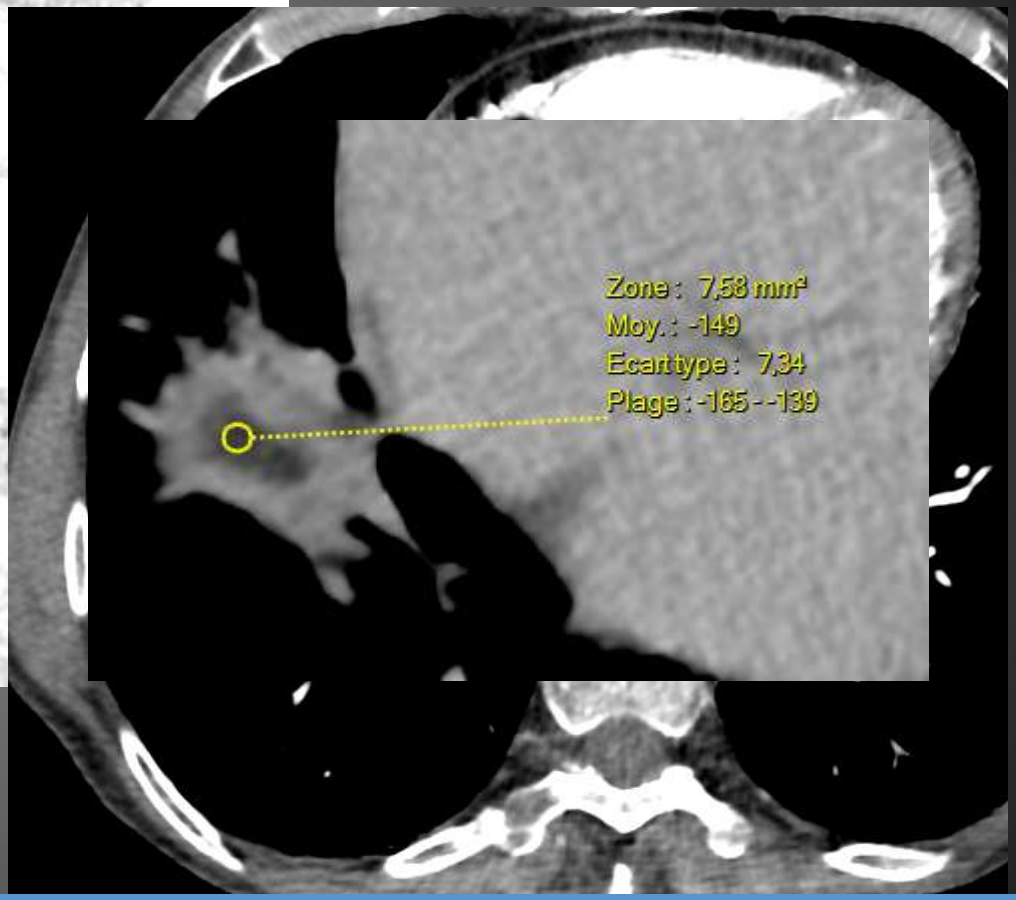

Elément sémiologique clé: Hypoatténuation graisseuse centrale
(à ne pas confondre avec une hypoatténuation liquidienne de nécrose centro tumorale)

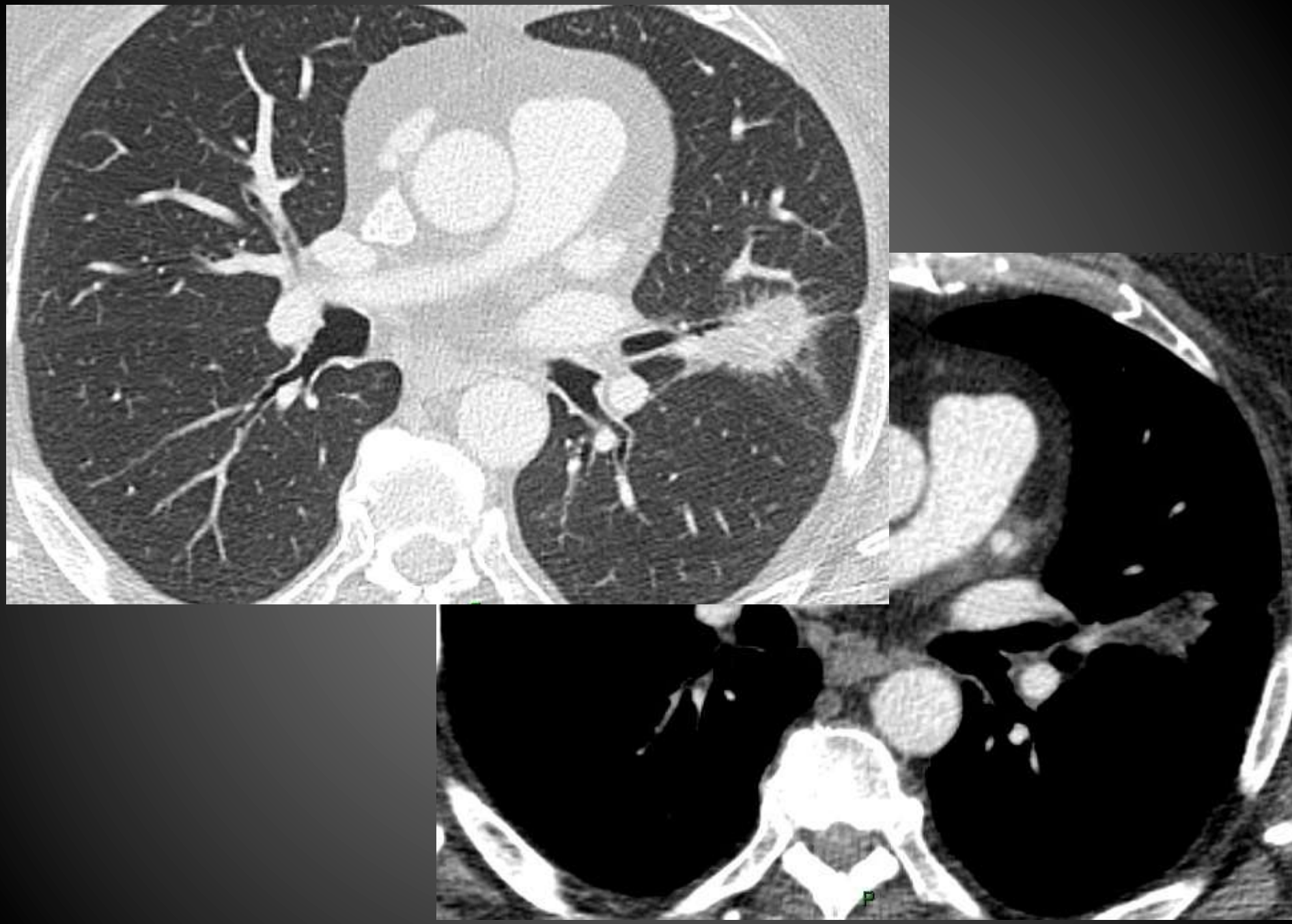
P

18FDG PET-CT
can produce false positives in tumor-like lesions

Increased metabolic activity on 18FDG PET has

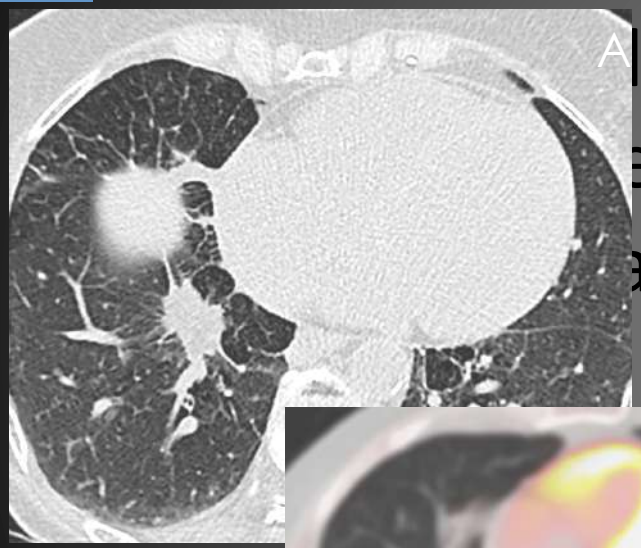

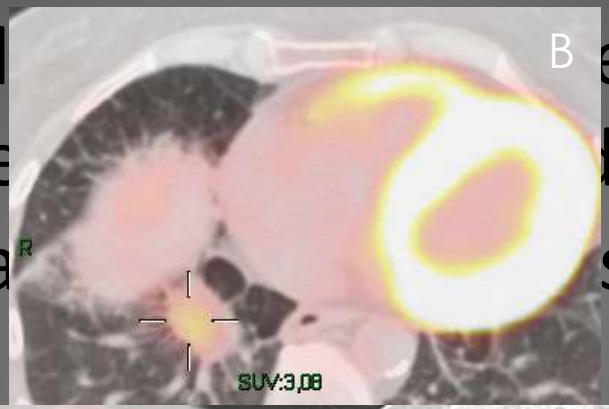

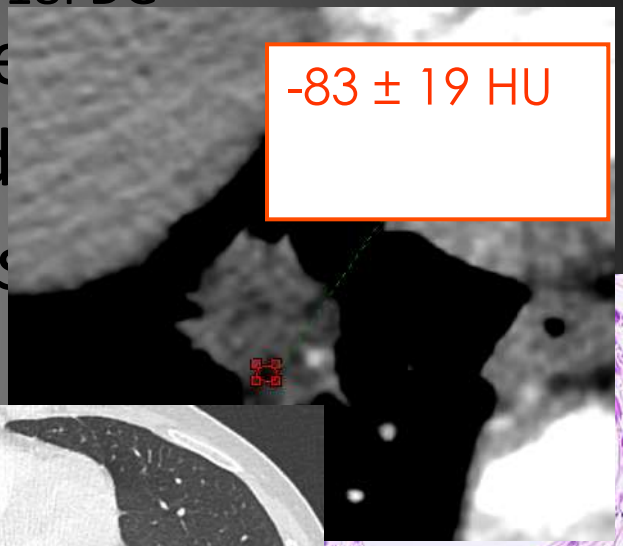

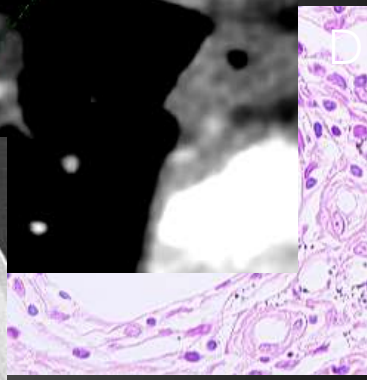

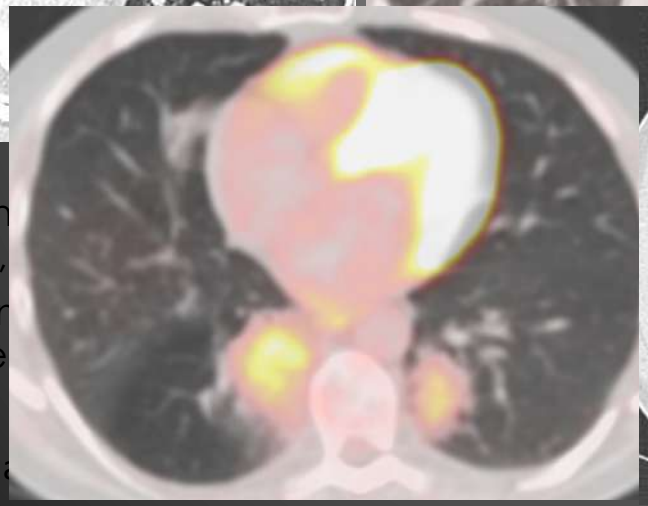

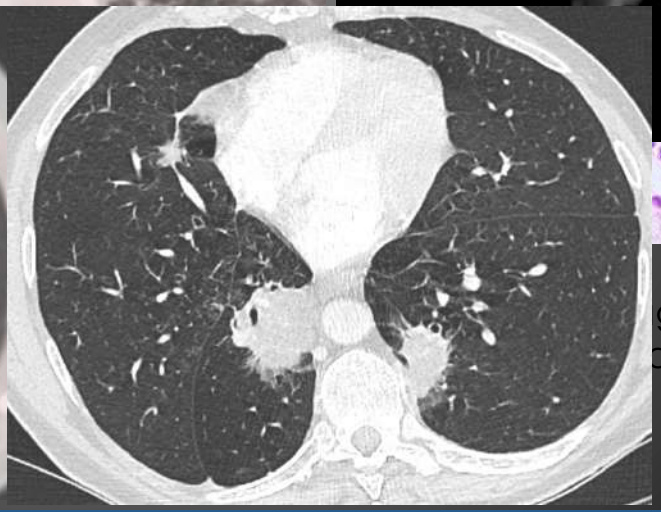

Spiculated lun
On PET-CT (B),

Microscopic in
showing large
lymphocytes

gnosis, by
and

Fat attenuation

Mokhlesi B et al V. False-positive FDG-PET scan secondary to lipoid pneumonia mimicking a solid pulmonary nodule. *Ann Nucl Med* 2007

Formes pseudo pneumoniques

- *Patiente de 82 ans*
- *Toux avec expectoration claire, non améliorée par les antitussifs et mucolytiques*

- *Changement de médecin traitant: radio de thorax*

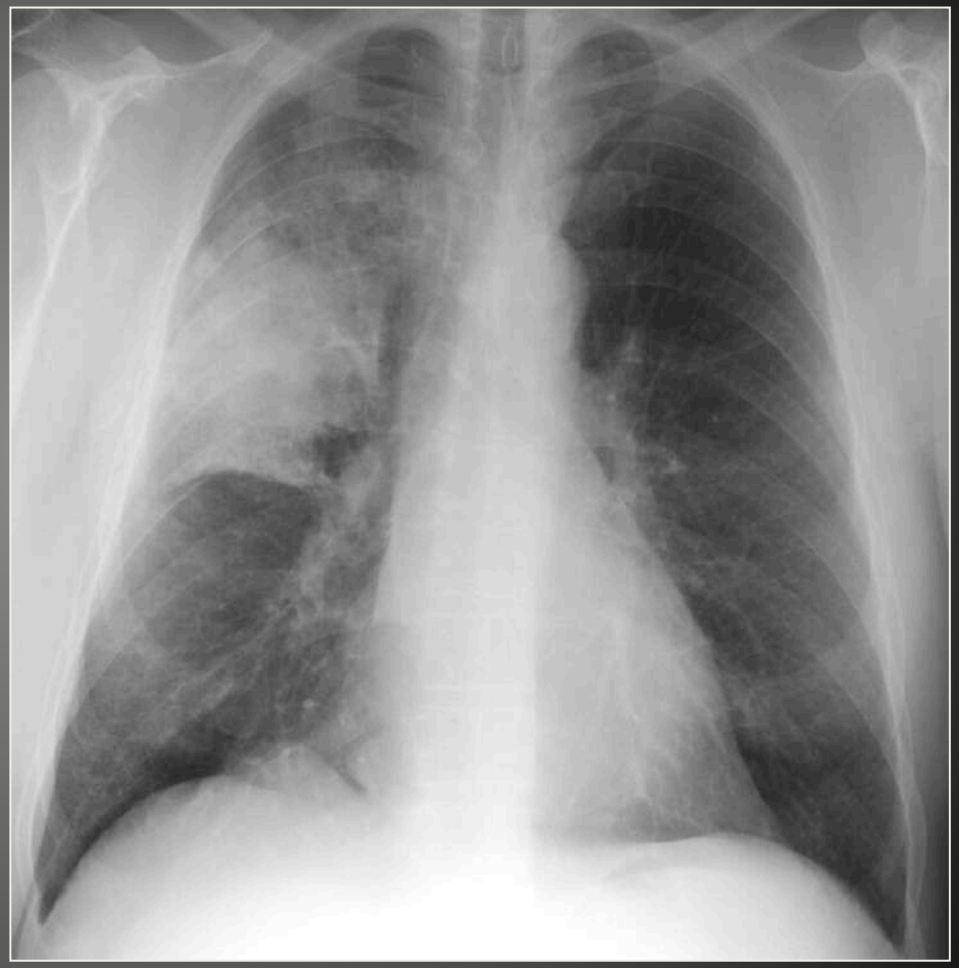

- *Autre patient*

Formes mucineuses

Comblement des lumières alvéolaires par le mucus =
aspects pneumoniques

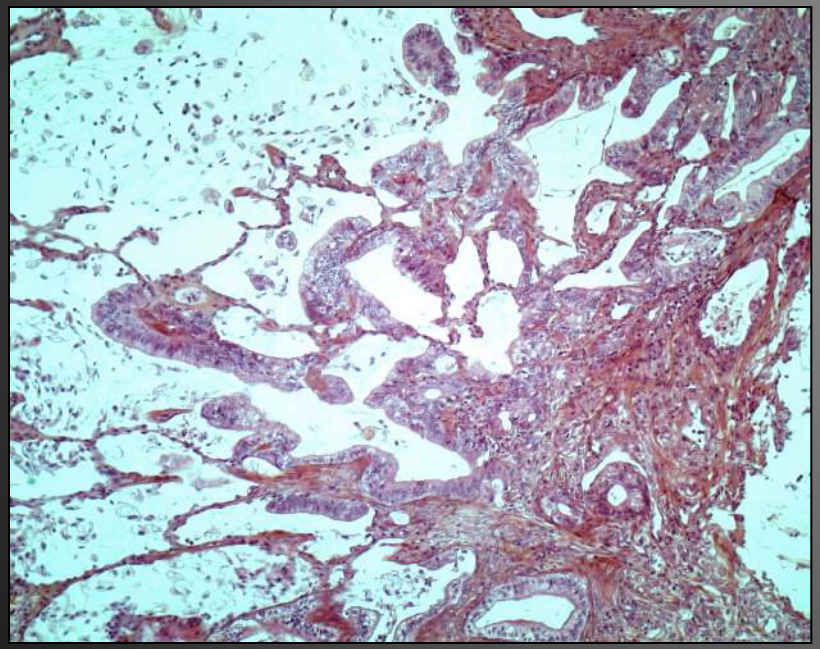

Desquamation cellulaire, propagation par voie aérienne

STAGING INITIAL

- Sous estimation du stade
  - Rare si on réalise PET et imagerie cérébrale
    - Imagerie cérébrale: injecter +++
  - Problématique des petits nodules parenchymateux pulmonaires: reste difficile
- Surestimation
  - Faux positifs du TEP
  - Ne jamais contre indiquer sans preuve histologique (cerveau exclu)

Adénocarcinome lobaire inférieur droit

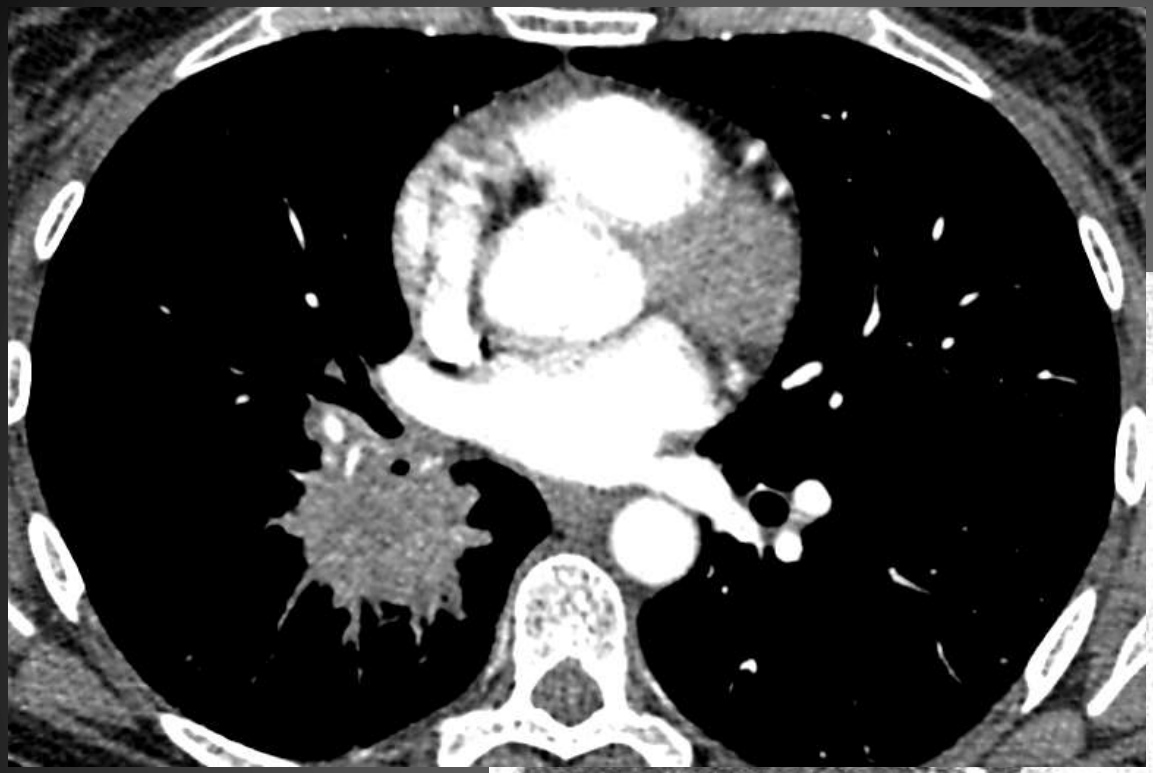

NODULE LIG?

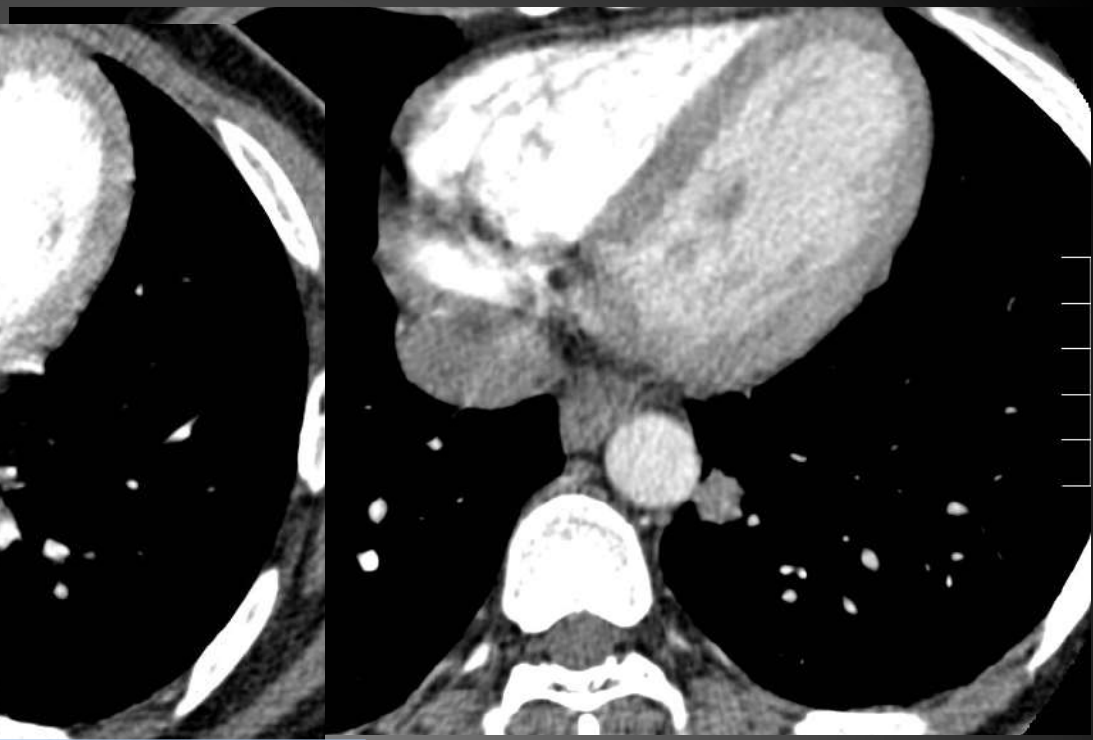

Adénocarcinome lobaire inférieur gauche

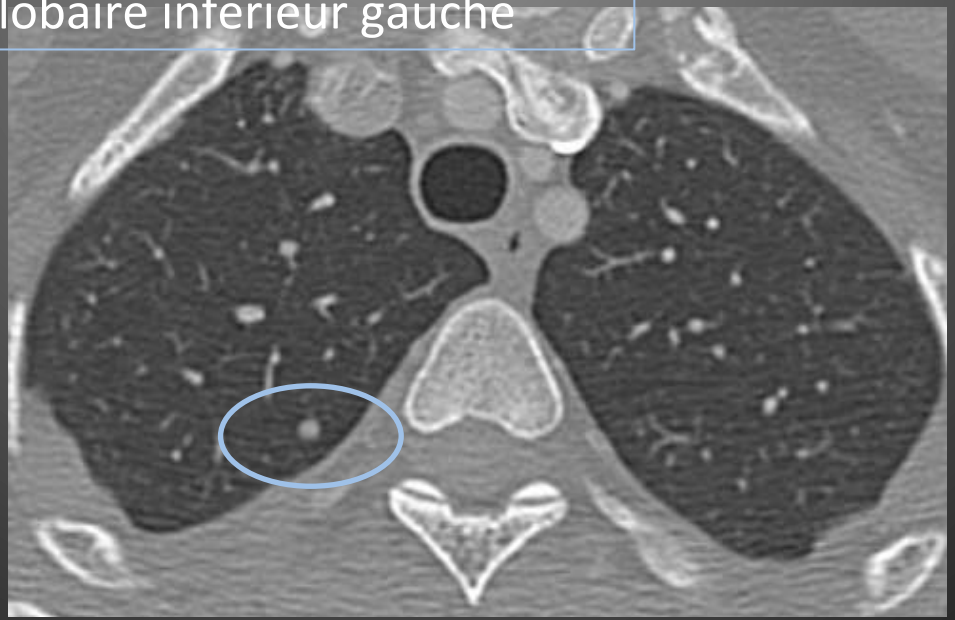

NODULE LSD?

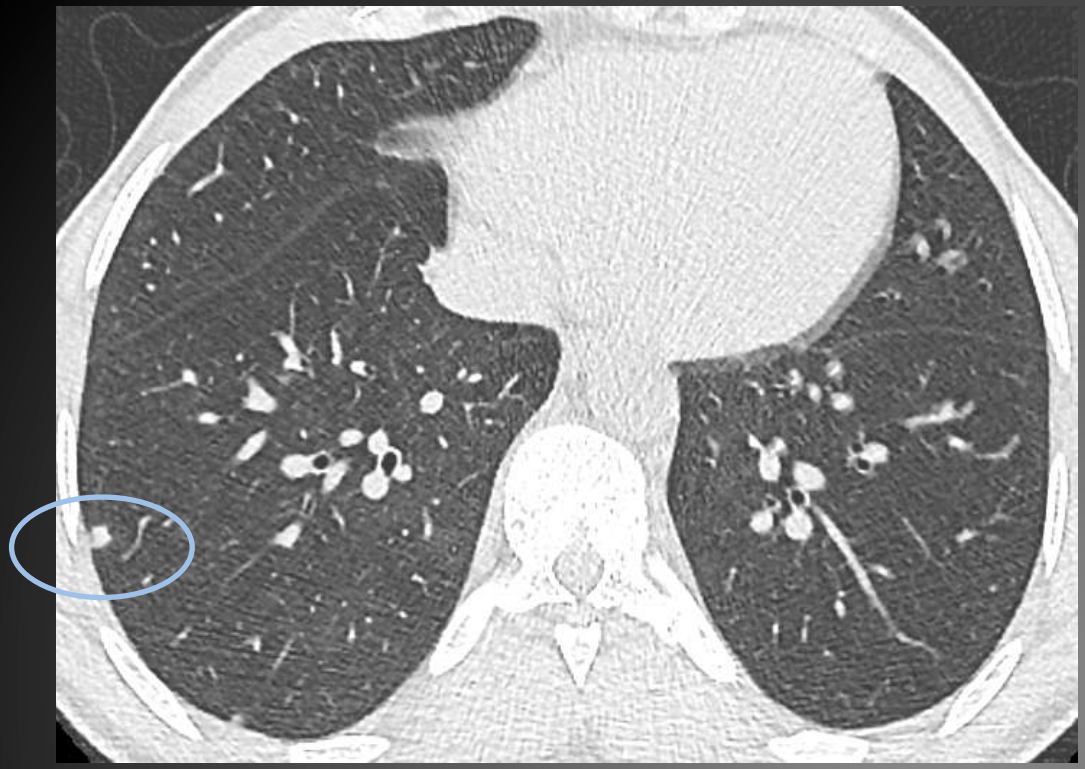

NODULE LID?

Tumeur de vessie

- Patient présentant une lésion spiculée avec épanchement pleural du coté gauche et un nodule dans le lobe moyen

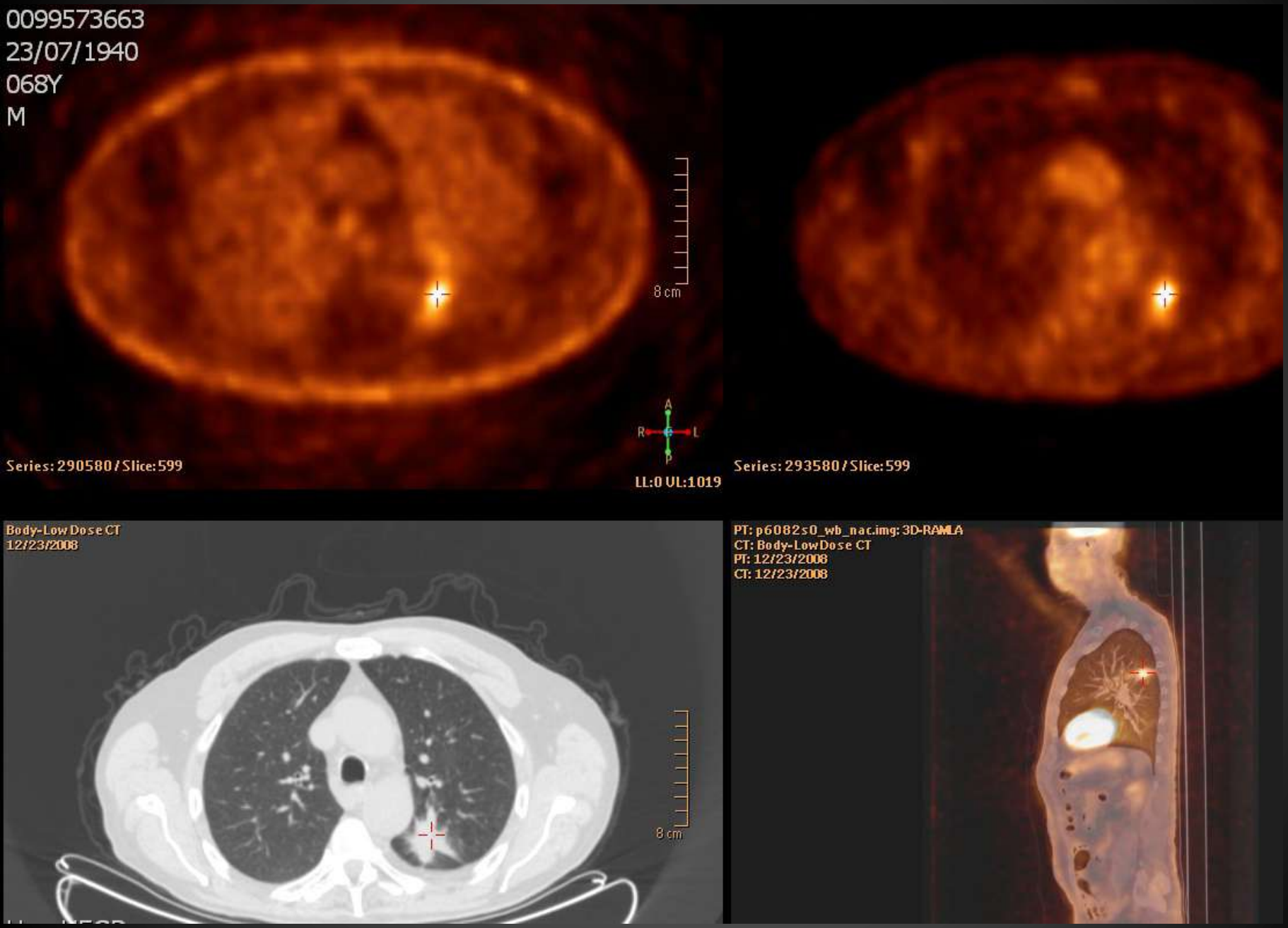
0099573663
23/07/1940
068Y
M
8 cm
A
R
L
P
Series: 290580 / Slice: 599
LL:0 UL:1019
Series: 293580 / Slice: 599
Body-Low Dose CT
12/23/2008
8 cm
PT: p6082s0_wb_nac.img: 3D-RAMLA
CT: Body-Low Dose CT
PT: 12/23/2008
CT: 12/23/2008

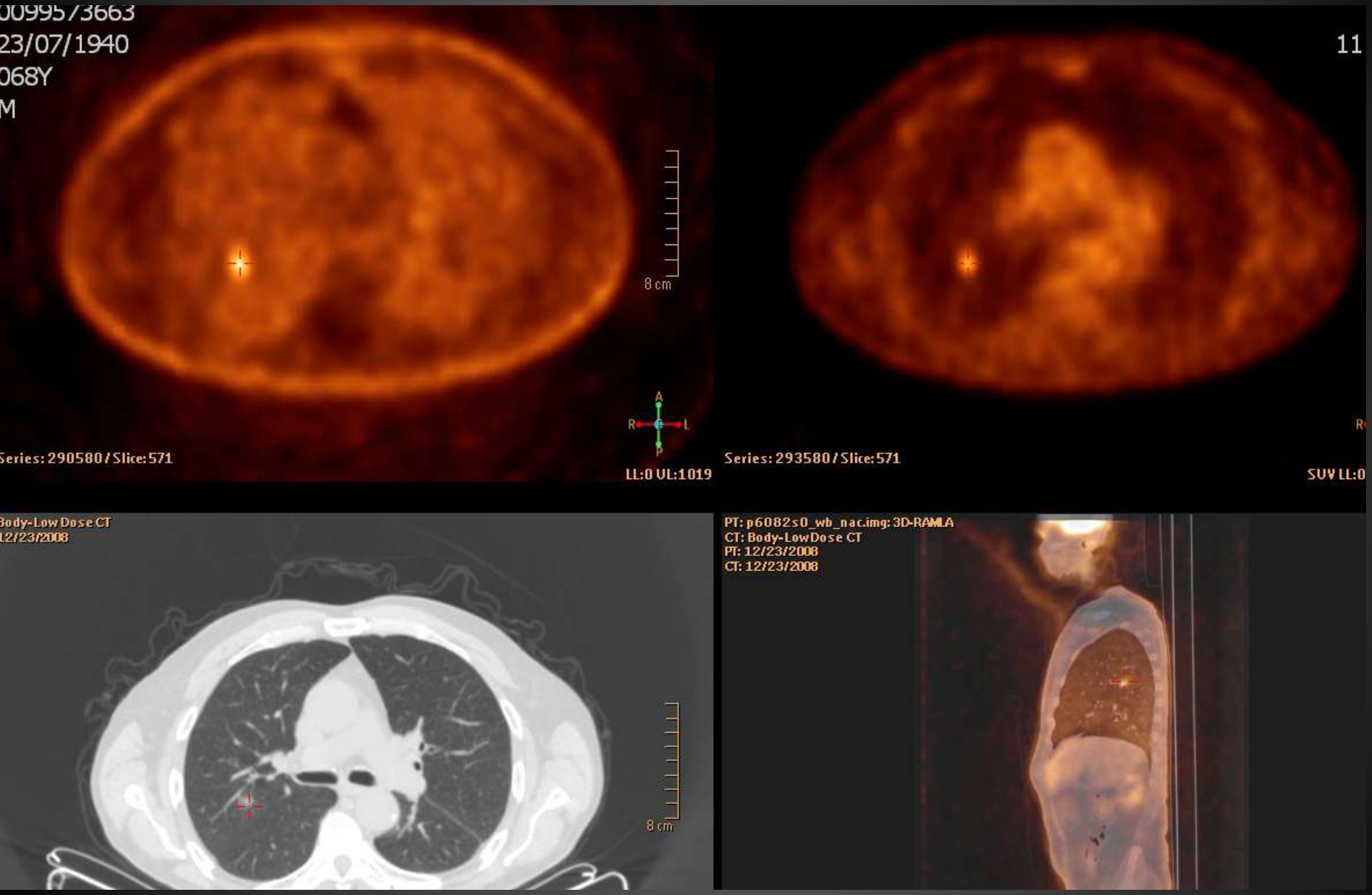
23/07/1940
068Y
M
8 cm
A
R
L
P
Series: 290580 / Slice: 571
LL:0 UL:1019
11
Series: 293580 / Slice: 571
SUV LL:0
Body-Low Dose CT
12/23/2008
8 cm
PT: p6082s0_wb_nac.img: 3D-RAMLA
CT: Body-Low Dose CT
PT: 12/23/2008
CT: 12/23/2008

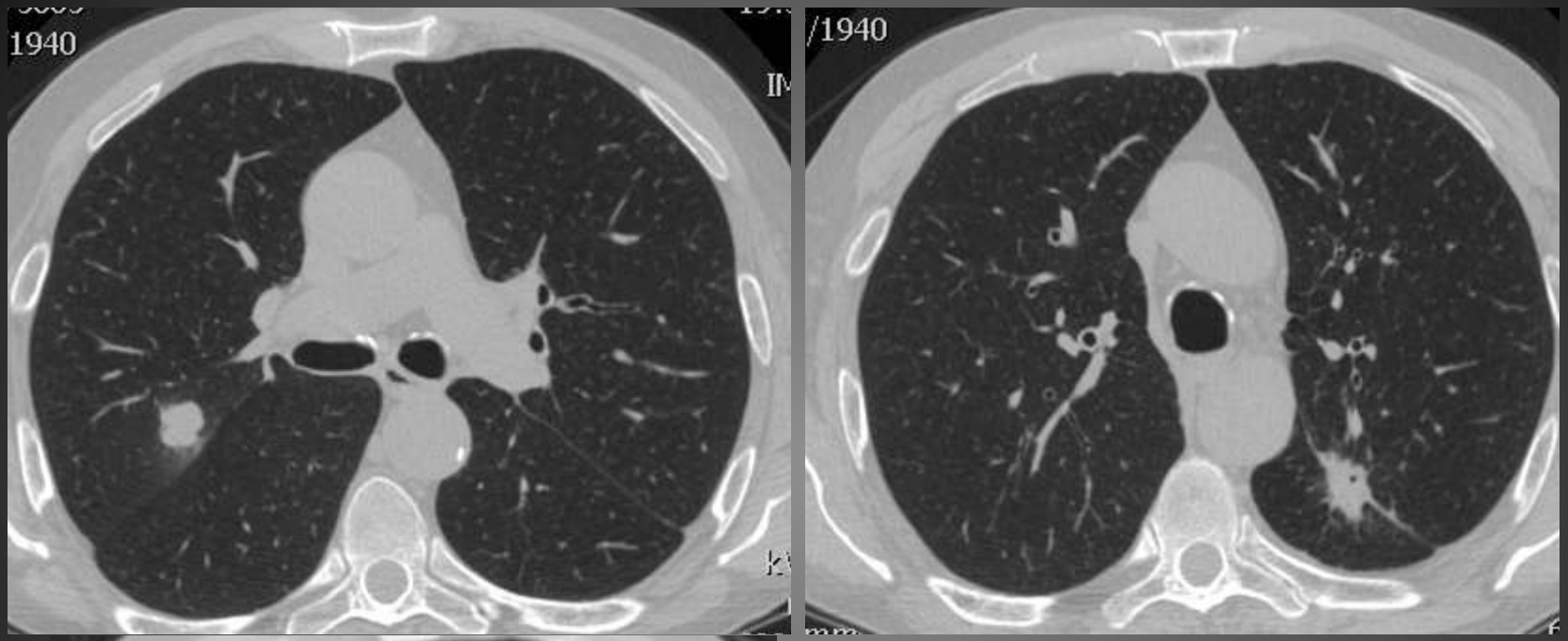
1940
/1940

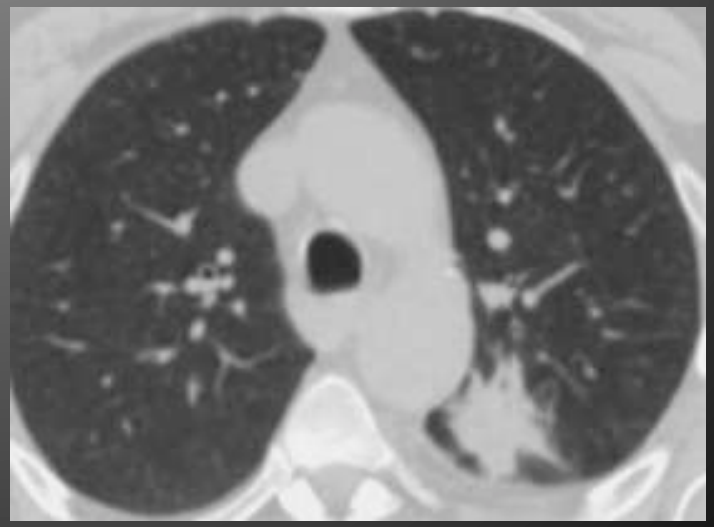

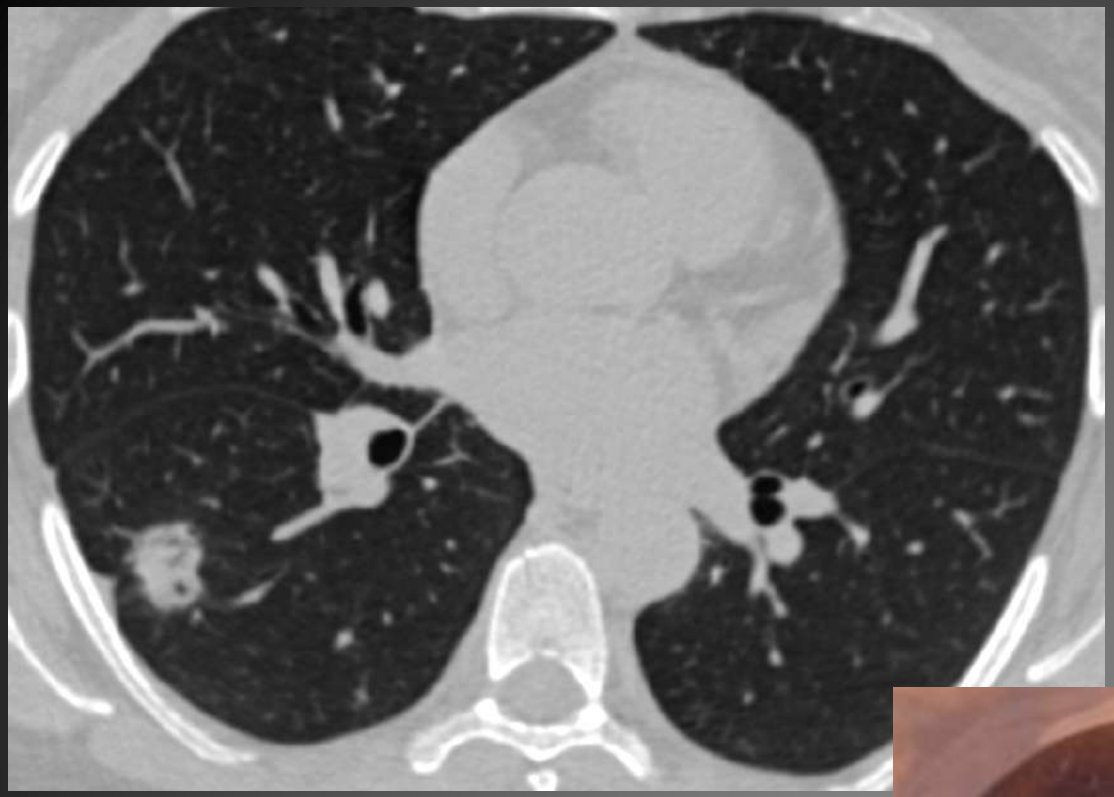

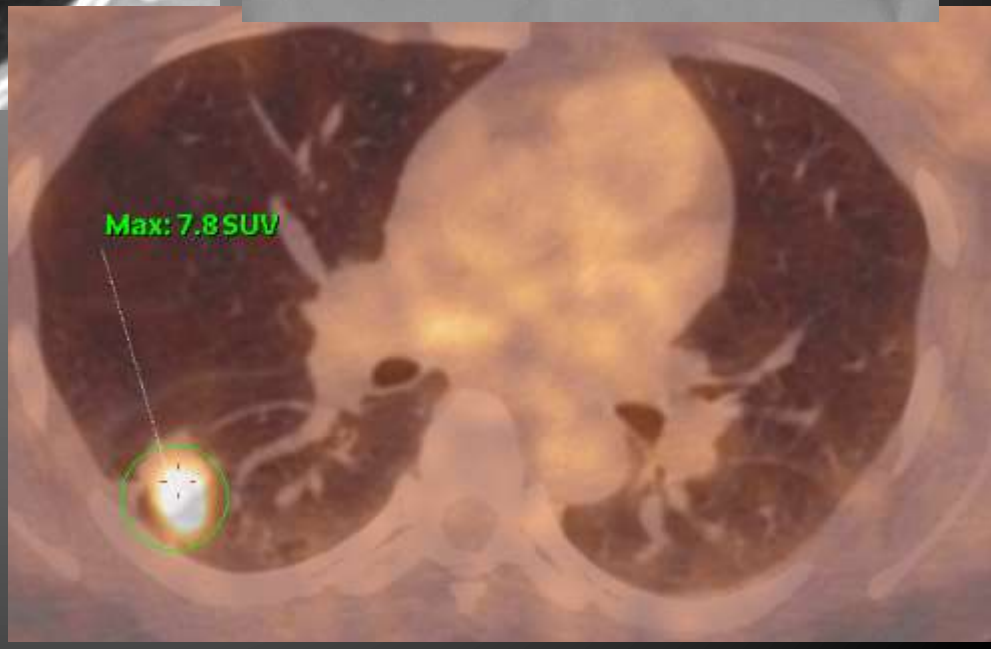

TEP DANS LE BILAN PREOPERATOIRE D'UN NODULE DU LID

HYPERMETABOLISME ANNEXIEL GAUCHE ET UTERIN

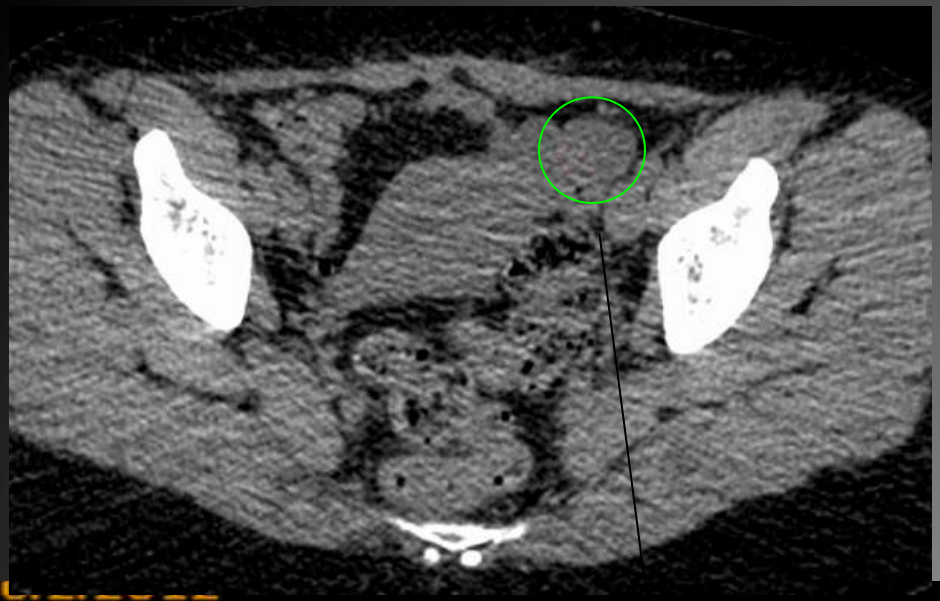

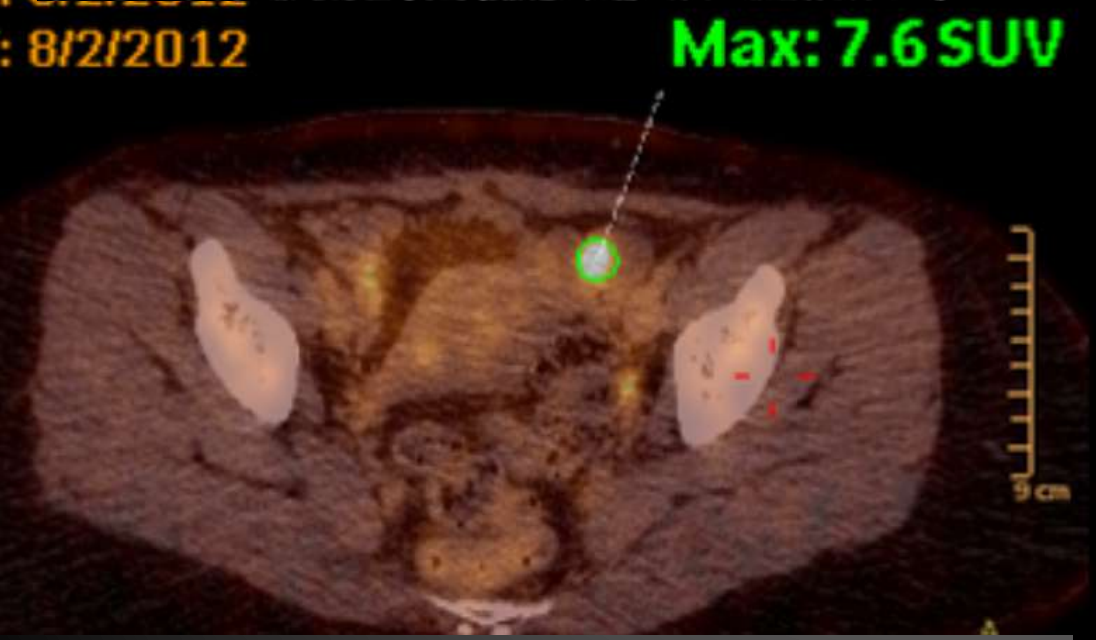

IRM &ECHO PELVIENNE:
UTERUS: RAS
ANNEXE GAUCHE: corps jaune kystisé

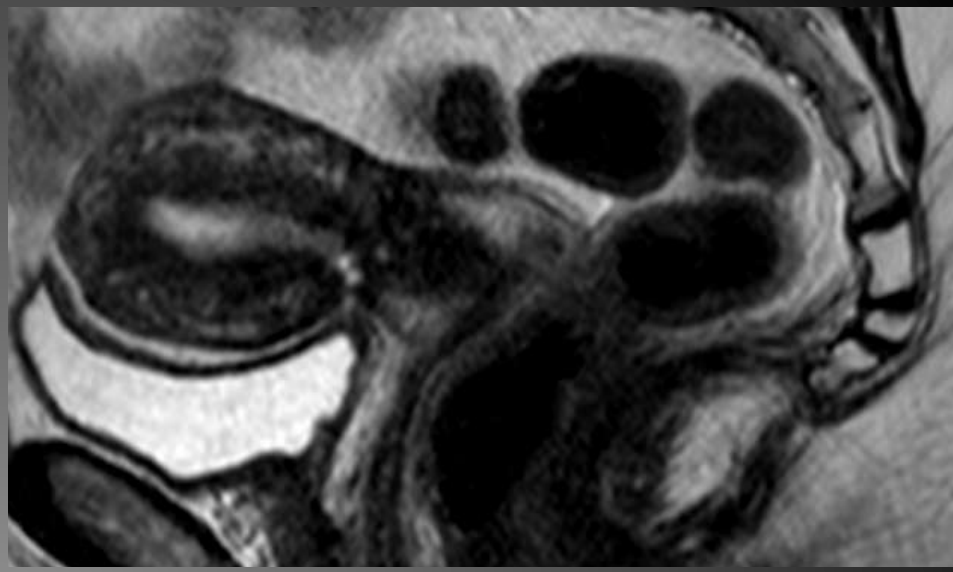

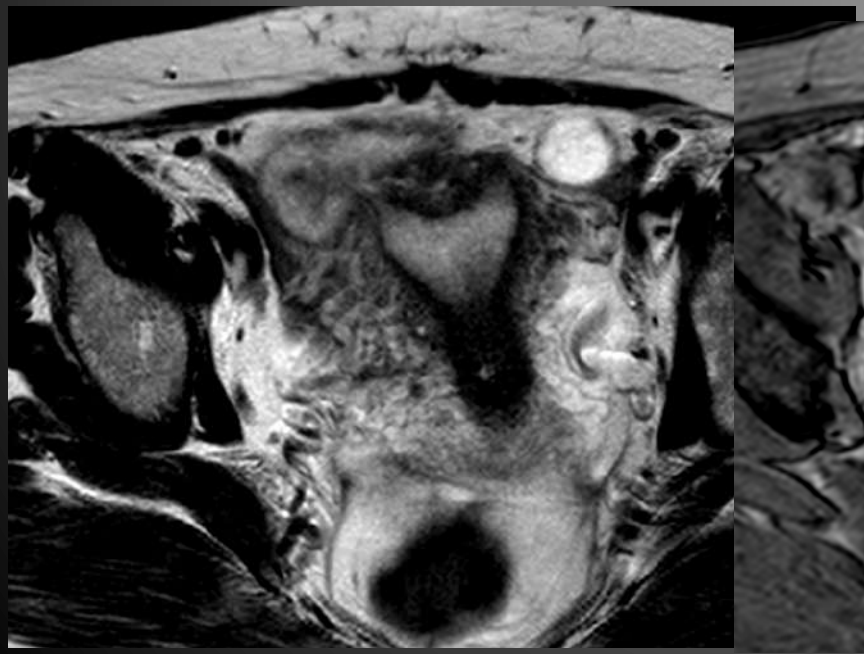

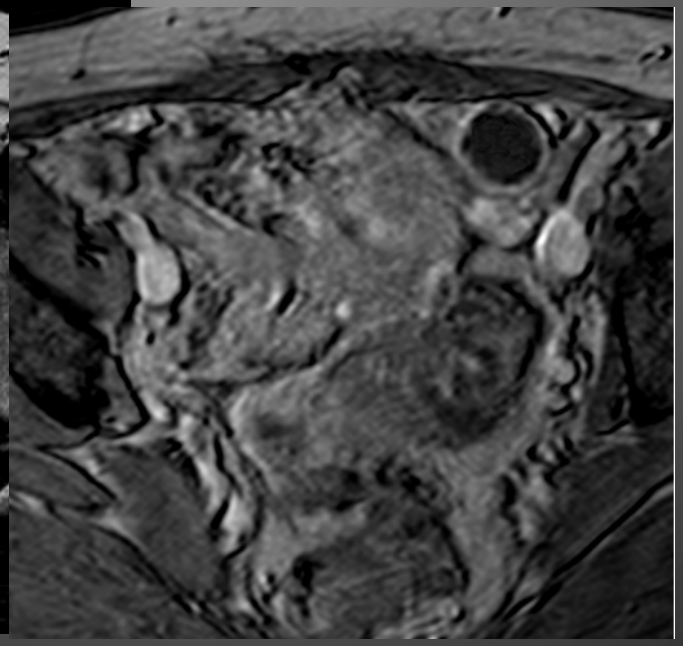

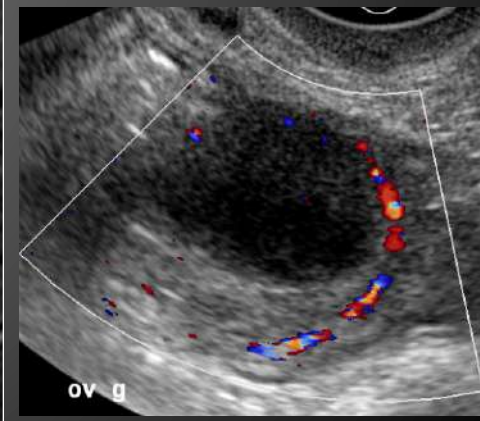

Eur J Nucl Med Mol Imaging. 2005 May;32(5):549-56. Epub 2004 Dec 14.

Physiological 18F-FDG uptake in the ovaries and uterus of healthy female volunteers.

Acta Radiol. 2009 May;50(4):455-61.

Physiological uptake of 18F-fluorodeoxyglucose in uterine endometrium and myometrium: correlation with uterine motility evaluated by cine magnetic resonance imaging.

EVALUATION DE LA REPONSE THERAPEUTIQUE

- Mauvaise application des critères RECIST

- Fausses progressions
  - Nouvelles lésions de nature non tumorale
  - Pseudo progressions sous immunothérapie

- critères RECIST: les règles
  - Sélectionner des lésions cibles mesurables
    - Au moins 1 cm
    - Les lésions osseuses ne sont pas candidates sauf composante mesurable dans les parties molles
  - Mesurer le petit axe des adénopathies, pas le grand axe
  - Respecter les délais
    - Baseline ≤4 semaines par rapport au début de la chimiothérapie
    - Se comparer au Baseline et Nadir

Mesure des adénopathies: petit axe

Meilleur reflet de la réponse

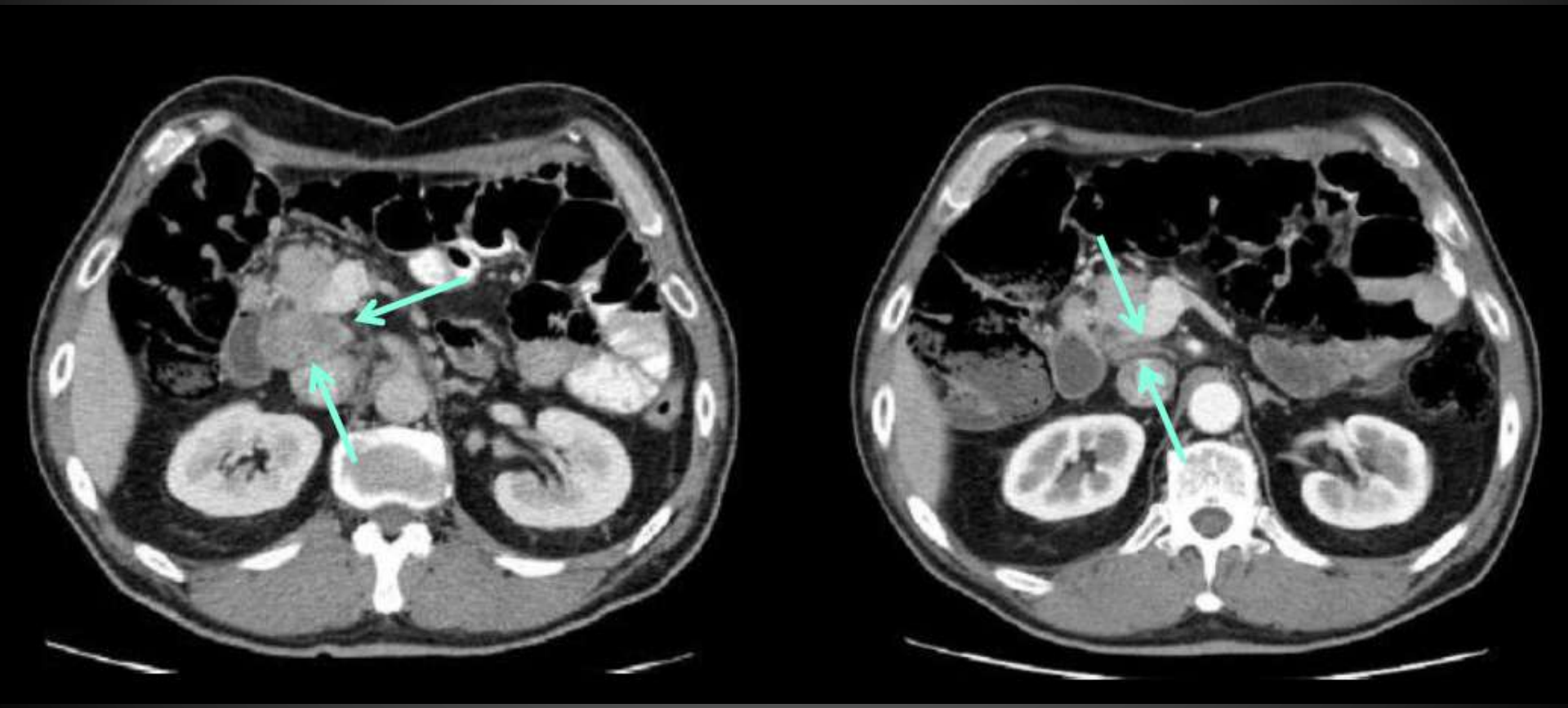

Pourquoi se référer au baseline?

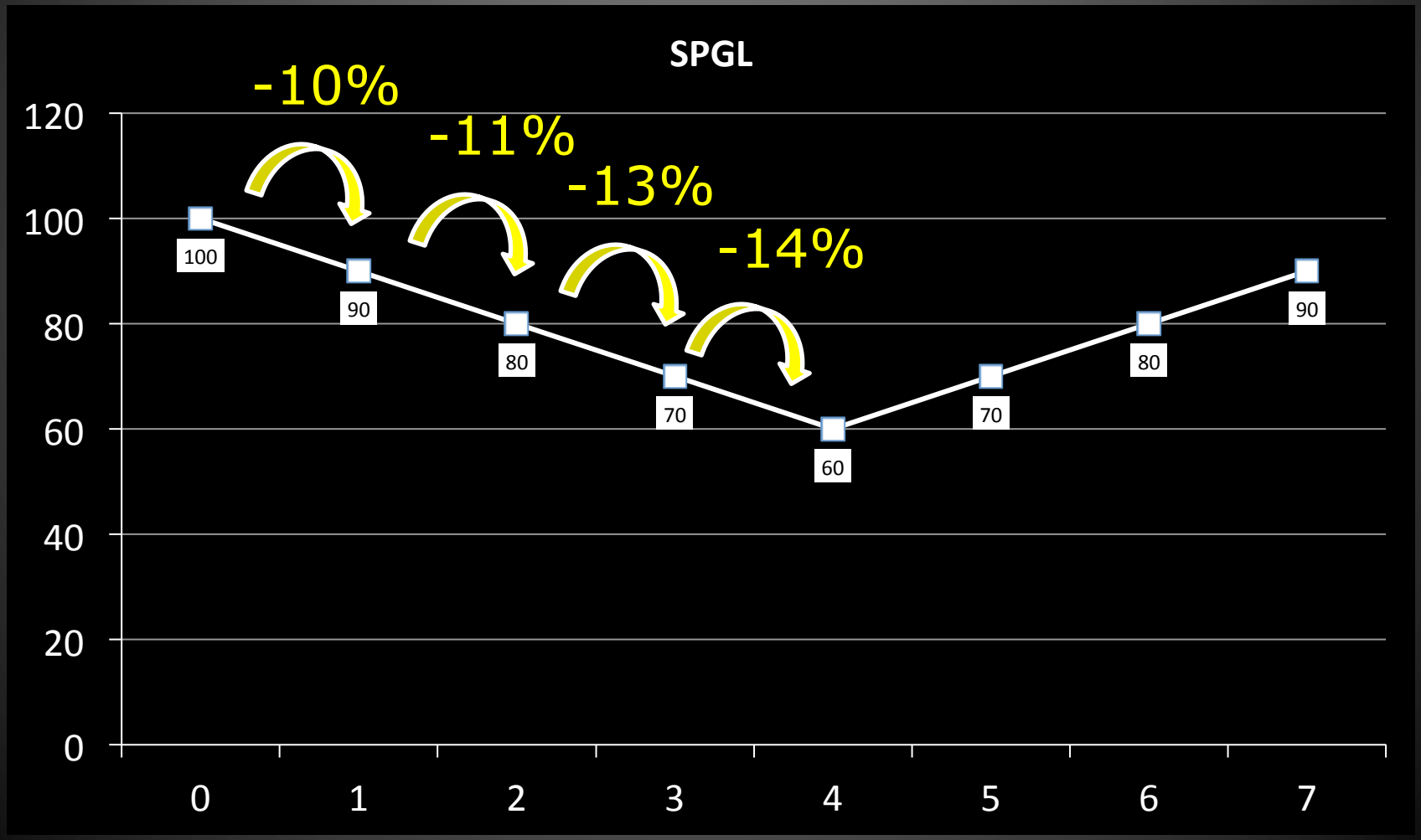

Pourquoi se référer au baseline?

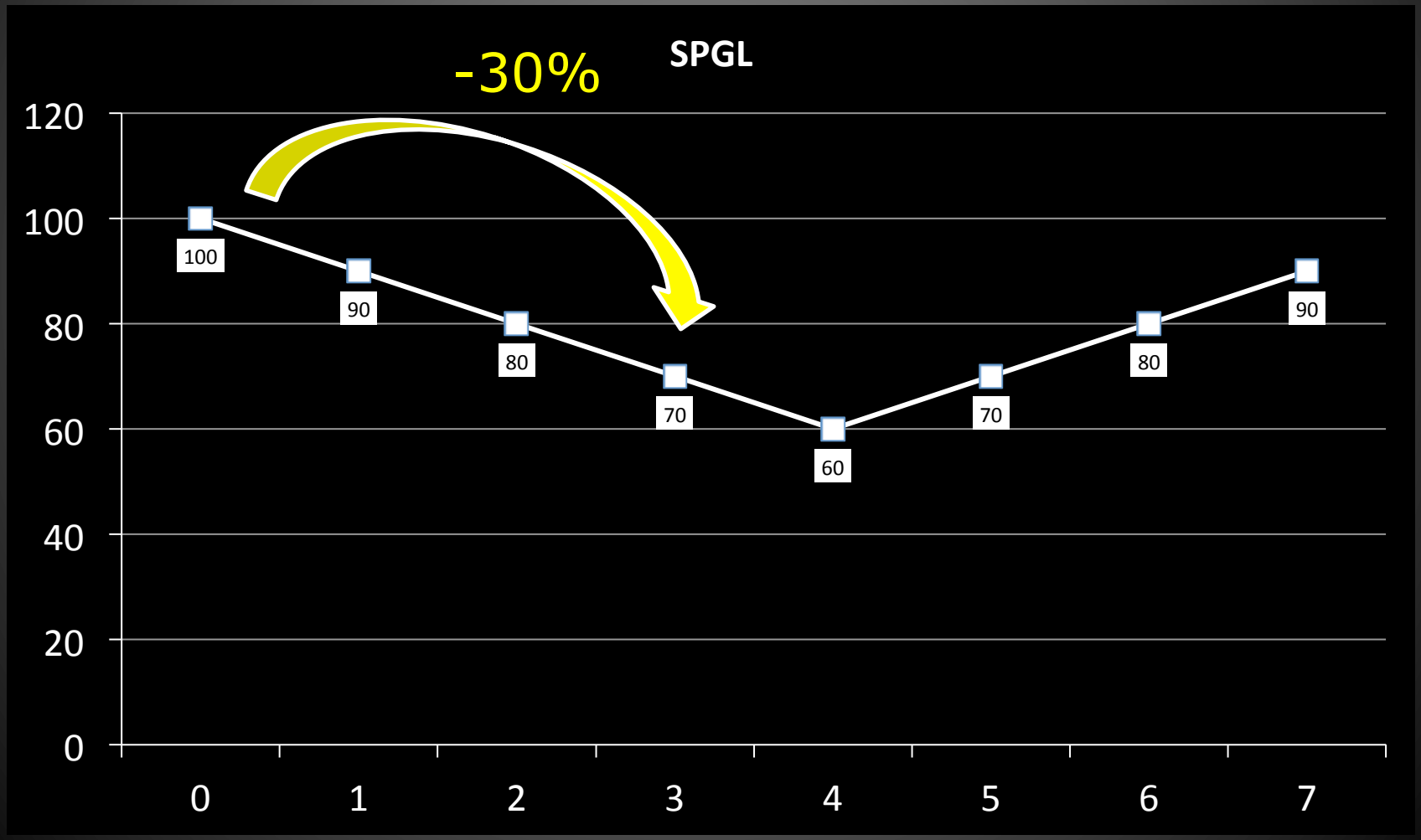

Pourquoi se référer au NADIR?

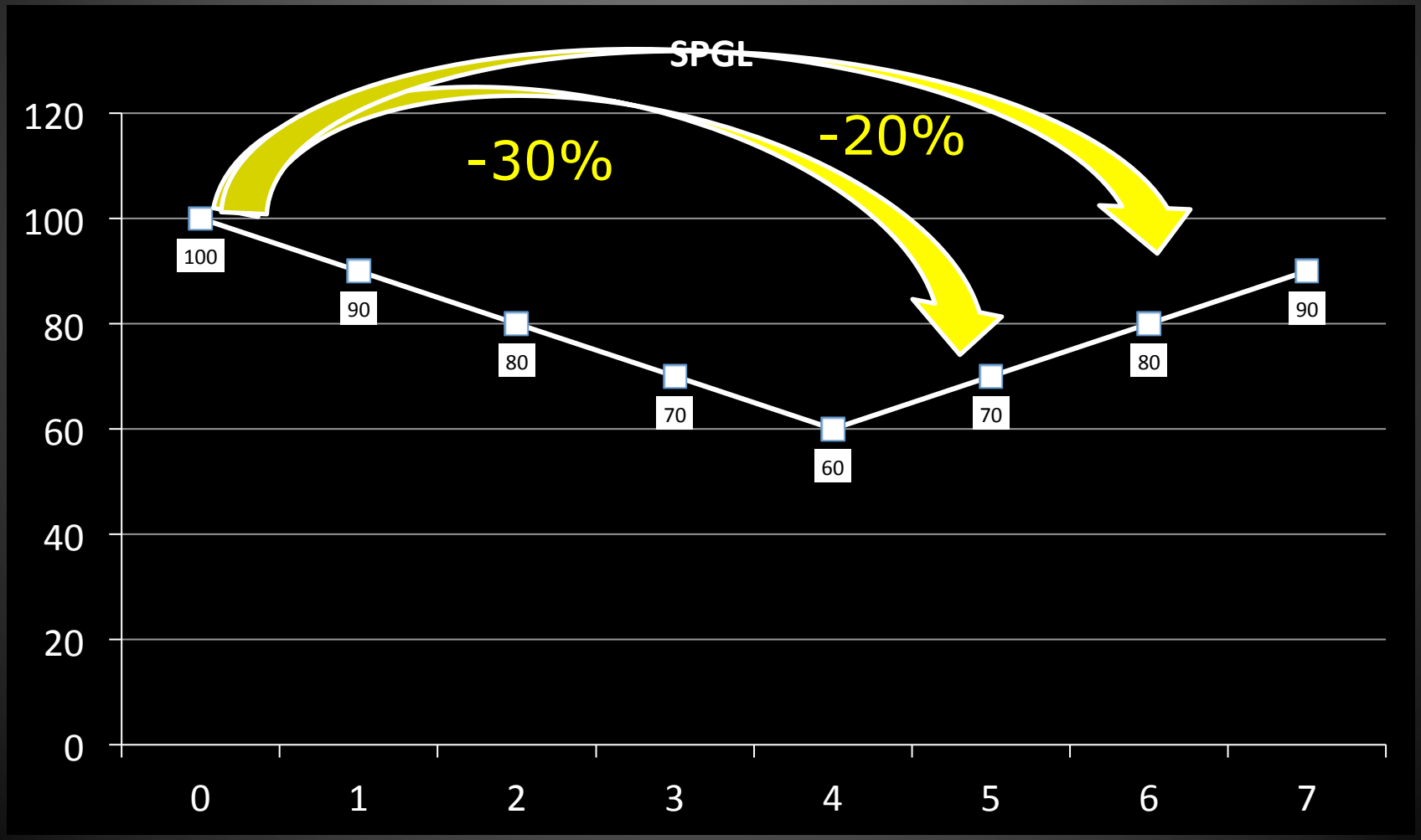

Pourquoi se référer au NADIR?

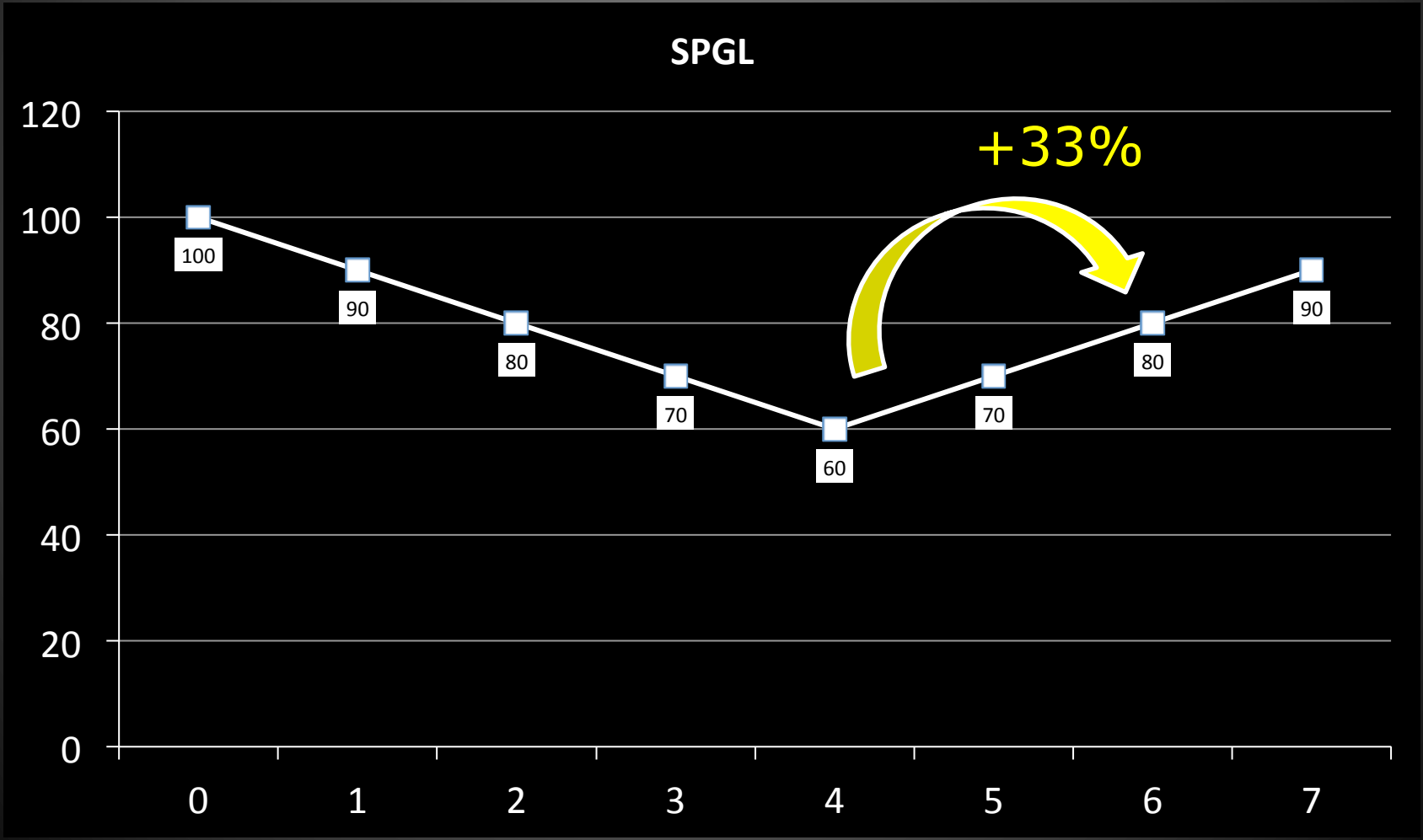

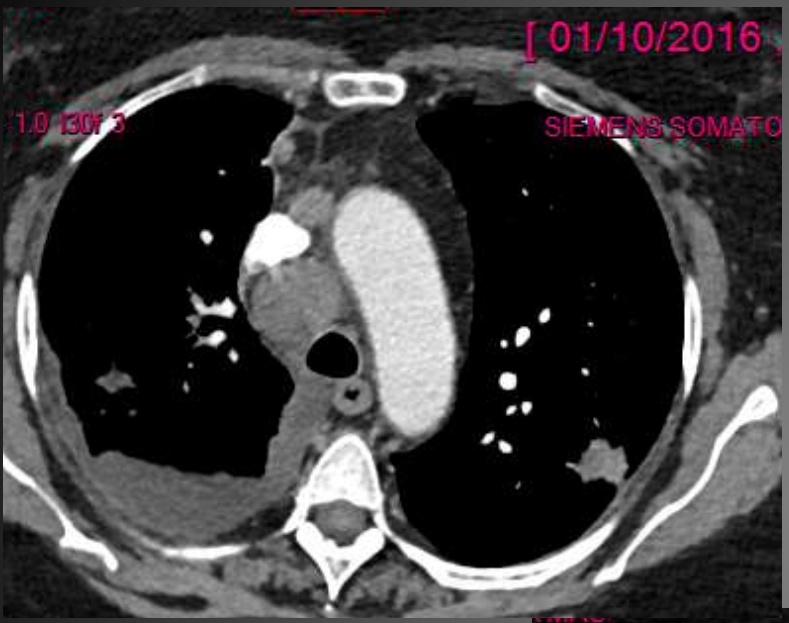
[01/10/2016
SIEMENS SOMATO

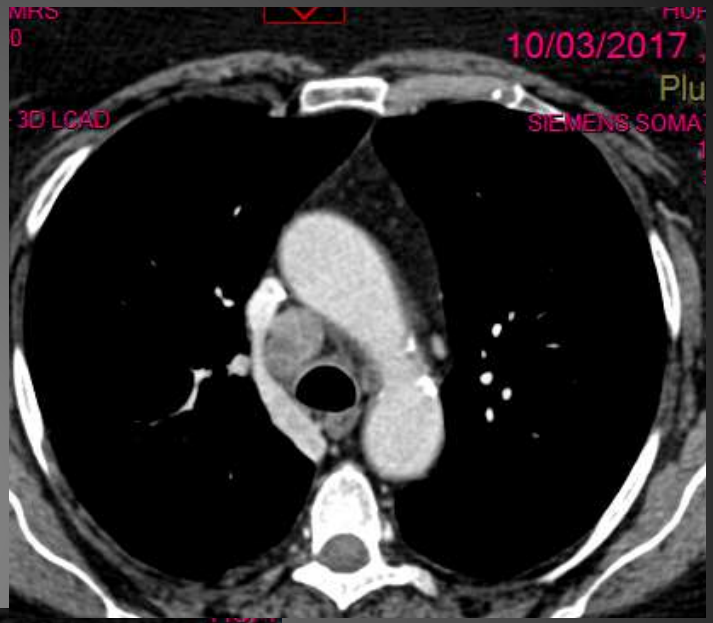
10/03/2017
3D LCAD
SIEMENS SOMA

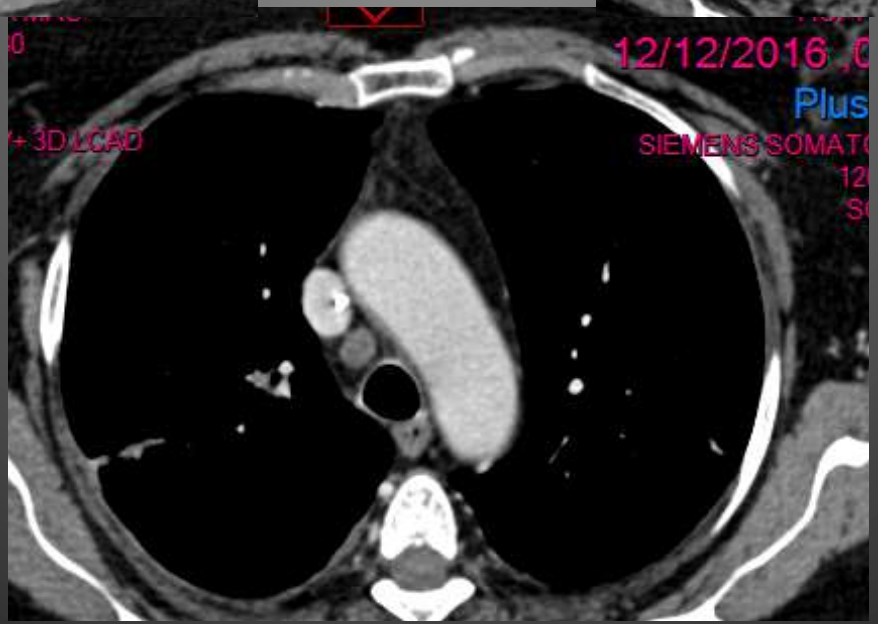
12/12/2016
Plus
3D LCAD
SIEMENS SOMAT

IMMUNOTHERAPIE

- L'afflux de cellules T (« flare-up » effect) peut créer des effets de pseudo progression (6 à 7% des cas)

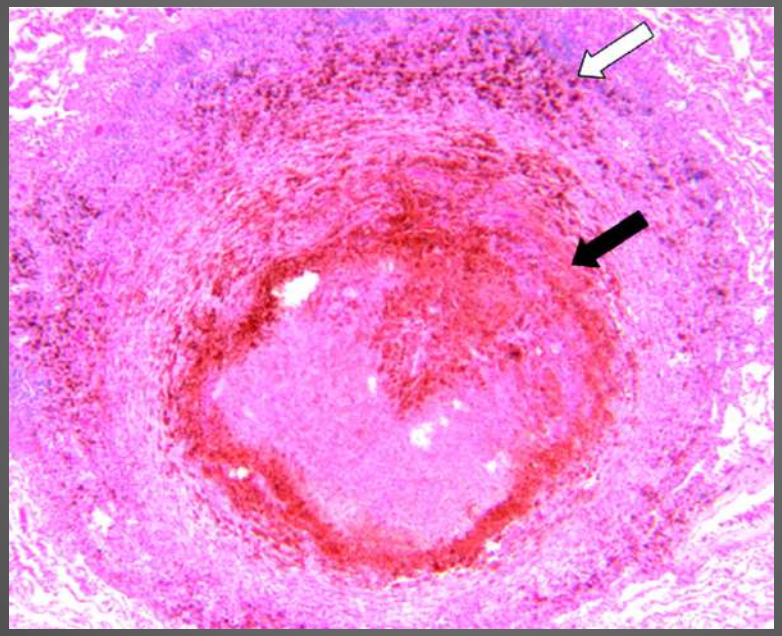

T-cell infiltration (white arrow) and necrosis (black arrow) in lung metastasis from melanoma under immunotherapy

Réponse après pseudoprogression

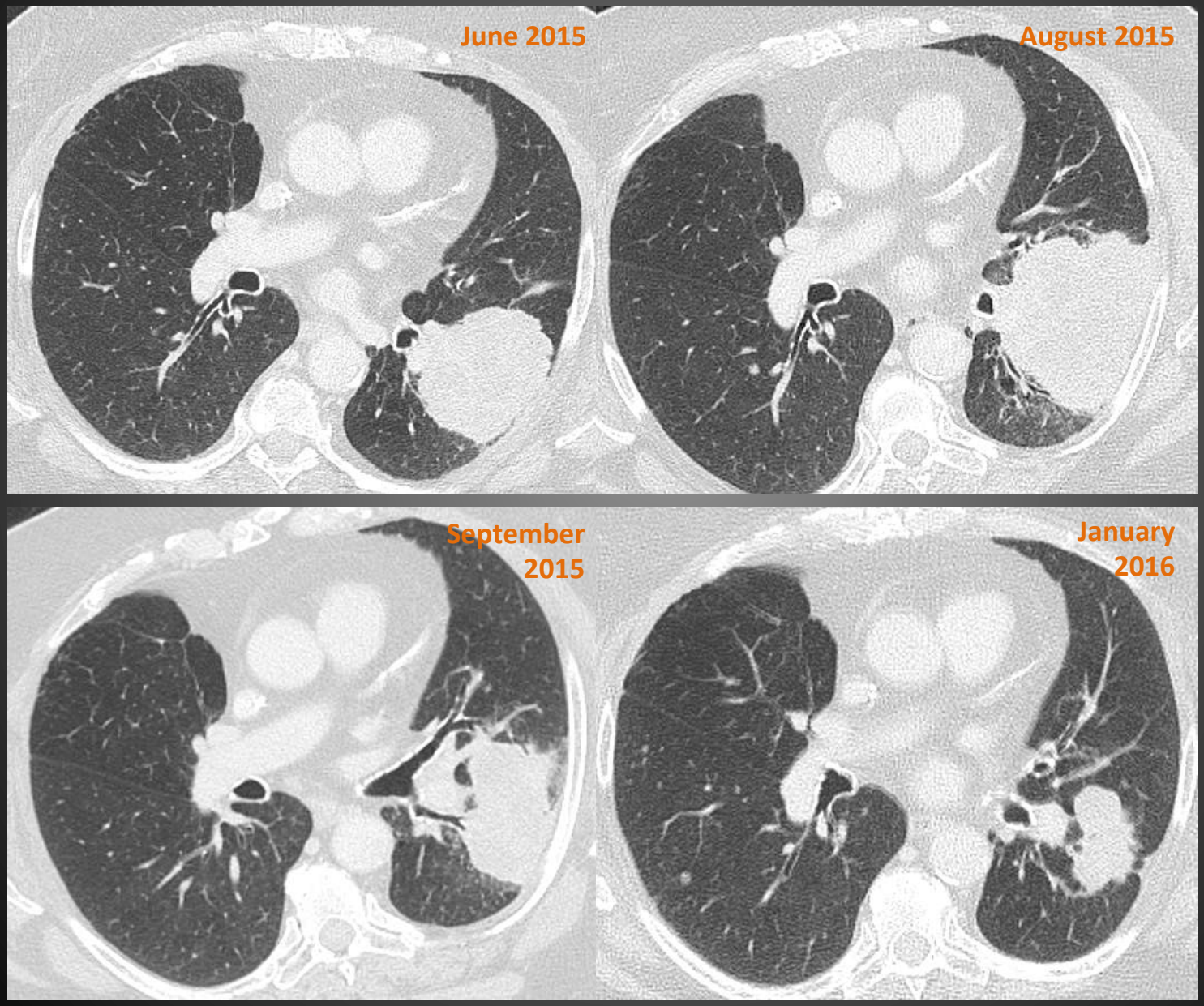

Réponse après pseudoprogression

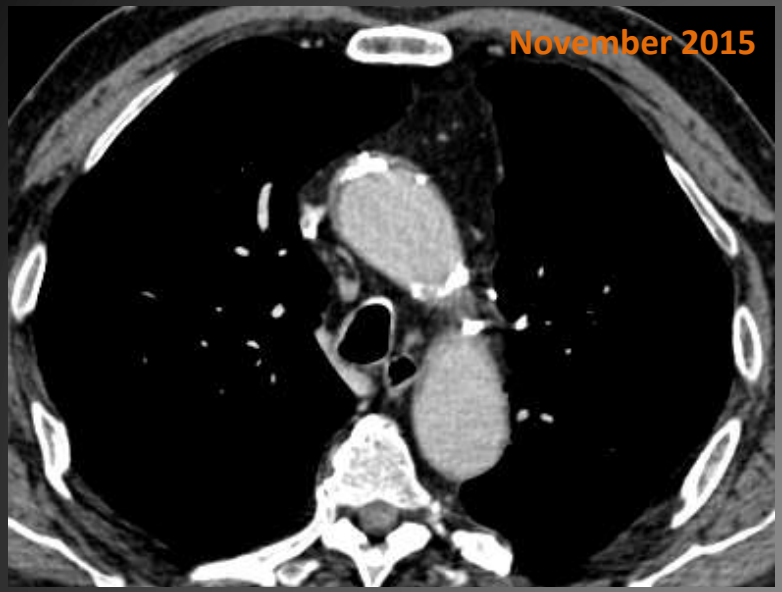

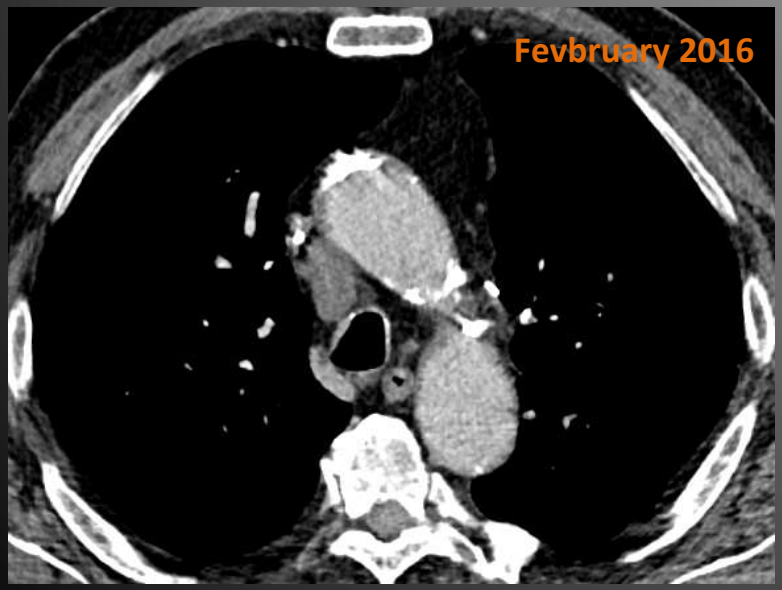

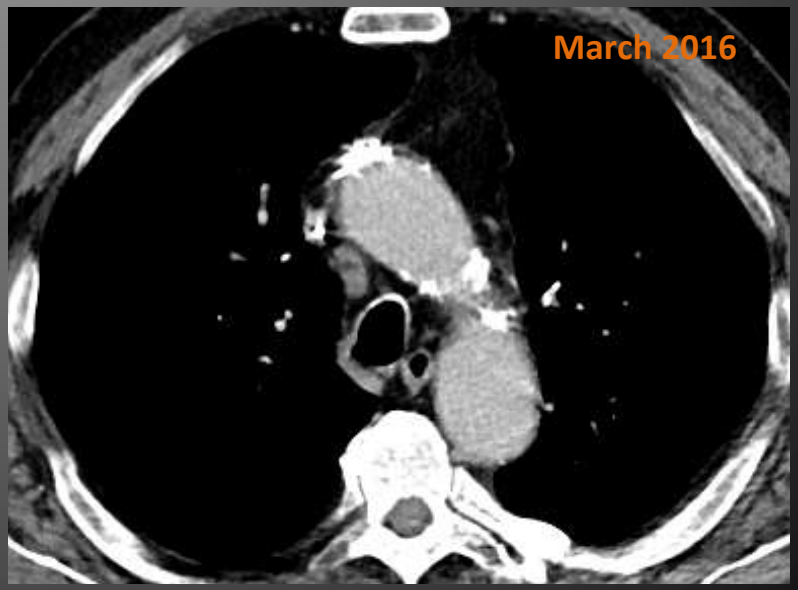

Réponse après pseudoprogression

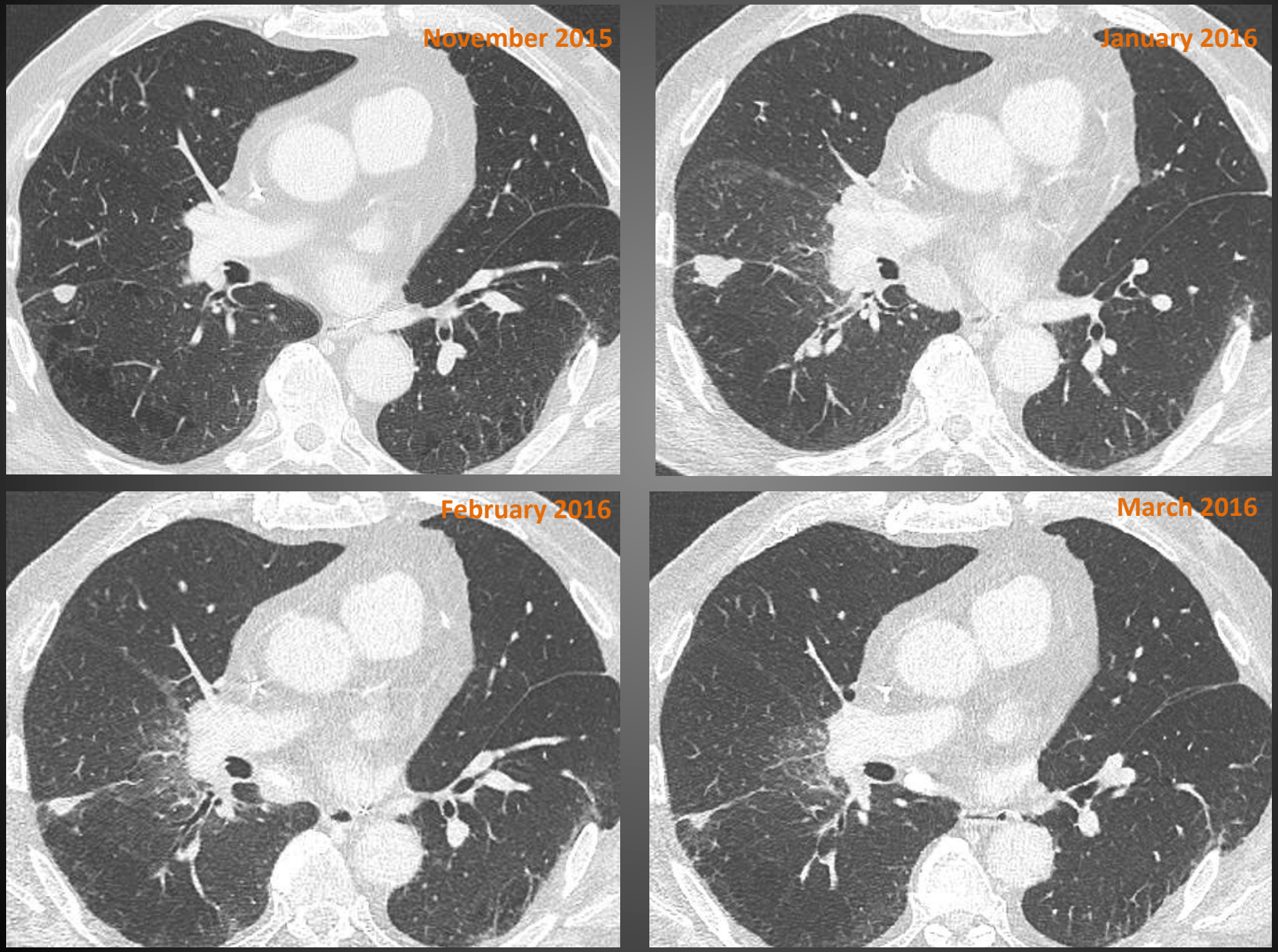

SUIVI SOUS TRAITEMENT

- Fausses rechutes
  - Nouvelles images de nature non tumorale
    - Toxicité
    - Images infectieuses
    - Lésions ischémiques: envahissement veineux ou complication thrombo embolique

- Distinction séquelles radiques/ évolution tumorale reste difficile

- Patiente de 50 ans, traitement adjuvant post pneumonectomie gauche par une association incluant du taxotère (Docetaxel).
- Après le 4ème cycle: épanchement pleural droit, épanchement péricardique, et inflation liquidienne de la loge de pneumonectomie.
- Rechute?

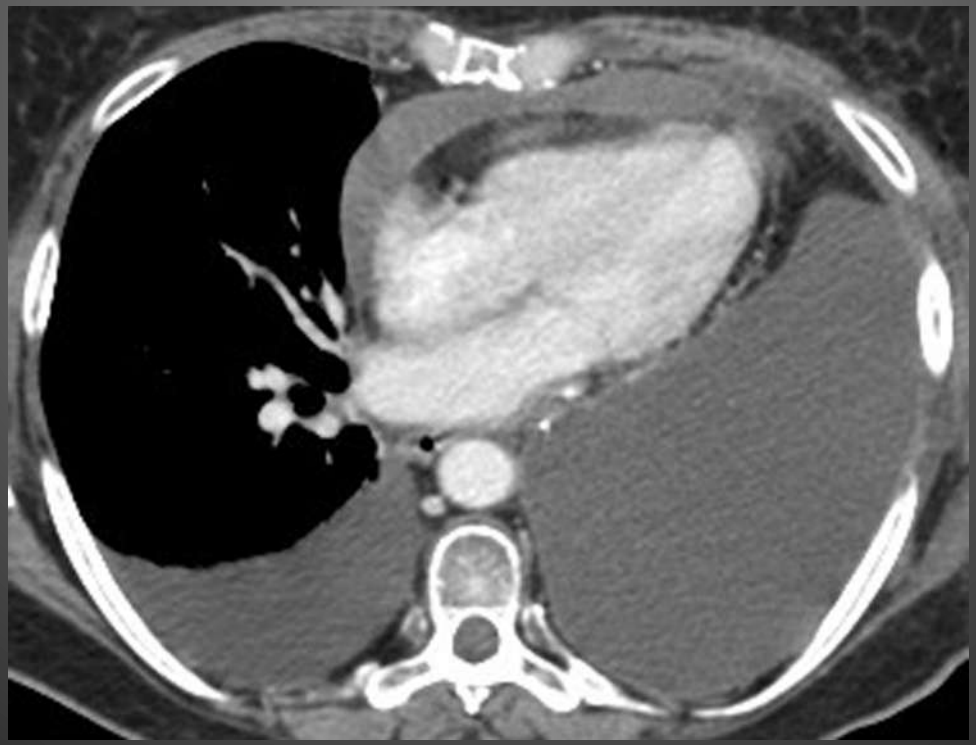

Vidéothoracoscopie droite avec talcage: pas de rechute
Syndrome de fuite capillaire

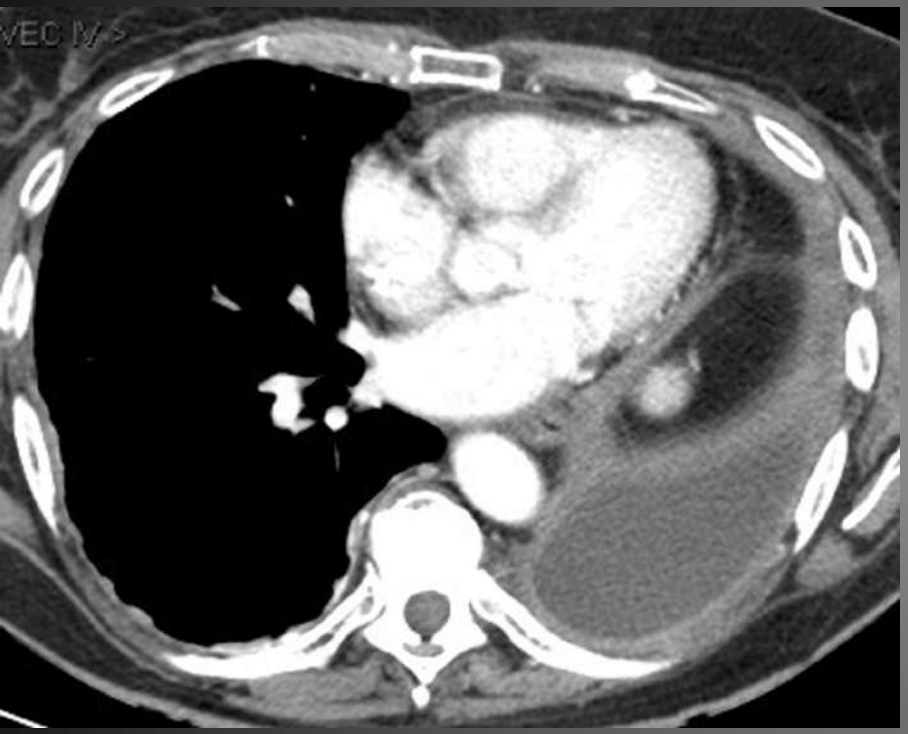

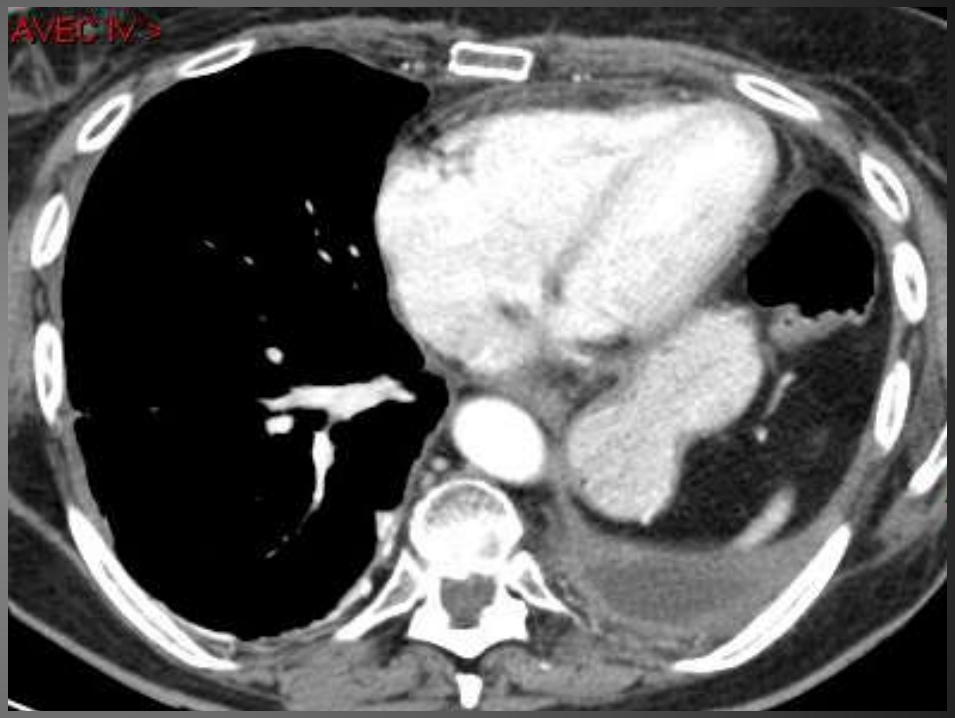

- Contrôle à distance. Les épanchements ont régressé, de même que l'inflation hydrique dans la loge de pneumonectomie.

Mars

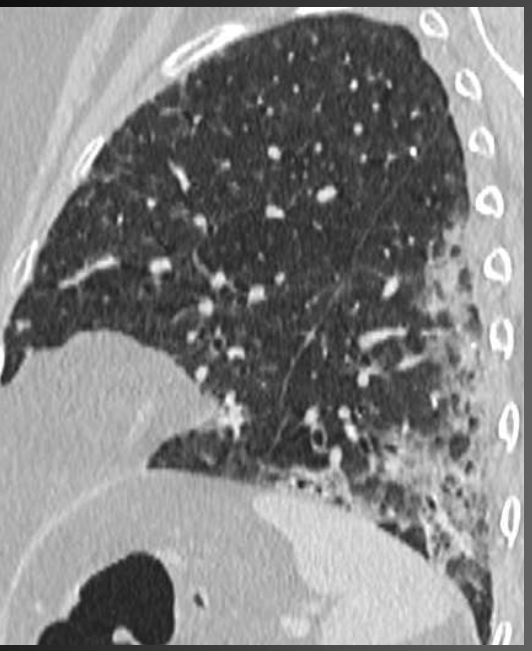

Avril

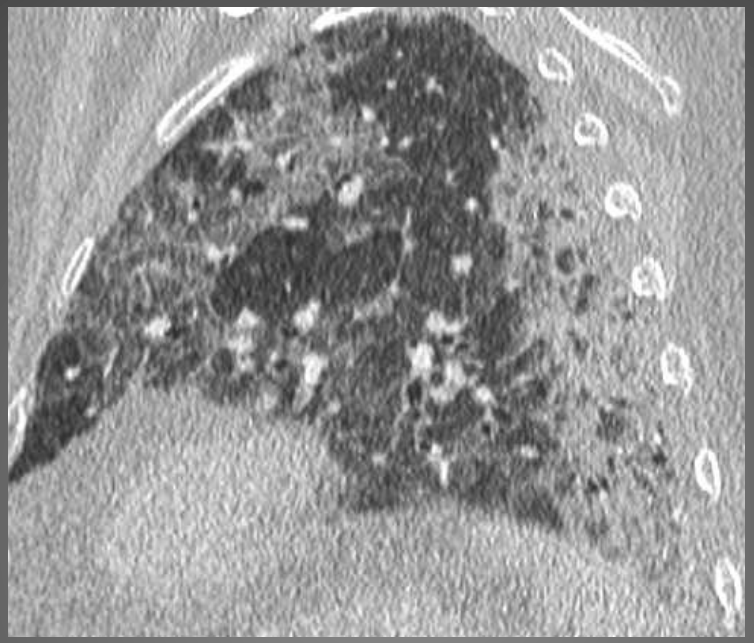

Juin

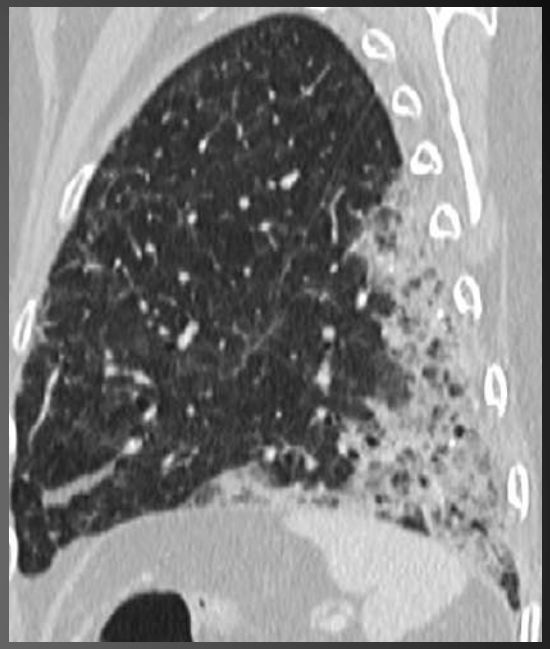

Adénocarcinome mucineux en rechute LIG, traitement par GEMZAR en 3ème ligne

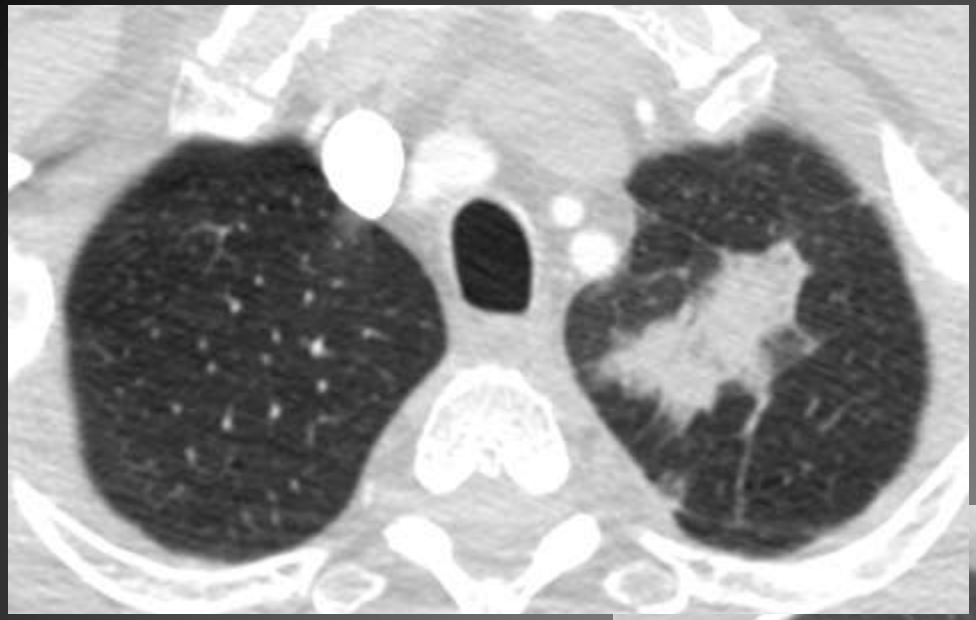

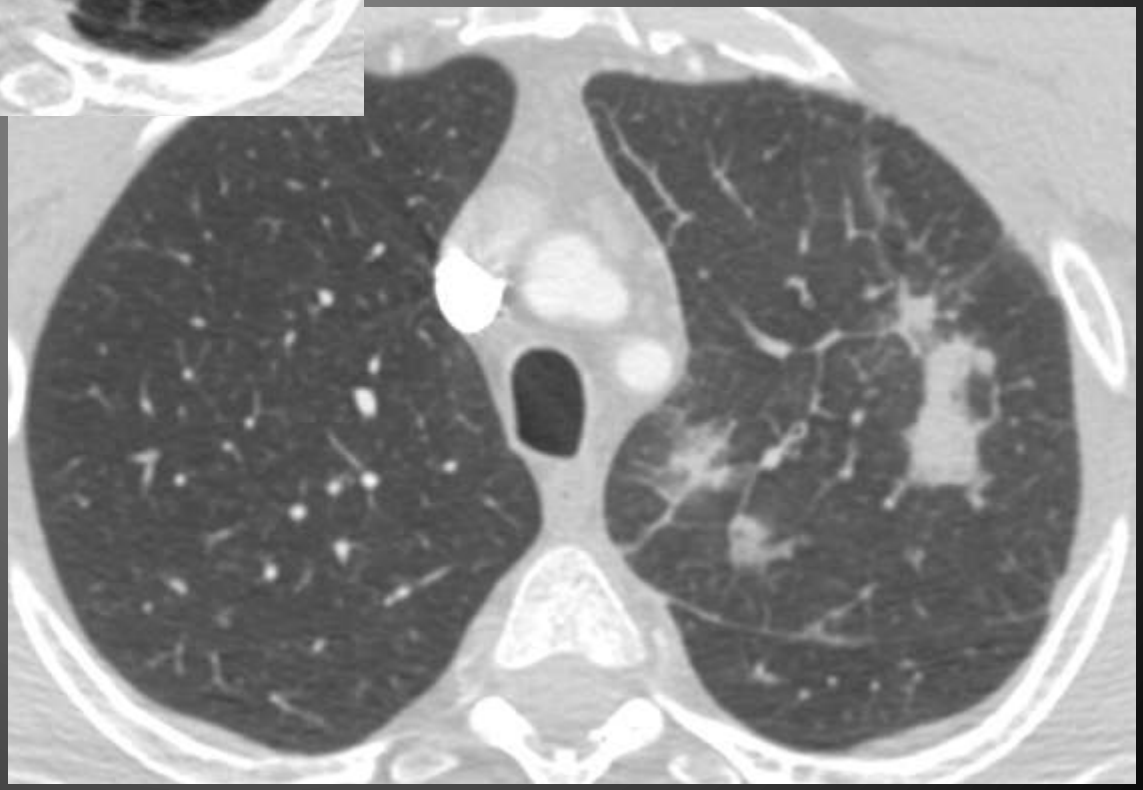

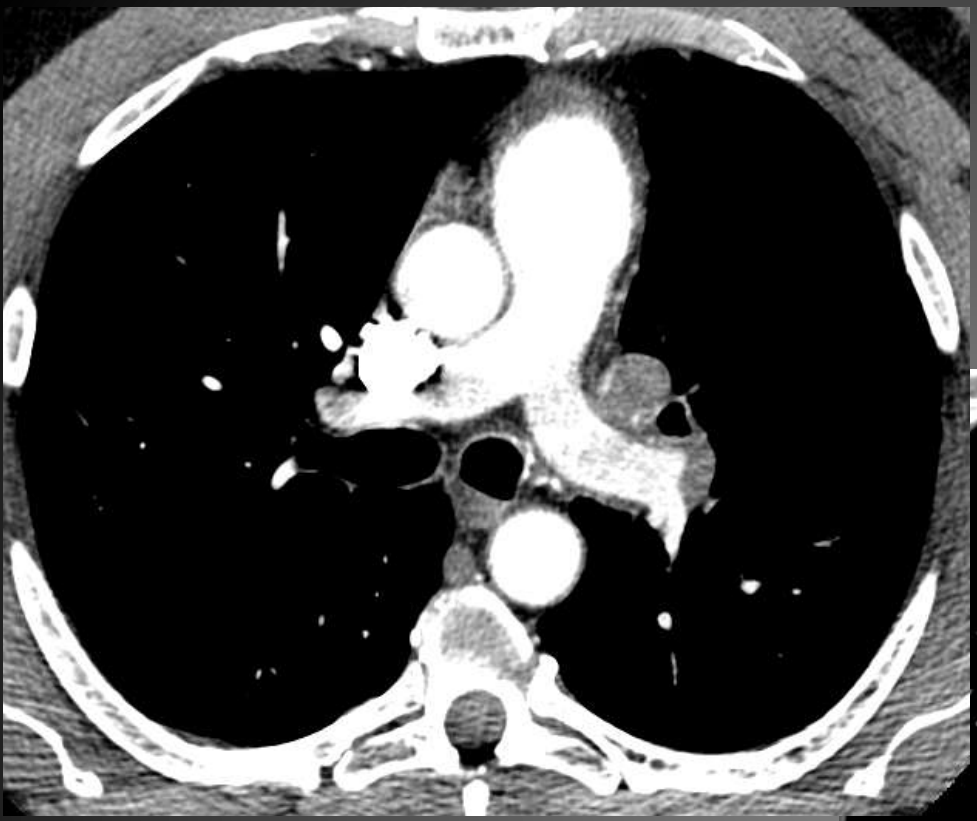

- Autre patient, suspicion de rechute après pneumonectomie gauche

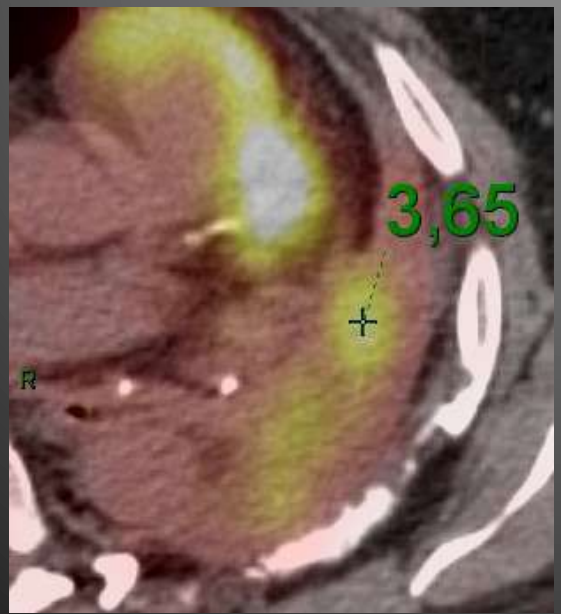

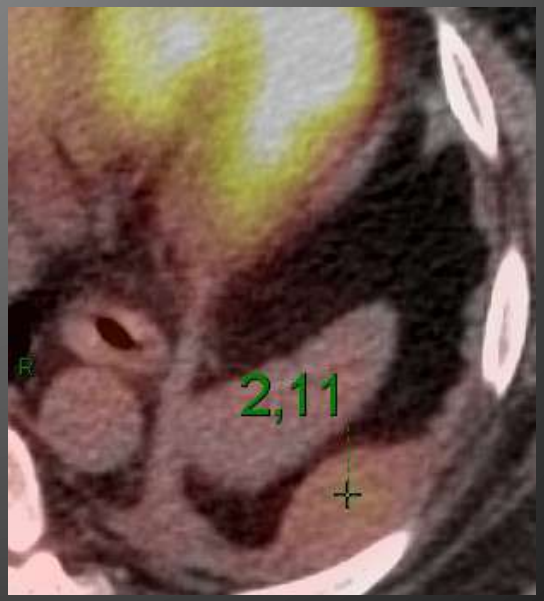

Case Report

A Case of Desmoid-Type Fibromatosis Arising after Thoracotomy for Lung Cancer with a Review of the English and Japanese Literature

Takeshi Mori, MD, PhD, Tatsuya Yamada, MD, Yasuomi Ohba, MD, PhD, Kentaro Yoshimoto, MD, PhD, Koei Ikeda, MD, PhD, Kenji Shiraishi, MD, PhD, and Makoto Suzuki, PhD, MD

Chest wall desmoid-type fibromatoses are rare, locally aggressive tumors that occasionally arise from previous thoracotomy sites. Tumors arising from previous sites of thoracotomy to treat malignant disease should be discriminated from the pleural dissemination of the previous malignancy. In this study, we report a case of desmoid-type fibromatosis arising from a site for thoracotomy to treat lung cancer. Additionally we reviewed 15 reported cases of desmoid-type fibromatosis following thoracotomy and summarized their features. A 62-year-old woman was found to have a tumor on computed tomography (CT) at a 1-year routine checkup for lung cancer. The tumor (diameter, 3.4 cm) was located at the previous thoracotomy site. Positron emission tomography (PET) revealed mild ^{18}F-fluorodeoxyglucose (FDG) accumulation in the tumor, with a maximal standardized uptake value (SUV_{max}) of 1.9. CT-guided biopsy revealed only fibrous tissue. Eighteen months after the biopsy, CT revealed apparent tumor growth, and a biopsy revealed the same histology observed previously. The tumor was removed and diagnosed as desmoid-type fibromatosis. Currently, the patient is alive without recurrence 4 years after desmoid surgery.

Mori T et al Ann Thorac Cardiovasc Surg. 2014;20 Suppl:465-9

SUV:2.25

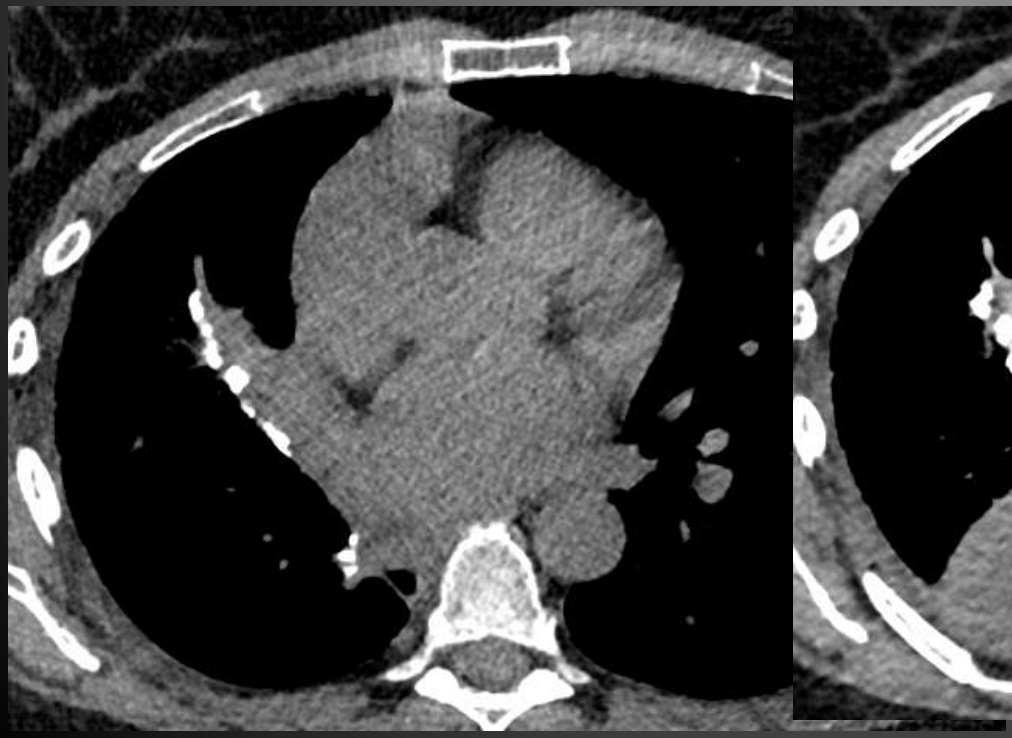

Lobectomie supérieure droite en dec 2007
Récidive dans la loge de Baréty - Juillet 2008

Taxol et Radiothérapie 65 Gy- Fin : Août 2008

Juin 2009

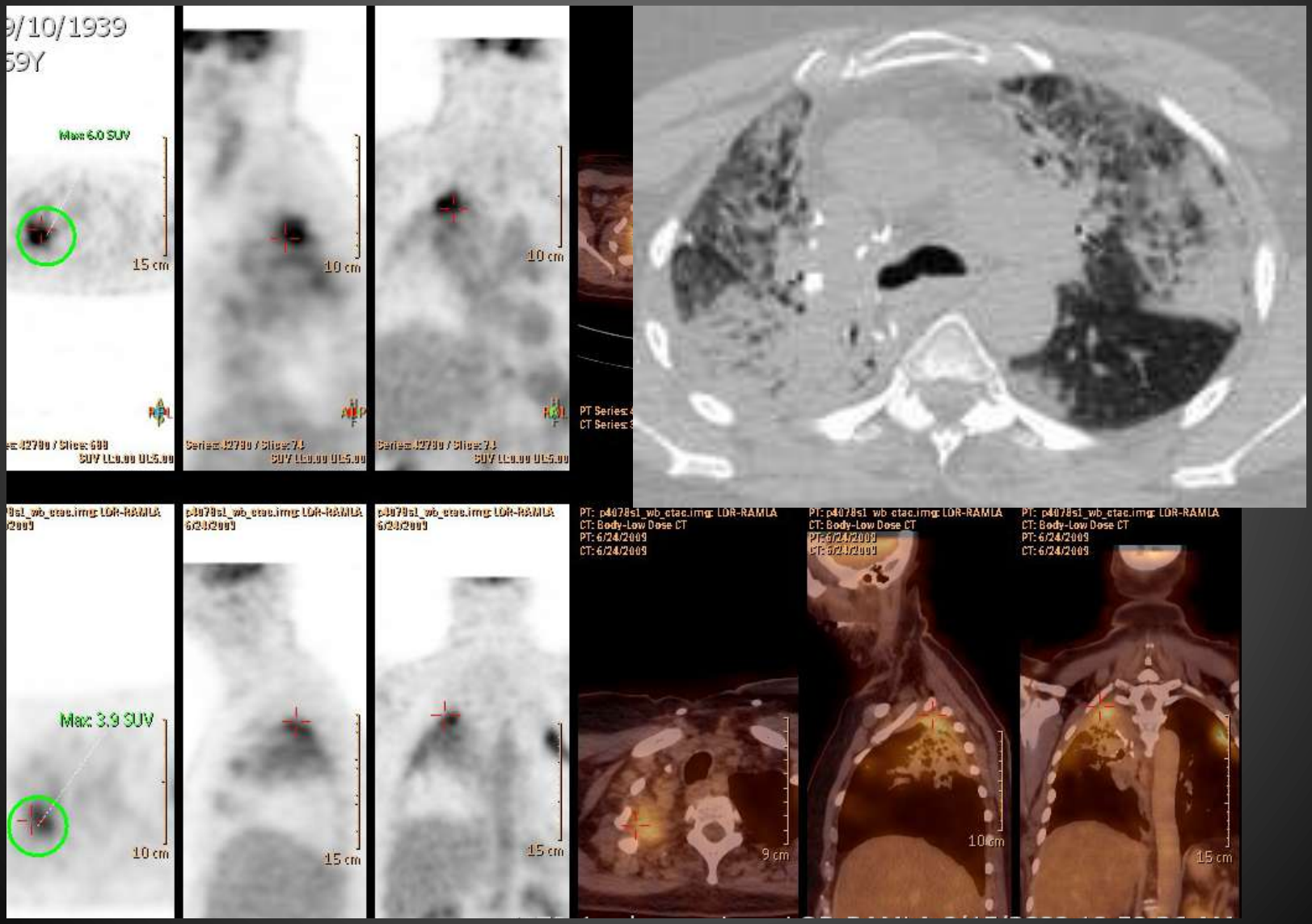
9/10/1939
59Y
Max 6.0 SUV
15 cm
10 cm
10 cm
Max: 3.9 SUV
10 cm
15 cm
15 cm
PT: p4078s1_wb_ctac.img: LOR-RAMLA
CT: Body-Low Dose CT
PT: 6/24/2009
CT: 6/24/2009
9 cm
10 cm
15 cm

Novembre 2009

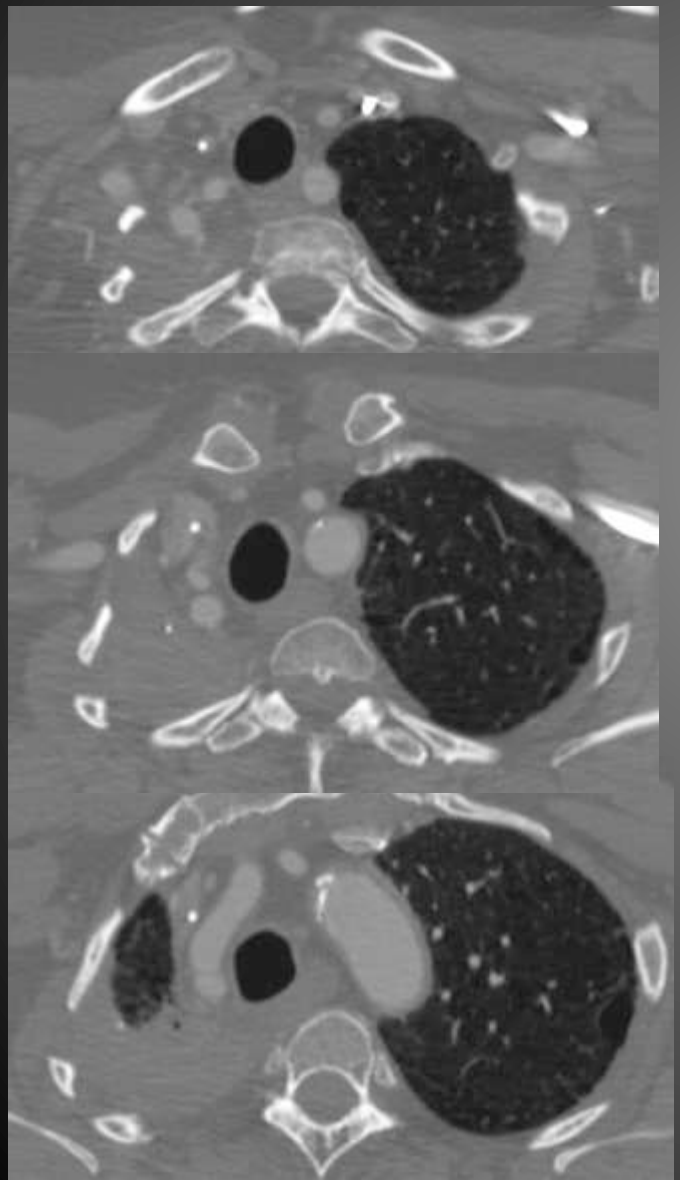

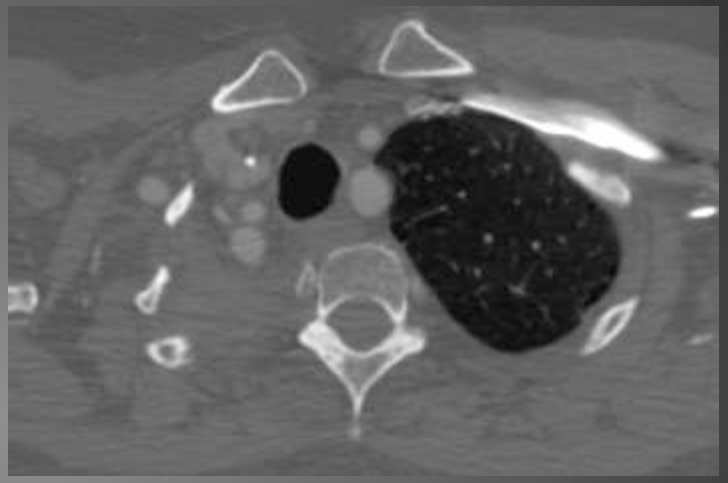

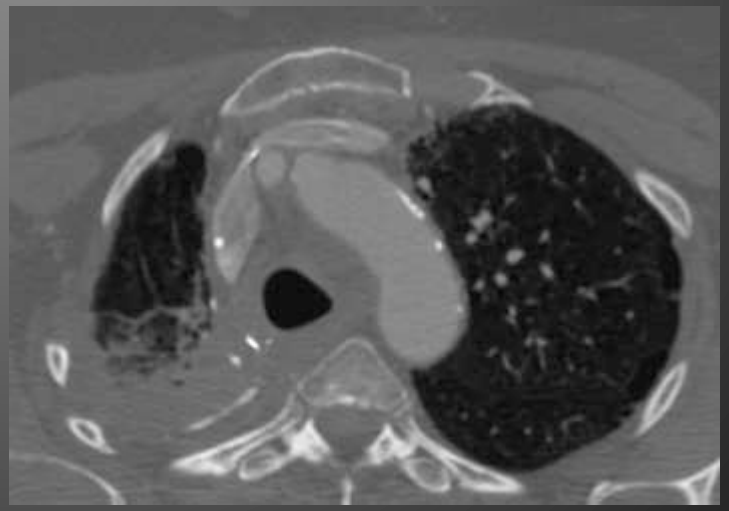

Avril 2010

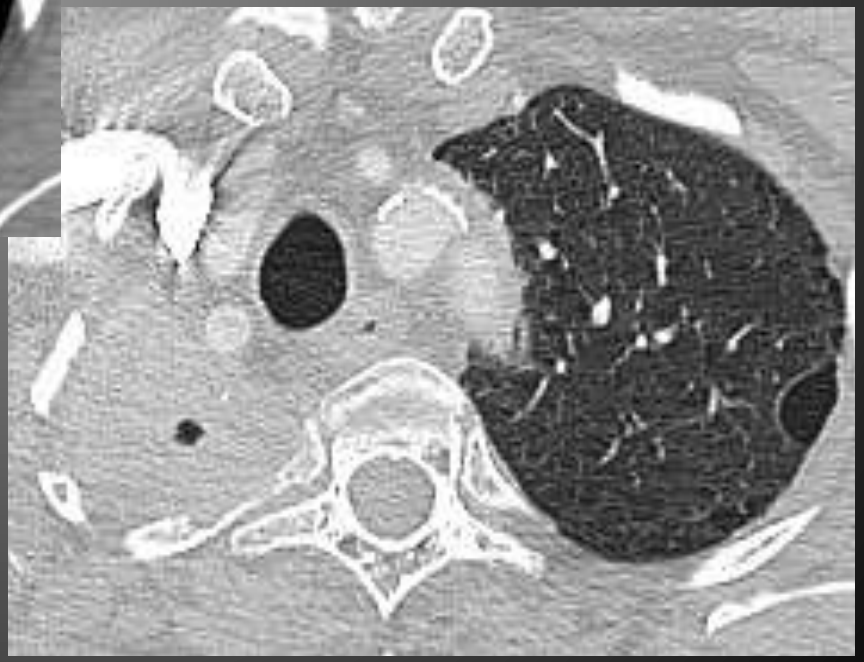

SYNTHESE

- Connaitre les images faussement tumorales
  - Pneumopathie lipidique et atélectasie par enroulement
  - Images infectieuses: régression, donc raisonner sur 2 imageries rapprochées et non sur une image unique
- Respecter les règles RECIST
- Confirmer les rechutes par une histologie
  - Parfois le syndrome tumoral ne traduit pas une rechute (ex tumeur desmoide)