Journée DES Janvier 2023

CLAD
Chronic lung allograft dysfunction

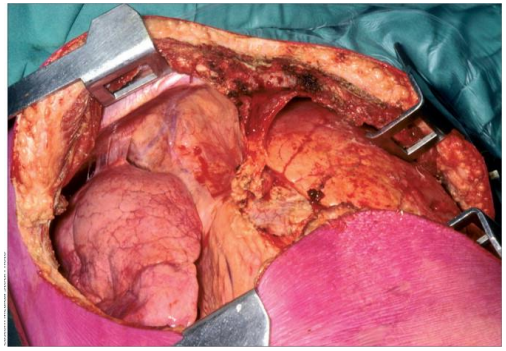

Olivier Brugière,
Hôpital Foch

- Laboratoire d'Immunologie de la Transplantation, Hôp. Saint-Louis, CEA/Institut de Biologie François Jacob

CLAD= Dysfonction chronique du greffon
(= équivalent d'un Rejet chronique en TxP)

- Principal phénotype = bronchiolite oblitérante (BO)
- 80% des CLAD
  - Limite la survie > TxP, 1ère cause de mortalité post-TxP

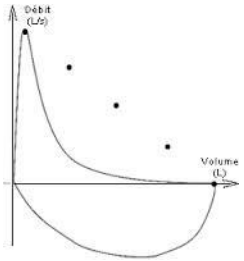

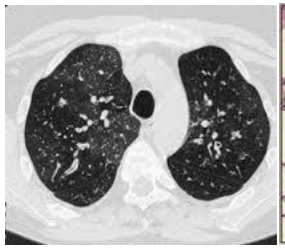
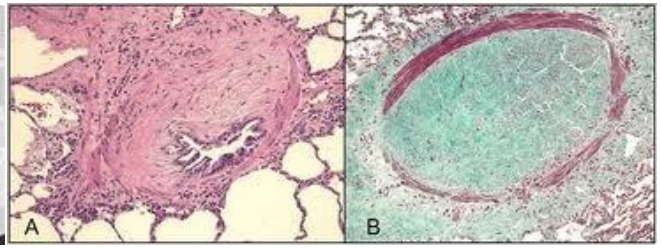

  - Trouble ventilatoire obstructif vers ins. Respiratoire terminale

Freedom from Bronchiolitis Obliterans

For Adult Lung Recipients (Follow-ups: April 1994-June 2002)

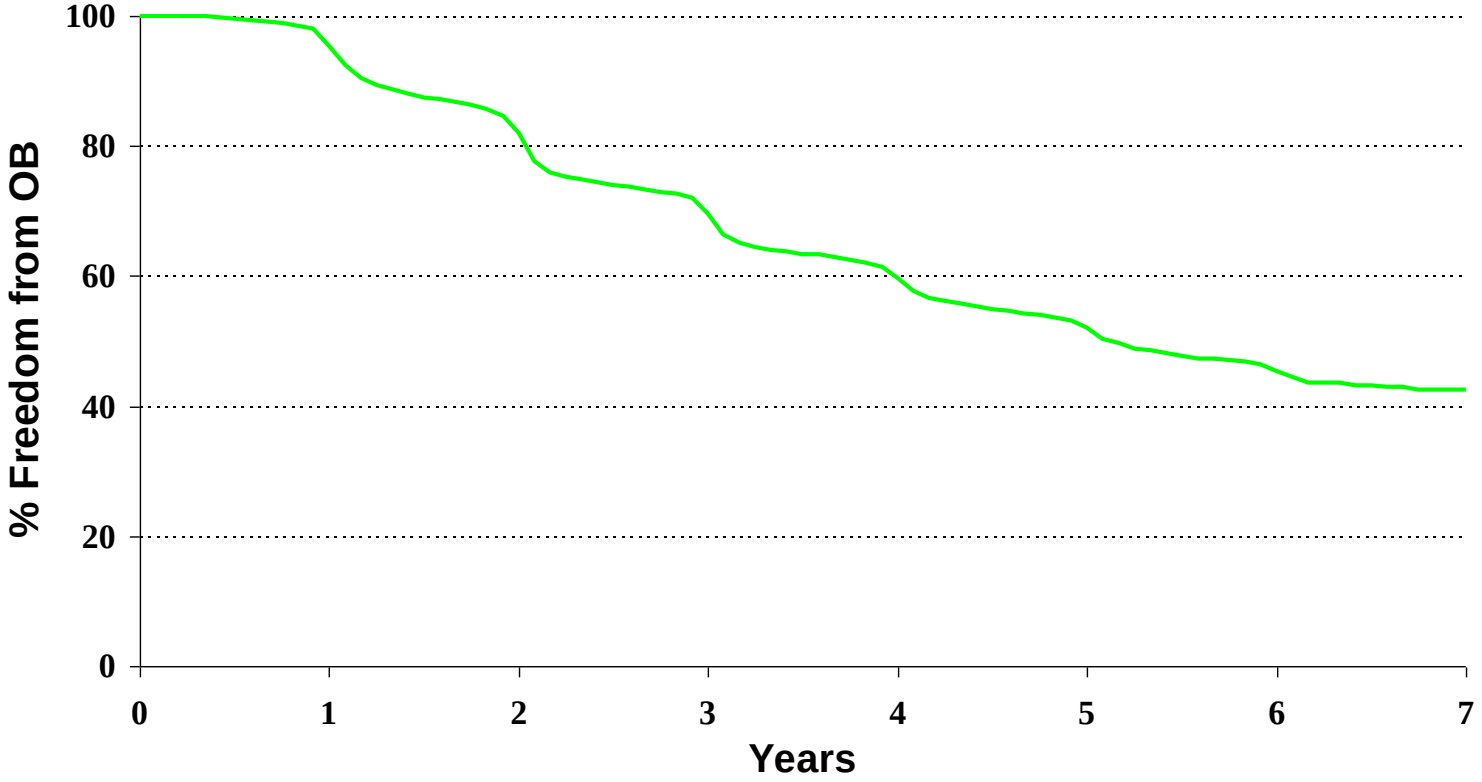

Incidence de la BO: > 50 % à 5 ans post-Tx

Très supérieure au autres Tx d'organes solides

Présentation clinique de la BO post-TxP

Baisse spirométrique isolée

Phase tardive: colonisation/infection

(*Pseudomonas* spp, *Staphylococcus* spp, et *Aspergillus* spp)

Apparition et progression très variable

- Brutal avec déclin rapide du VEMS
- Insidieux avec déclin lent et continu
- Stabilité prolongée après déclin

Le diagnostic histologique n'est le plus souvent pas posé (faible rendement BTB)

BOS : Syndrome de bronchiolite oblitérante: diagnostic fonctionnel de BO

TABLE 1. BRONCHIOLITIS OBLITERANS SYNDROME CLASSIFICATION SYSTEM

2002 Classification	
$FEV_1 > 90\%$ of baseline and $FEF_{25-75} > 75\%$ of baseline	BOS 0
FEV_1 81–90% of baseline and/or $FEF_{25-75} \leqslant 75\%$ of baseline	BOS 0p
FEV_1 66–80% of baseline	BOS 1
FEV_1 51–65% of baseline	BOS 2
$FEV_1 \leqslant 50\%$ of baseline	BOS 3

Diagnostic de BOS: Déclin spirométrique après élimination des autres causes de chute VEMS (RA, complication bronchique, infections, hyperinflation natif, RGO, ..)

Détection précoce BOS

- Spirométrie à domicile
- Nouvelle classification BOS 0-p
- Présence d'une HRB (valeur prédictive)
- Neutrophilie du LBA
- Augmentation du NO exhalé (corrélé au % des neutrophiles au LBA)
- Scintigraphie perfusion (Bonne VPN)
- TDM thorax coupes fines expiratoires (VPN> 90%)

Coupes TDM de BO (Thorax 2006; 61: 799, Scores)

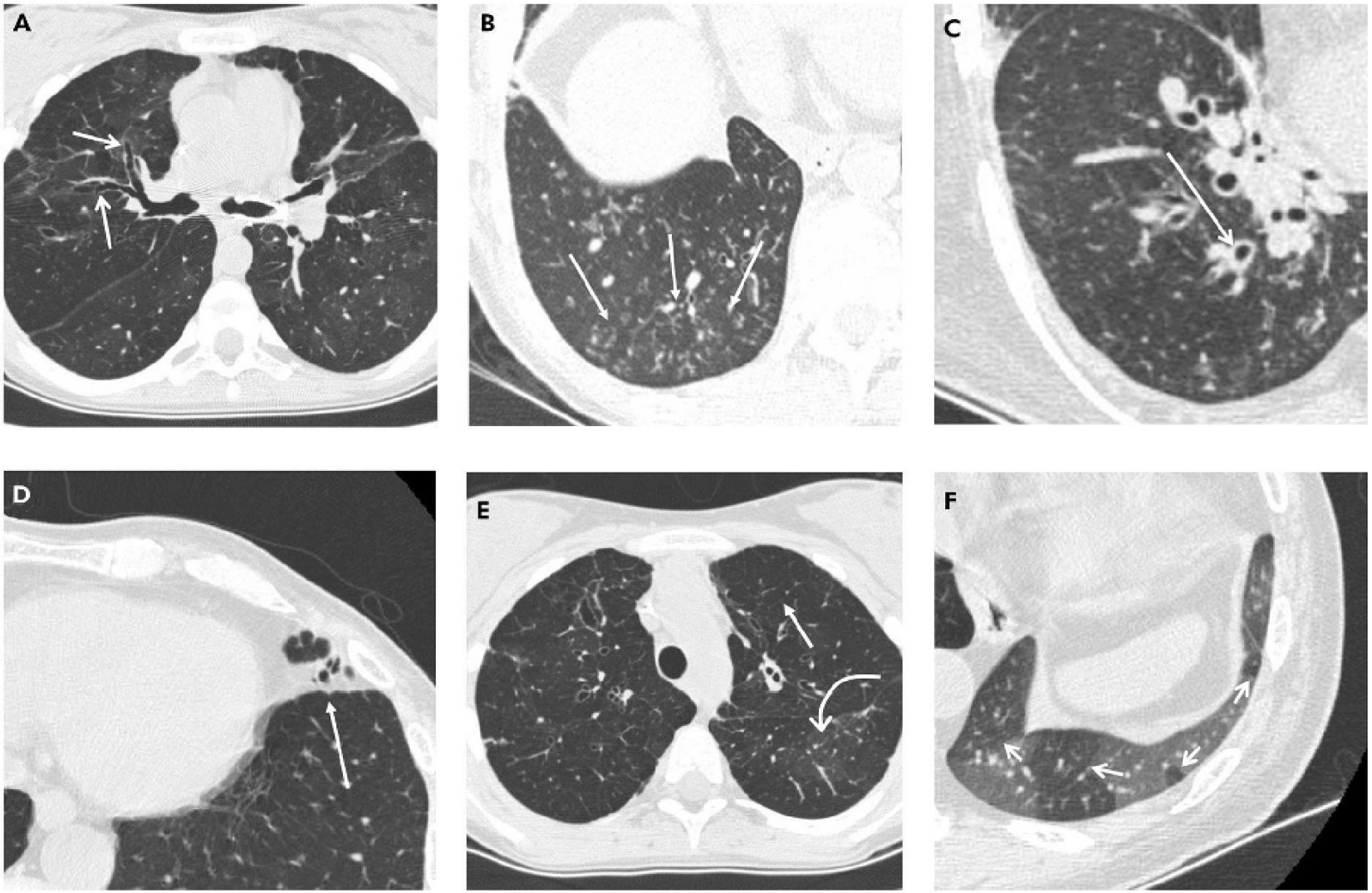

Figure 1 Representative CT images showing the CT_{BO} scoring system abnormalities. A collection of transaxial 1.25 mm CT sections in different patients viewed at lung window and level setting (width 1500 HU, level −500 HU) showing (A) bronchiectasis (arrows) identified by the absence of normal bronchial diameter tapering; (B) peripheral mucus plugging shown as multiple centrilobular nodules (arrows); (C) dilated bronchus with associated wall thickening (arrow); (D) lingular consolidation (arrow) shown as an area of increased density obscuring the underlying pulmonary vasculature; (E) generalised mosaic pattern in both upper lobes shown by areas of decreased attenuation and vessel size (straight arrow) compared with regions of normal attenuation and normal vessel size (curved arrow); and (F) expiratory image showing areas of air trapping (arrows).

Physiopathologie de la BO

Lésions de l'épithélium et prolifération/différentiation lymphocytaire (1) → **Fibroprolifération**

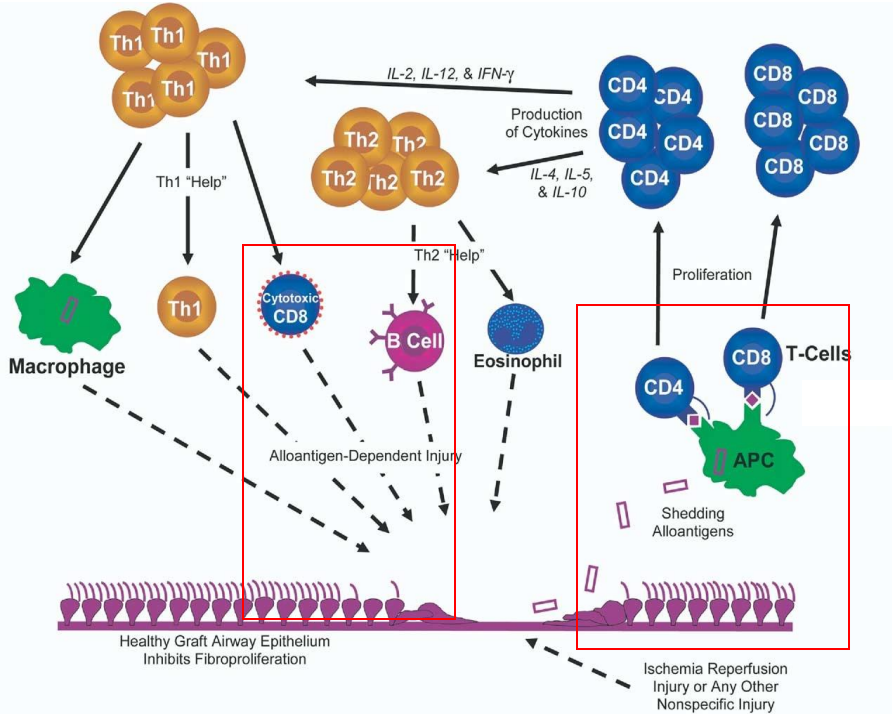

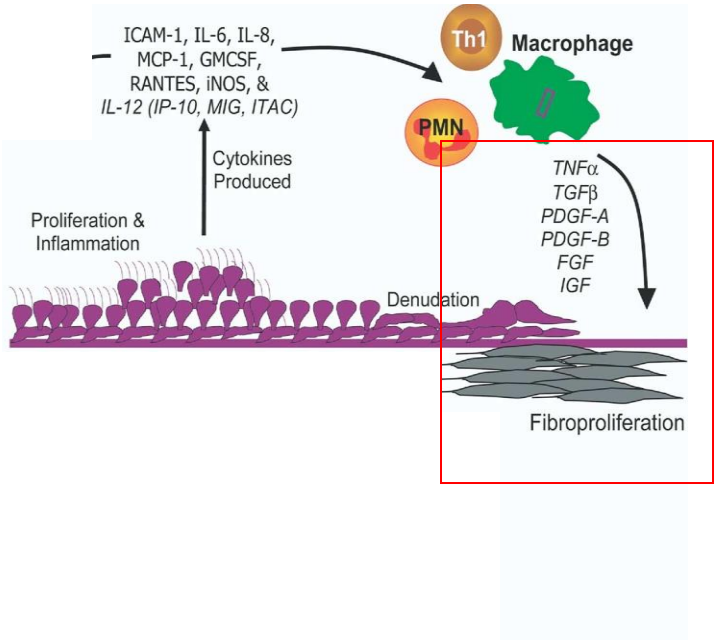

- Autres voies : Axe TH-17, /l'IL-17/neutrophilie alvéolaire

(1) Neuringer 2005

Pathogénie BO (études humaines)

Rôle de la réponse allogénique T

BO: maladie rare

Prévalence élevée en TxP et Tx moelle osseuse (BMT)

= aspect histologiques (1) (BO et fibroelastose) et TDM similaires

= alloréactivité commune aux 2 Tx

= BMT: Tx stem cells déplétées en Ly T= BO moindre (2)

myofibroblasts surrounded by intraalveolar collagen (arrows)
areas with dense aggregates of macrophages (stars)
elastosis of the alveolar walls is apparent throughout (arrowheads)

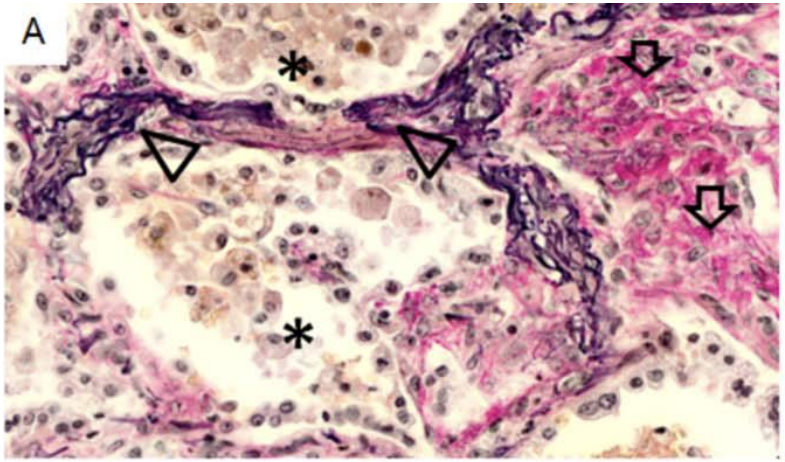

(1) Jonicg D, 2017; (2) Huysman C. 2006

Facteurs de risque de BO

Alloimmuns

- Rejet aigu cellulaire (A)
- Rejet aigu bronchiolaire (B)
- Mismatch HLA donneur/receveur
- AC anti-HLA/ Rejet aigu humoral ?

Non alloimmuns

- Pneumopathie à CMV
- Dysfonction primaire du greffon
- Virose respiratoire non CMV
- RGO

FdR immun: Rejet aigu cellulaire

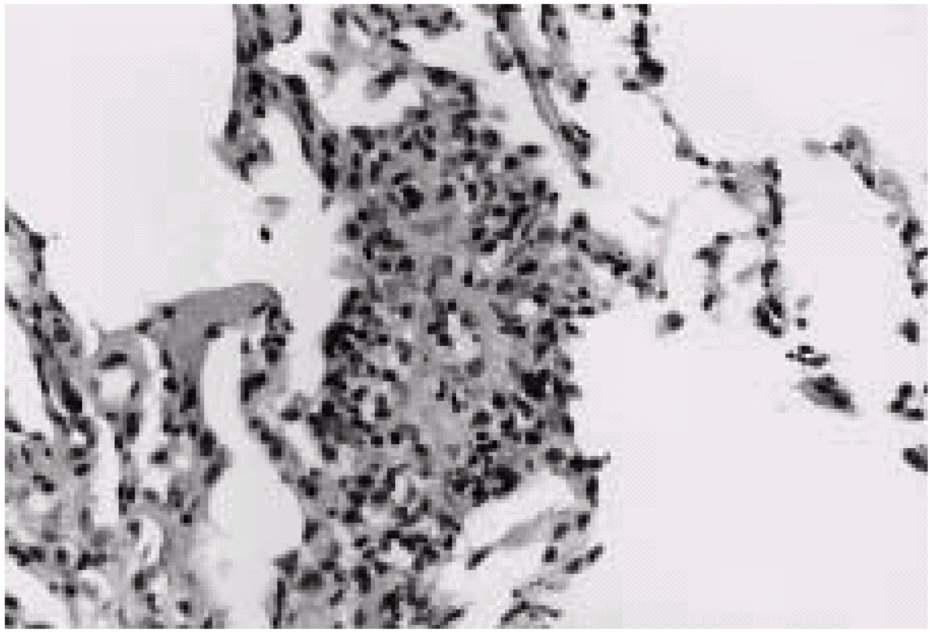

Fig. 2. – A dense perivascular infiltrate of mononuclear cells including small and large lymphocytes and macrophages with intimitis. The infiltrate does not extend into adjacent alveolar walls and the alveolar spaces are clear. Grade A2 acute rejection. Haematoxylin and eosin.

FdR immun
RA bronchiolaire
= Bronchiolite lymphocytaire

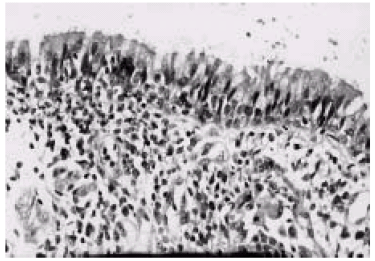

Fig. 5. – Bronchiolar mucosa showing a diffuse infiltrate of lymphocytes in subepithelial tissue and
epithelium itself. The ciliated respiratory epithelial cells are intact with no evidence of ulceration or n
Grade B2 acute airways rejection. Haematoxylin and eosin.

- Sévérité de la bronchiolite Lymphocytaire corrélée L'incidence de la BO

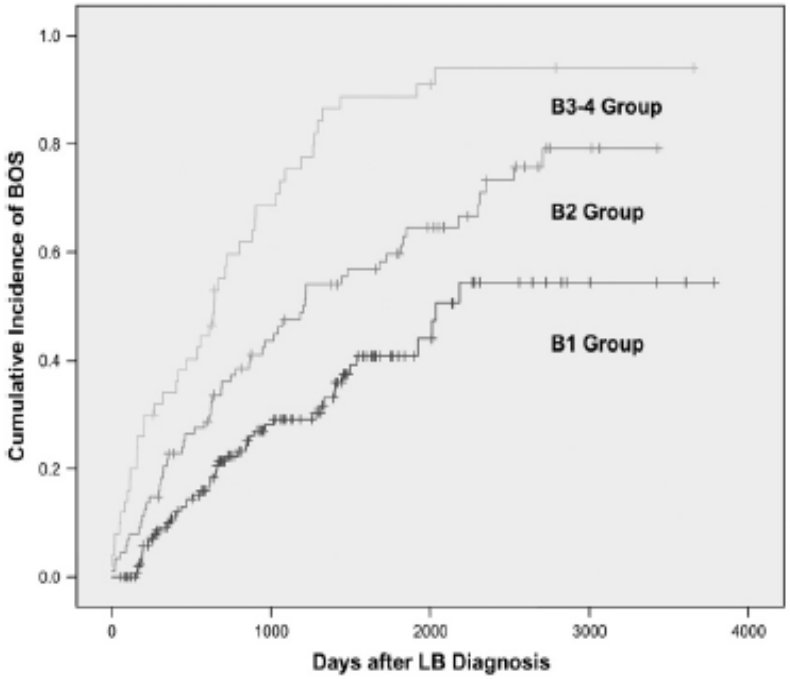

Figure 4. Kaplan-Meier curves showing cumulative incidence of bronchiolitis obliterans syndrome (BOS) stage ≥ 1 in lung transplant recipients, 1995–2005, is significantly associated with highest grade of lymphocytic bronchiolitis (LB) (B grade) on transbronchial biopsy. Model $\chi^2 = 48.20$, $P < 0.001$, log-rank; B1 versus B2, $P = 0.002$, log-rank; B1 versus B3–4, $P < 0.001$, log-rank; B2 versus B3–4, $P < 0.001$, log-rank.

Glanville 2008; 177: 1033

FdR immun
Mismatching HLA

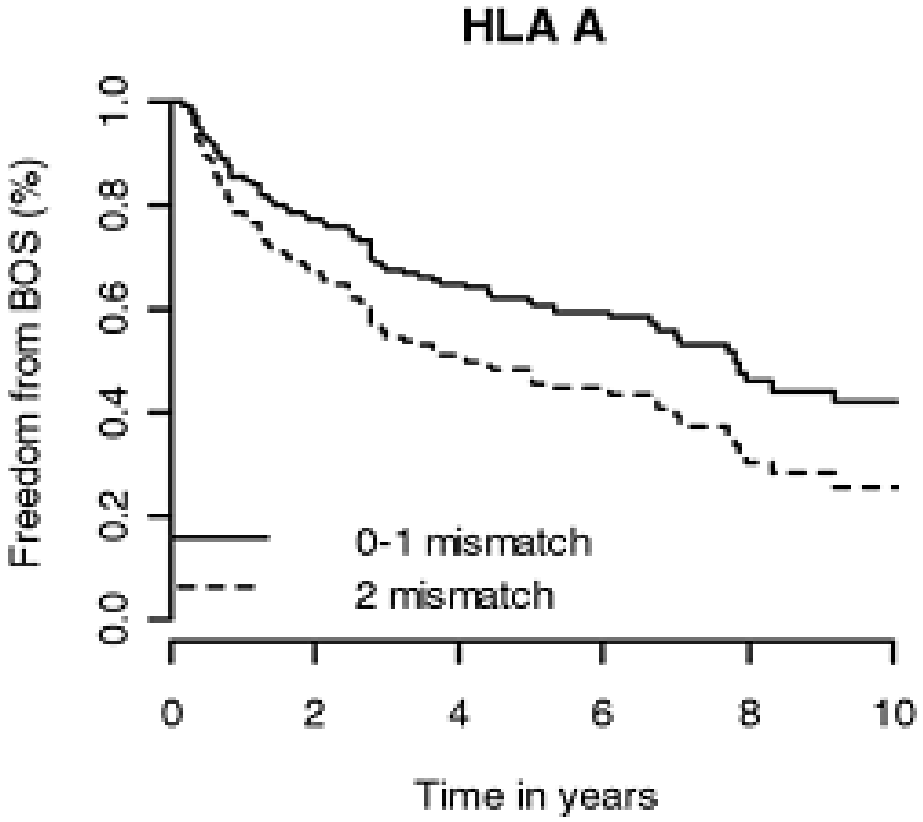

JHLT 2008

FdR immun: Immunité humorale= DSA (anti-HLA donor-specific antibodies)

2013 **Lung Transplantation in Patients with Pretransplantation Donor-Specific Antibodies Detected by Luminex Assay**

Olivier Brugière,[1,4] Caroline Suberbielle,[2] Gabriel Thabut,[1] Elodie Lhuillier,[1] Gaelle Dauriat,[1]

The Transplantation Society

2016 **De-novo donor-specific anti-HLA antibodies 30 days after lung transplantation are associated with a worse outcome**

Jérôme Le Pavec, MD, PhD,[a,b,c] Caroline Suberbielle, MD,[d] Lilia Lamrani,[a,c]

The Journal of Heart and Lung Transplantation

2016 **Antibody-Mediated Rejection in Lung Transplantation: Clinical Outcomes and Donor-Specific Antibody Characteristics**

A. Roux[1,2,3,*], F. Parquin' on behalf of the Foch Lung Transplantation Group

2106 Tikkannen J, AJRCCM
Détection et persistance des DSA classe II type DQ

→ Apparition ultérieure d'une BOS

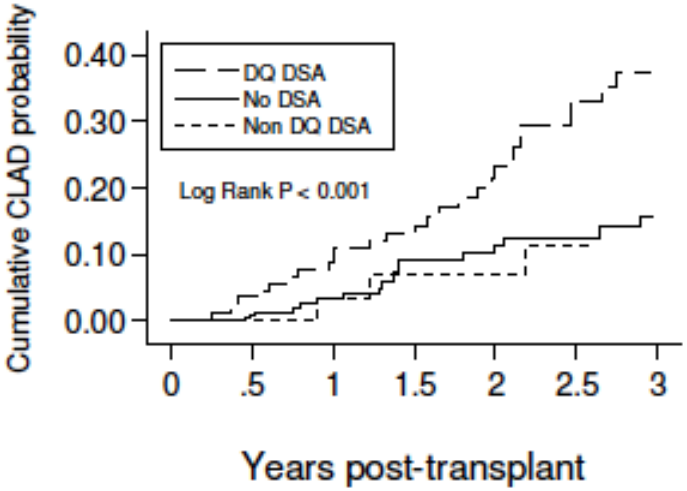

Antibody-Mediated Renal Allograft Rejection: J Am Soc Nephrol 2007
Développement des lésions

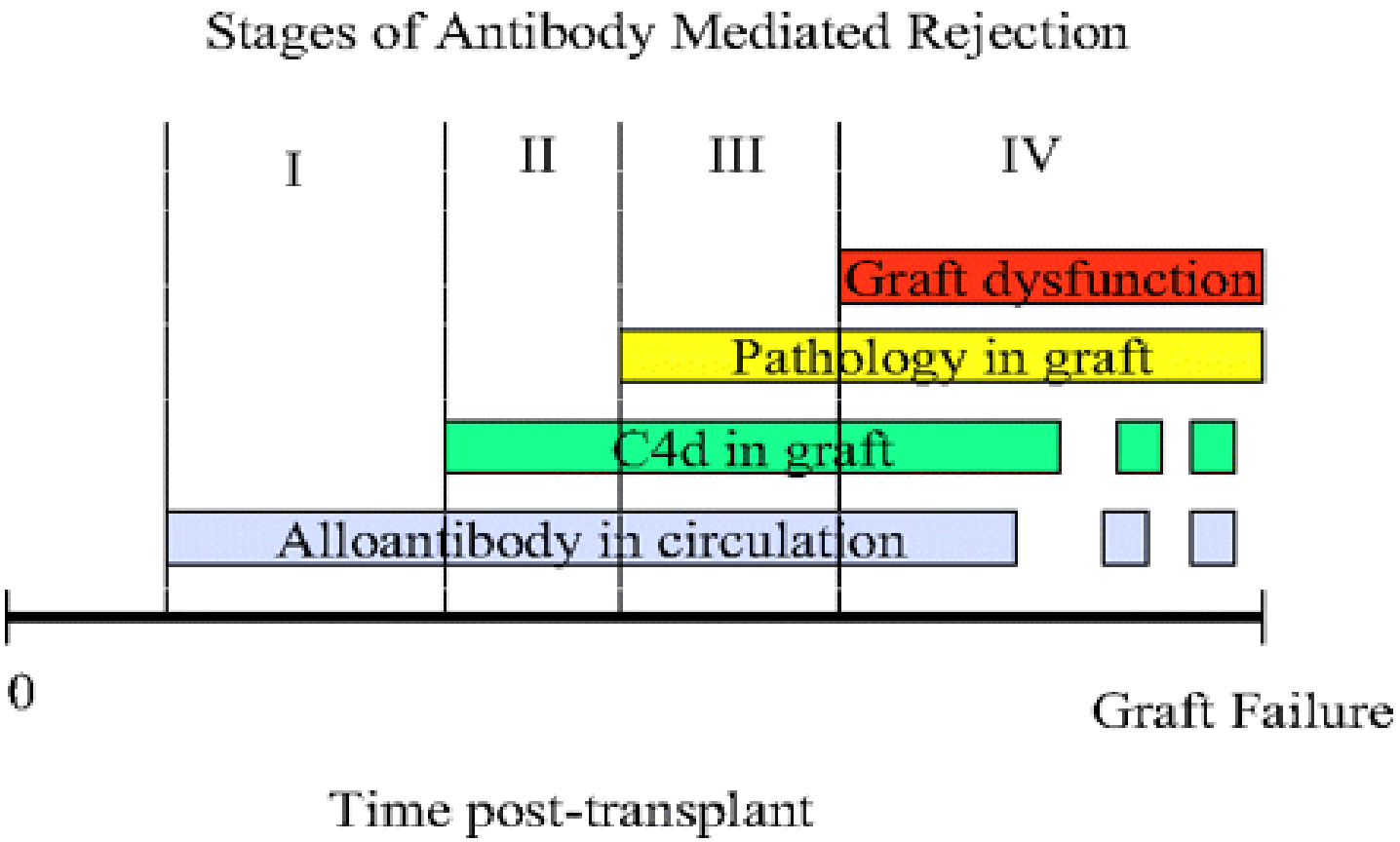

FdR non immun
= Dysfonction primaire du greffon

-PGD : dysfonction primaire du greffon sévère (grade 3)

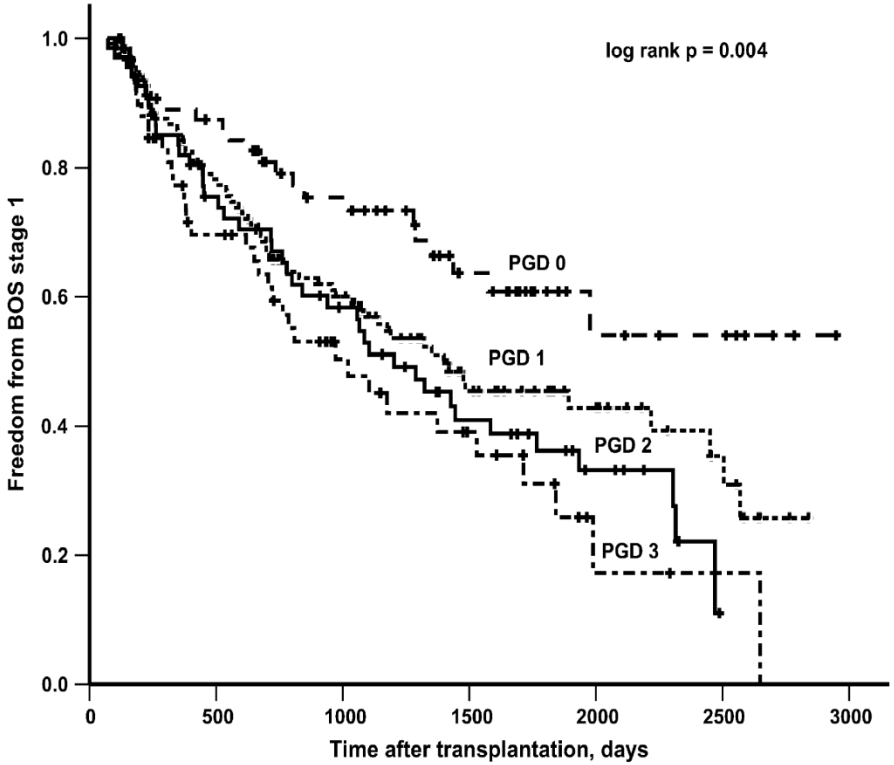

PGD 0, n =	65	39	8	0
PGD 1, n =	125	60	17	0
PGD 2, n =	68	32	10	0
PGD 3, n =	62	19	2	0

Figure 1. Recipients who did not have primary graft dysfunction (PGD grade 0) had significantly higher freedom from bronchiolitis obliterans syndrome (BOS) stage 1 than those who had any grade of PGD (log rank, p = 0.004).

Daud AJRCCM 2007; 175: 507

FdR non Immun:
infection CMV ?
(à l'ère des prophylaxies anti-CMV)

CMV pneumonia n = 151
No CMV pneumonia n = 190

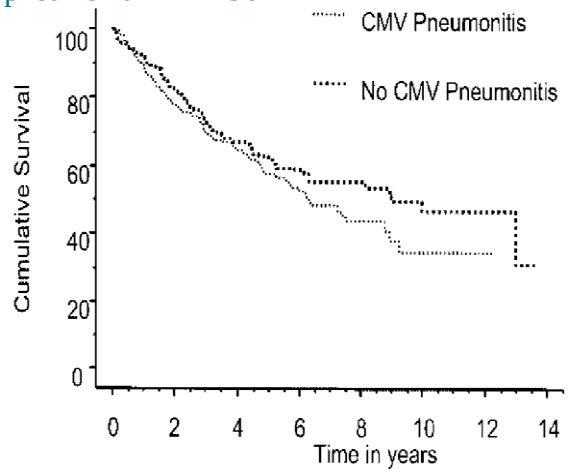

Figure 1. Cumulative survival in patients with and without cytomegalovirus (CMV) pneumonitis.

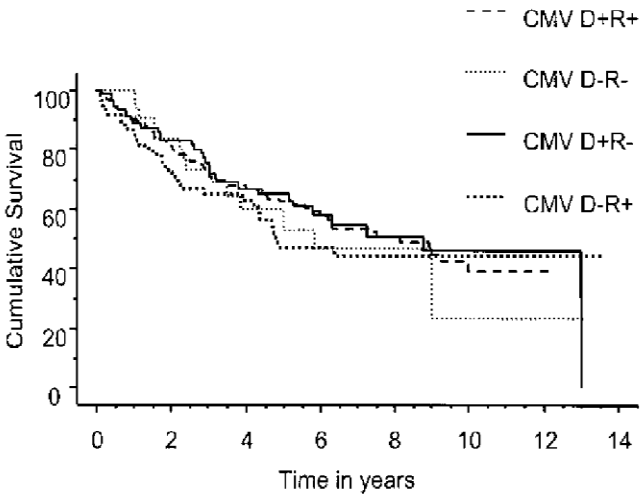

Figure 3. Cumulative survival in various CMV serogroup combinations.

Tamm AJRCCM 2004: 170; 1120

FdR non immun:
Viroses respiratoires communautaires: CARV

Virus communautaires
VRS, rhinovirus
Parainfluenzae
Influenzae,
Adénovirus.

Any CARV
risk to leading to BOS 3
HR = 3.6

Lower respiratory CARV
risk to leading to BOS 3
HR = 4.2

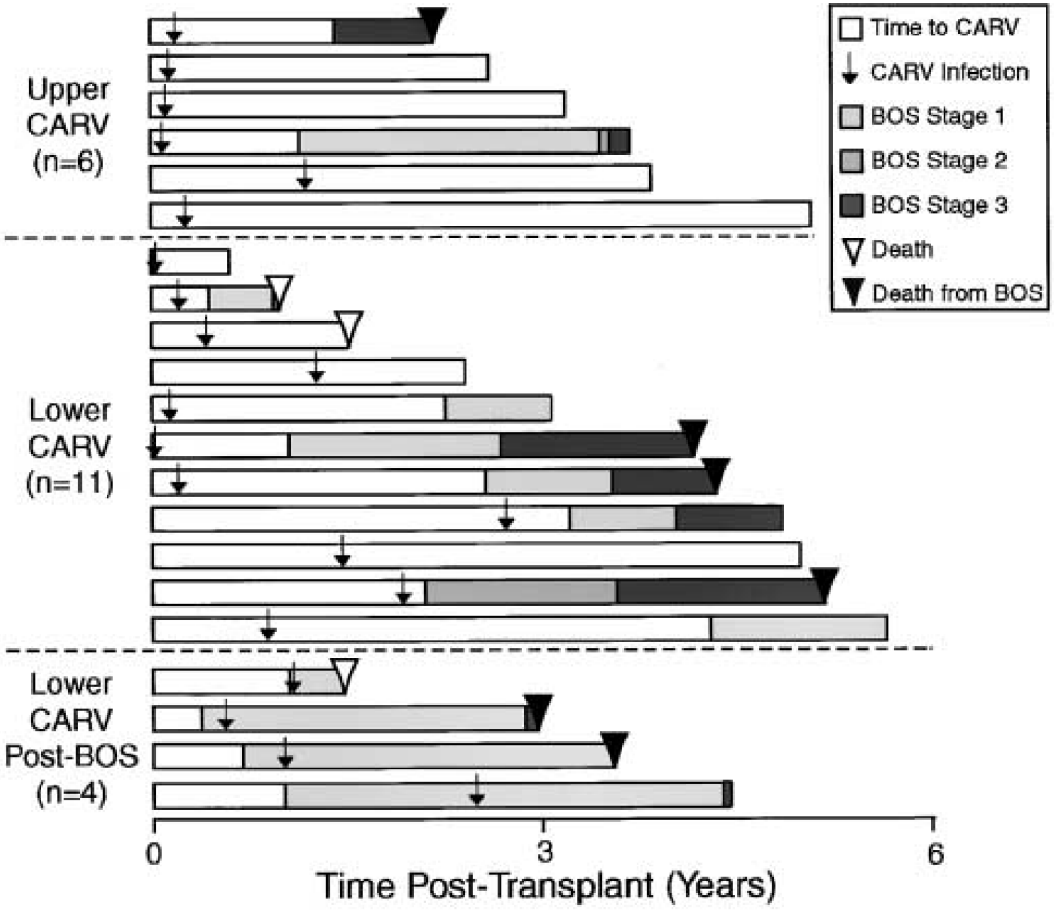

Khalifa AJRCCM 2004; 170: 181.

FdR non immun
Reflux gastro-oesophagien acide et non acide

Gastroesophageal Reflux as a Reversible Cause of Allograft Dysfunction After Lung Transplantation*

Scott M. Palmer, MD; Ara P. Miralles, RN, BSN;

(CHEST 2000;

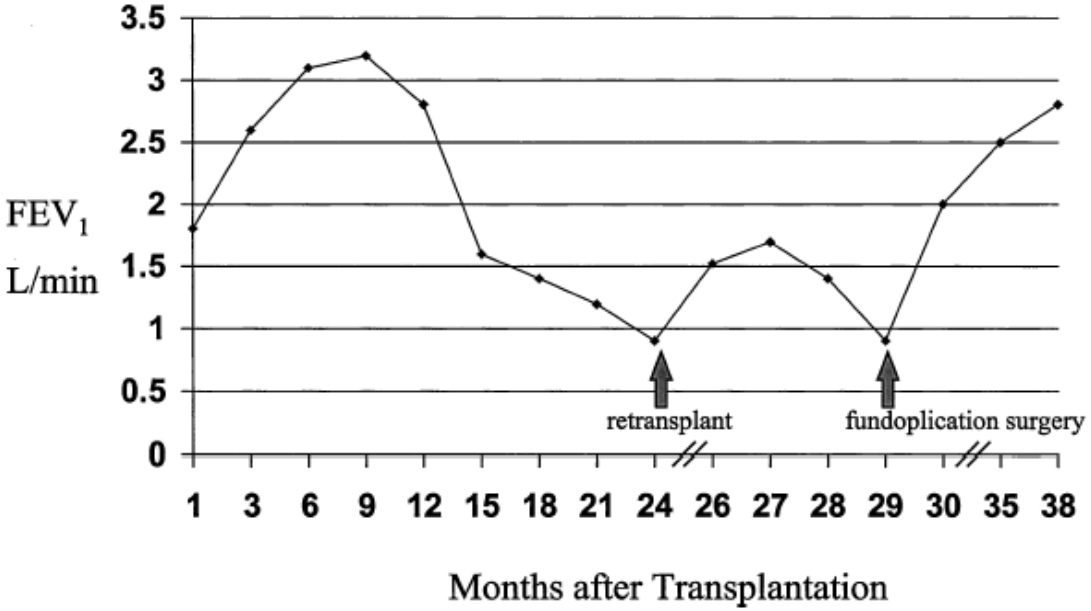

FIGURE 1. Lung function before and after fundoplication.

Concentration acides biliaires ds LBA patients BO > patients non BO *. P <0,05
ERJ 2008

Traitement de la BOS: 1- Azithromycine

A randomised controlled trial of azithromycin therapy in bronchiolitis obliterans syndrome (BOS) post lung transplantation

Paul A Corris,[1,2] Victoria A Ryan,[3] Therese Small,[1] James Lordan,[1] Andrew J Fisher,[1,2] Gerard Meachery,[1] Gail Johnson,[1] Chris Ward[2]

Thorax 2015;

Efficacité AZI
= 39% avec VEMS>10% bras AZI versus 0% bras placebo (p=0.002)

= effet anti-IL8
= inhibe neutrophilie alvéolaire

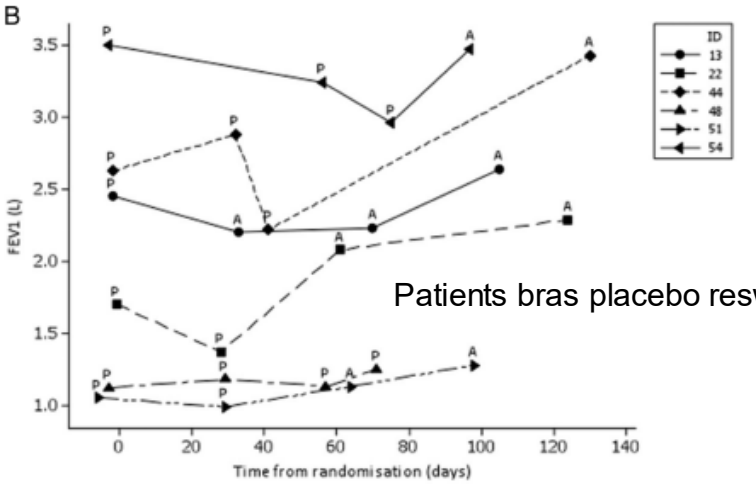

Patients bras placebo reswitchés à l'AZI

AZI
- Permet d'identifier les ARAD, « azithromycine reversible acute dysfunction »
- Permet de poser diagnostic de BOS si persistance du déclin

Traitement de la BOS: 2- PCE

extracorporeal photopheresis in patients with bronchiolitis obliterans syndrome after lung transplantation

Peter Jaksch, MD,[a] Axel Scheed, MD,[a] Maya Keplinger, MD,[a] Mai-Britt Ernst, MD,[a]

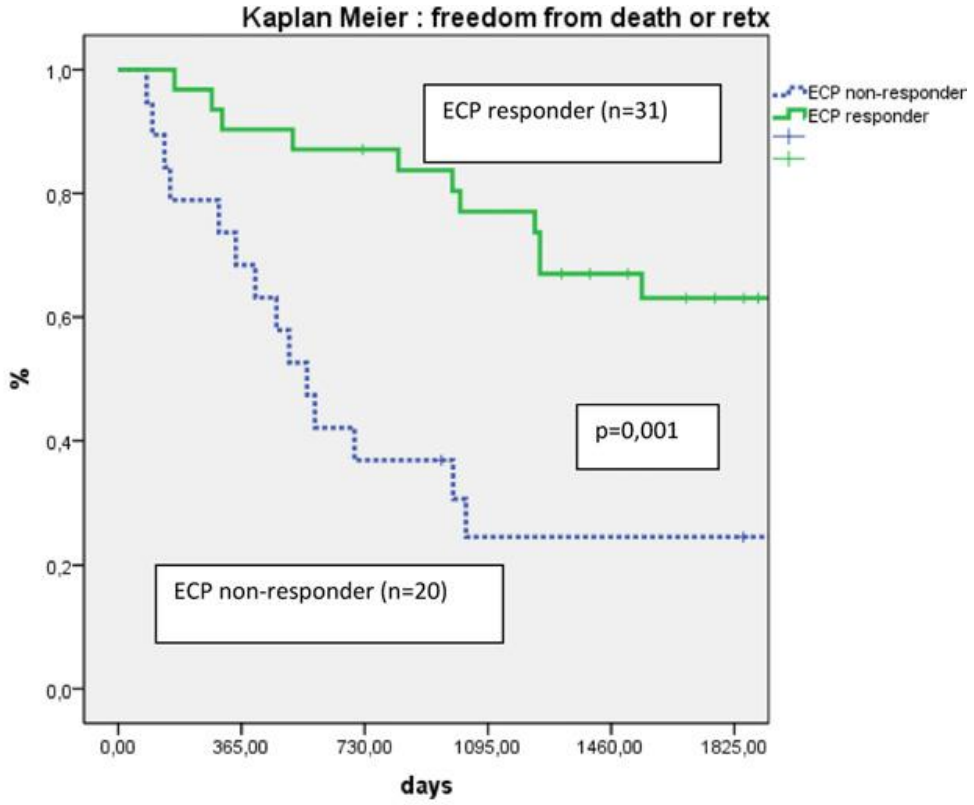

Freedom from death or retx after start of BOS ≥1

ECP responder (n=31) vs. ECP non-responder (n=20)

J Heart Lung Transplant 2012;31:950–7

Traitement de la BOS:
3- Traitement de l'AMR infra-clinique ?

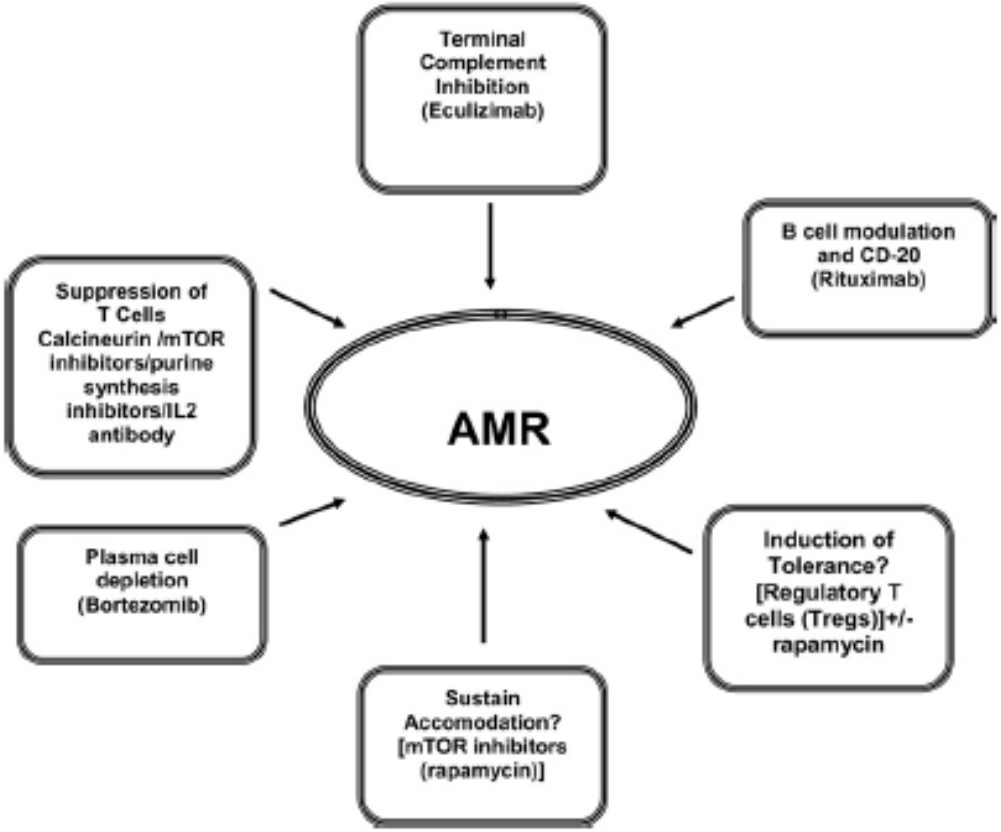

Figure 1 Possible approaches for treatment of AMR.

Pathogénie BO (études humaines)

= Rôle de la Fibrose de l'épithélium

Cathepsin B promotes collagen biosynthesis driving Bronchiolitis Obliterans Syndrome

2021

Carmela Morrone, Natalia F. Smirnova, Aicha Jeridi, Nikolaus Kneidinger, Christine Hollauer, Jonas Christian Schupp, Naftali Kaminski, Dieter Jenne, Oliver Eickelberg, Ali Önder Yildirim

Please cite this article as: Morrone C, Smirnova NF, Jeridi A, *et al*. Cathepsin B promotes collagen biosynthesis driving Bronchiolitis Obliterans Syndrome. *Eur Respir J* 2020; in press

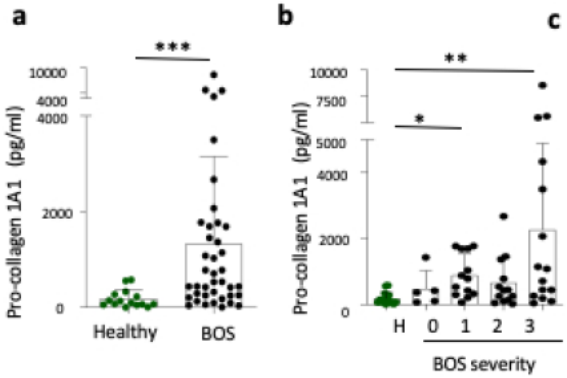

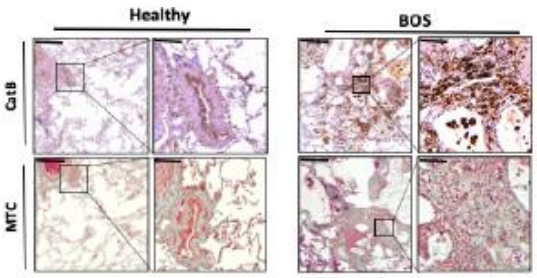

Cathepsin B and Collagen expression increase in bronchiolitis obliterans syndrome

Traitement de la BOS:
4- Médicament anti-fibrosant ?

INFINITx-BOS

Essai multicentrique, randomisé double aveugle contre placebo, évaluant l'efficacité du Nintedanib dans le traitement du Syndrome de Bronchiolite Oblitérante (BOS) de grade 0p-1-2 chez les patients transplantés pulmonaires

Ouverte début 2020
8 centres participants: Foch, Bichat, Marie-Lannelongue, HEGP/Cochin, Bordeaux, Marseille, Grenoble, Strasbourg

Prise en charge BOS en 2023

- **Azithromycine/** Montelukast
- Cure chirurgicale de RGO
- Modification de l'IS
  - Switch CsA-Prograf; ou Aza-MMF/ Inh mTOR **Sirolimus / Everolimus** ?
  - Bolus de solumédrol/SAL/Alemtuzumab/ Belatacept?
- IS inhalés: Stéroides inhalés, (CsA aérosol)
- Traitement des AMR infra-cliniques (rejet humoral DSA)
- Photophérèse extra-corporelle
- Anti-fibrosant
- **Patients sélectionnés: ReTx pulmonaire**

2è Phénotype CLAD = Restrictif

RAS= Restrictive allograft syndrome

Table 1 Definition of Restrictive Allograft Syndrome

Criterion	
1	Persistent ≥20% decline in FEV_1, compared with baseline
2	Concomitant ≥10% decline in TLC, compared with baseline
3	Persistent opacities on chest imaging

Critères 2019: (1) Glanville AR, JHLT 2019.

Restrictive allograft syndrome (RAS): A novel form of chronic lung allograft dysfunction (CLAD). J Heart Lung Transplant 2011

CLAD : (FEV1 < 80% baseline).

BOS : no restrictive changes

RAS = CLAD + TLC to 90% of baseline.

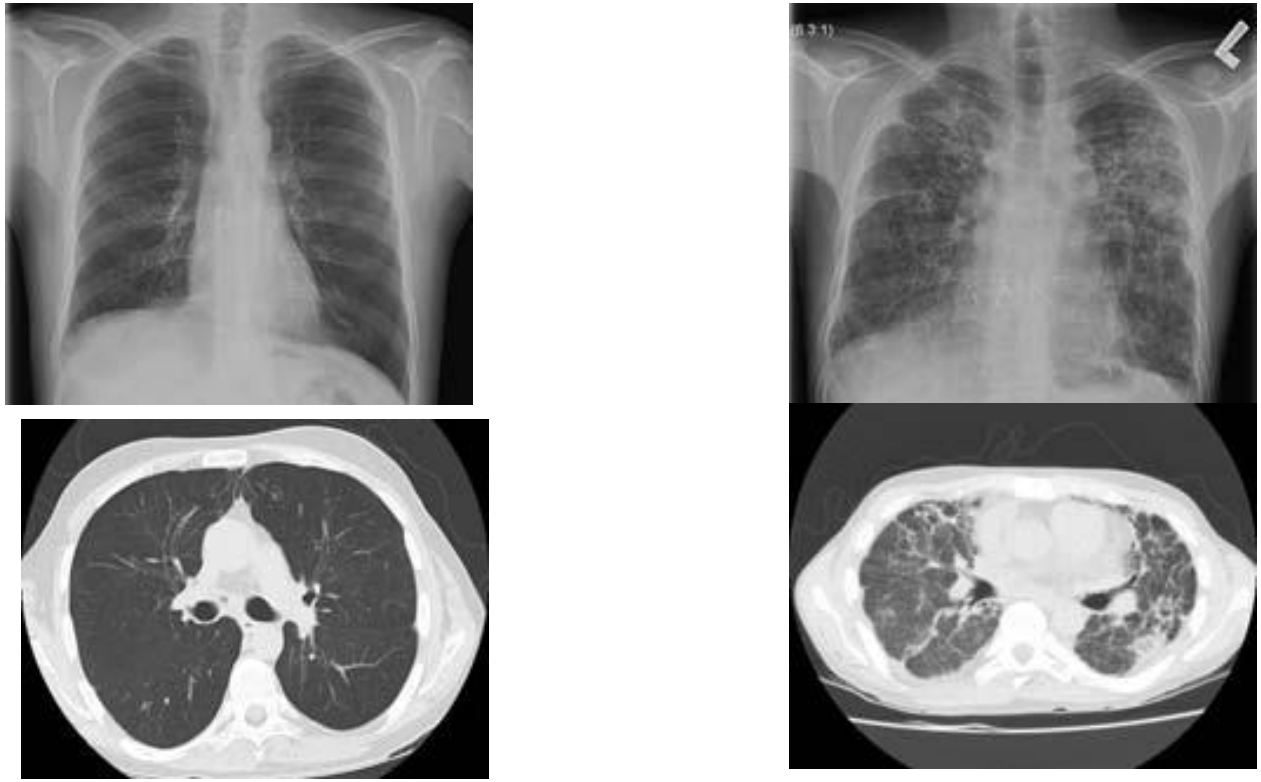

Images réticulaires interstitielles sur RP et TDM
+ consolidation sur TDM

Figure 4 Examples of histologic and radiographic findings of patients with bronchiolitis obliterans syndrome (BOS) and restrictive allograft syndrome (RAS). Chest X-ray and computed tomography (CT) scan of the same patients as in panels A and B taken toward the end of observation. A patient with BOS shows hyper inflated lungs with minimum interstitial infiltration. A patient with RAS shows m ultiple interstitial reticular shadows in both chest X-ray and CT scan. Some consolidation and small lung volume are also observed in the CT scan.

Rejet chronique restrictif:

RAS: A novel form of CLAD) (1) environ 20% des CLAD

Histologie pleiomorphe (2)

- pleuroparenchymal fibroelastosis (PPFE) =90%
- Bronchiolitis obliterans (BO) 50%
- Diffuse alveolar damage
- Fibroblastic foci (37%)

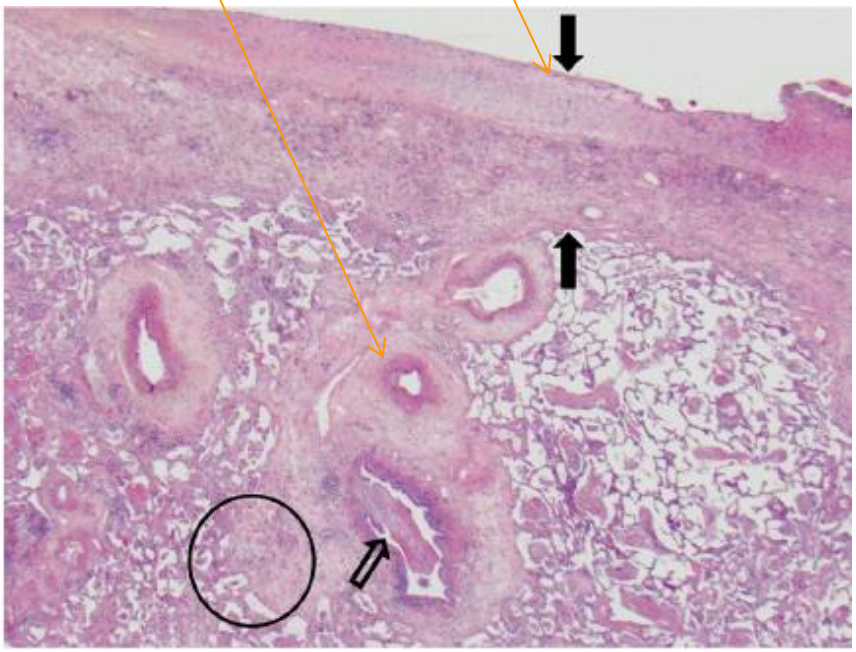

(1) Sato. J Heart Lung Transplant 2011

(2) Ofek E, 2013

Pronostic vital du RAS vs BOS

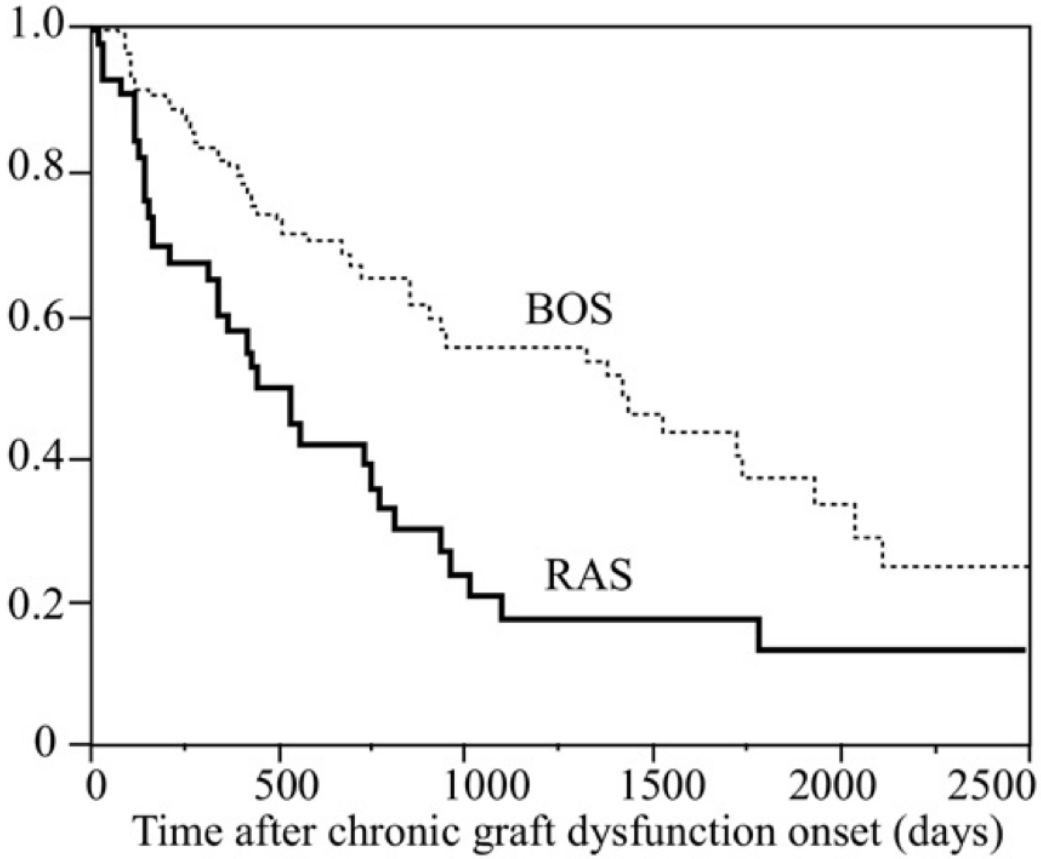

Sato, M. 2011. JHLT

Rejet chronique restrictif
Quel traitement pour le RAS ?
= Fibro-élastose pleuro-parenchymateuse post-TxP

- Majoration IS (bolus solumédrol, thymoglobuline)= décevant
- Traitement anti-fibrosant ?

1- Pirfinidone (2013)

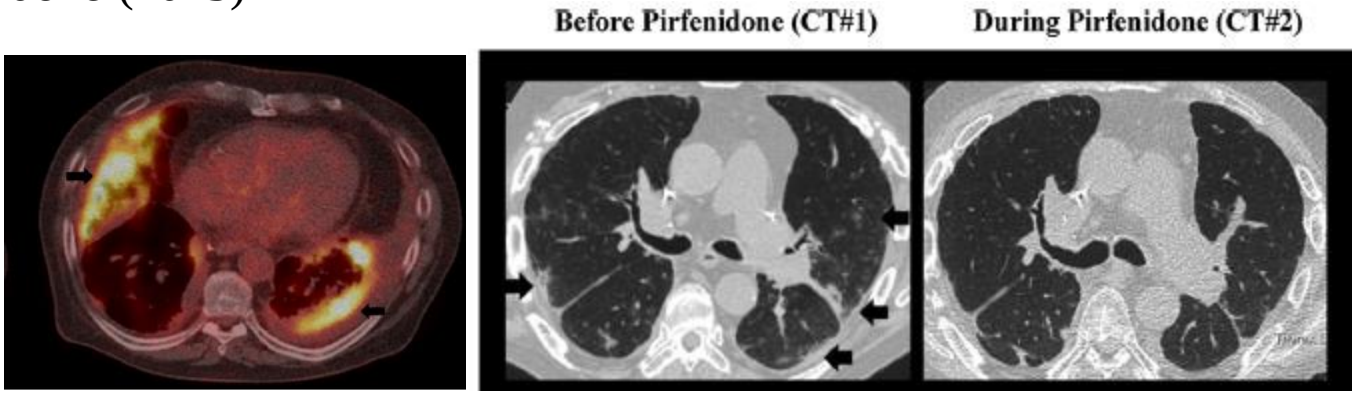

2- Nintédanib (2016)

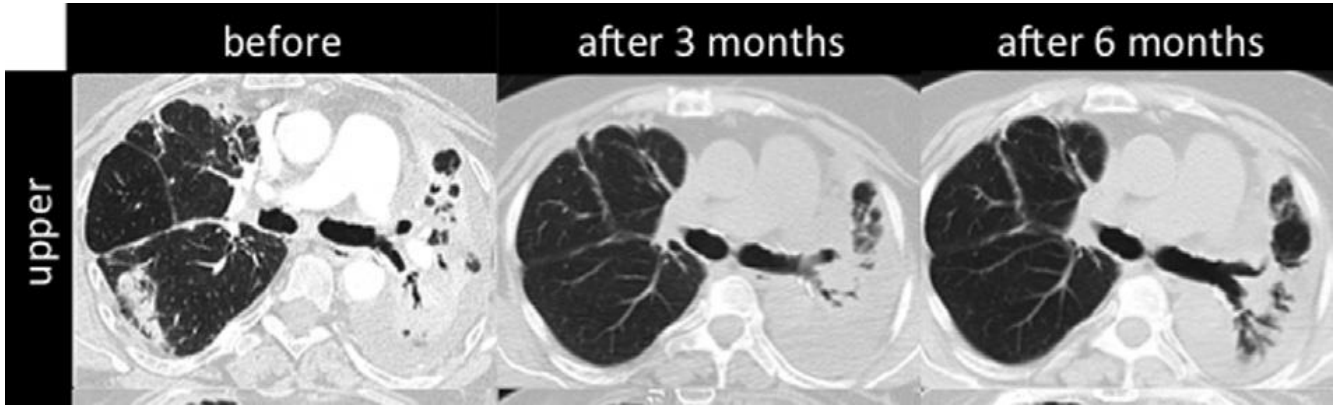

(1) Vos R. AJT 2013; (2) Suhling H. JHLT 2016

Bronchiolitis Obliterans Syndrome : The Final Frontier for Lung Transplantation

Jamie L. Todd and Scott M Palmer

2011

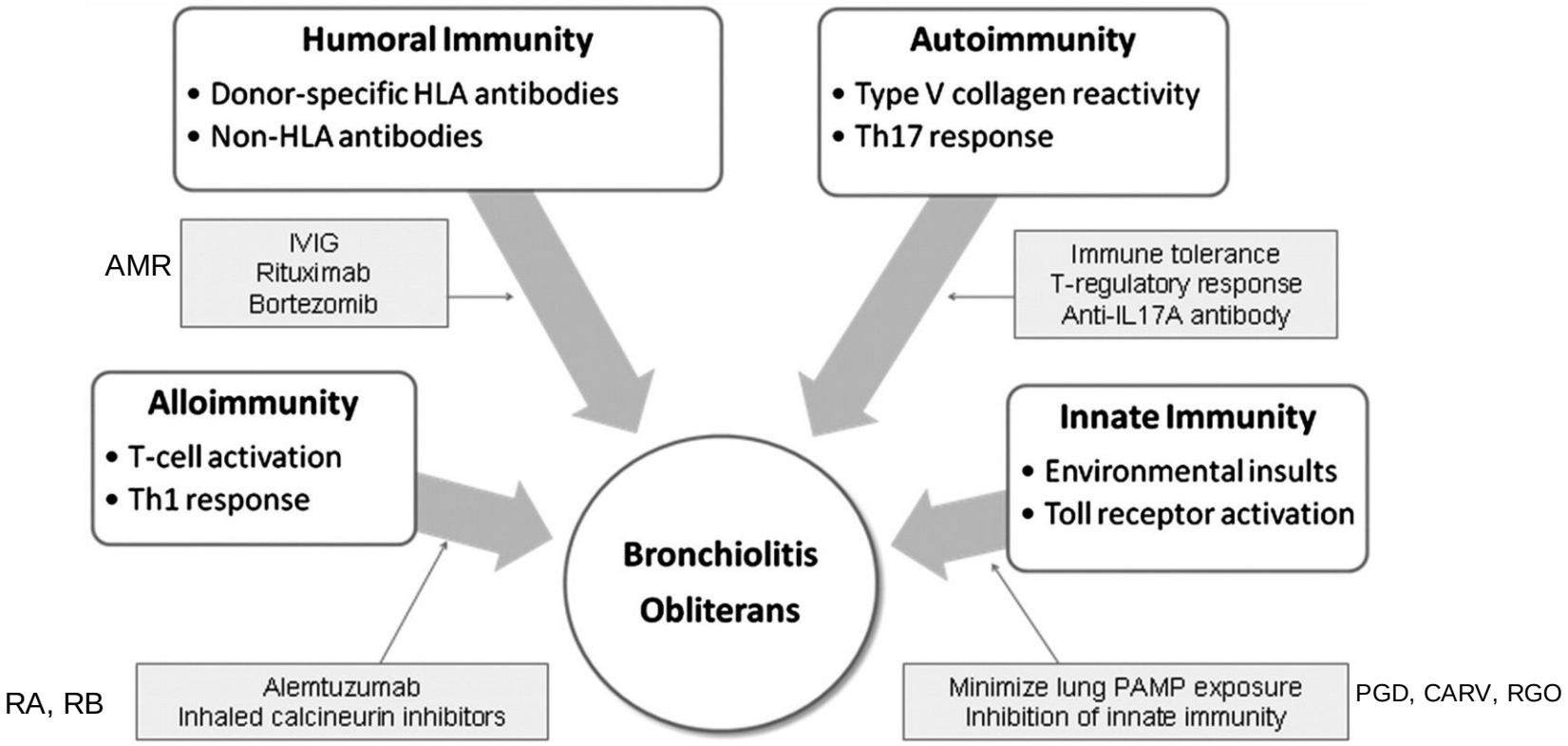

Take-home messages

- CLAD = Talon d'Achille de la Tx
  = 1ère cause de mortalité post-Tx
- Principal phénotype: BO
- Pas de traitement validé
- Nombreuses pistes de traitements
  - PCE
  - AMR infraclinique
  - Anti-fibrosants

Merci pour votre attention

Service Pneumologie et Transplantation Pulmonaire:
Antoine Roux, Clément Picard, Sandra de Miranda, Dominique Grenet, Abdulmonem Hamid, Laurence Beaumont, Sylvie Colin de Verdière, Charlotte Roy.

Service de Chirugie Thoracique:
Edouard Sage, Matthieu Glorion, Ciprian Pricopi, Julien De Wolf

Service de Réanimation Chirurgicale
Francois Parquin, Elise Cuquemelle, Benjamin Zuber, Charles Cerf

Service anatomopathologie:
Elisabeth Longchamps

U1152, DHU Fire, Paris

Service de Recherche en Hemato-Immunologie (SRHI),
Nathalie Rouas-Freiss
Edgardo D. Carosella

Identification précoce du RAS

Opacités évocatrices de RAS souvent en avance sur déclin CPT et/ou CV (2)

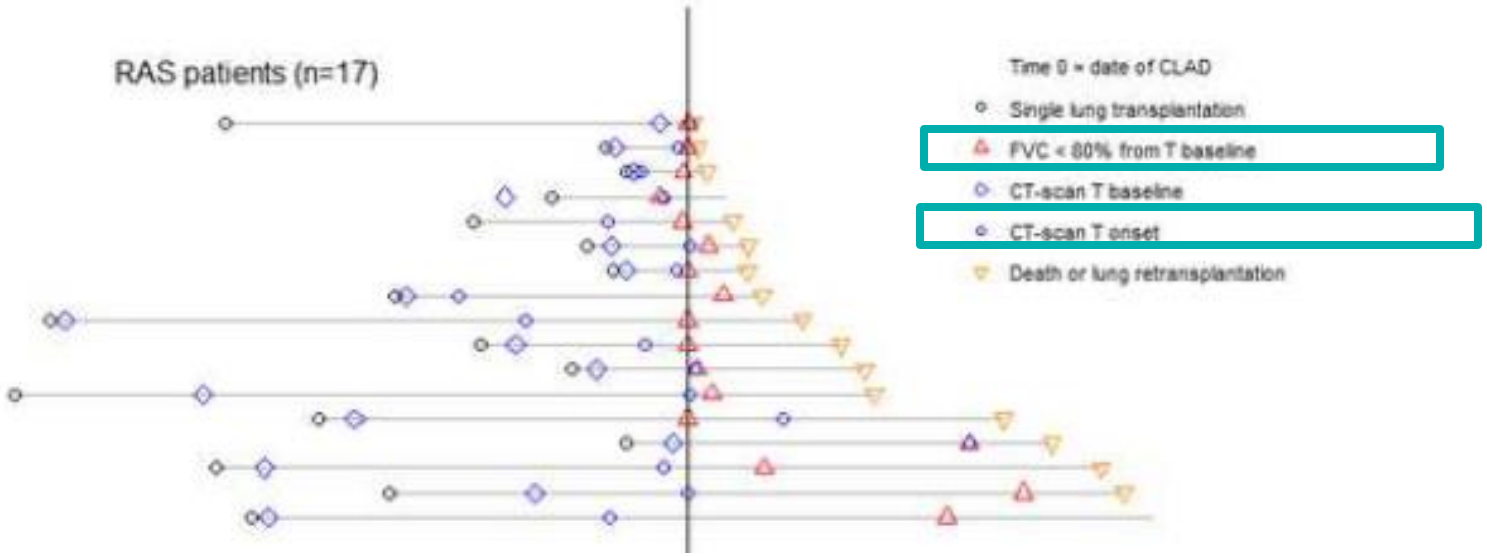

(1) Glanville AR, JHLT 2019. (2) Philippot Q, Brugière O. JHLT 2020

BO: Histopathologie

Steward et al. JHLT 2007

Obliterative bronchiolitis (C)

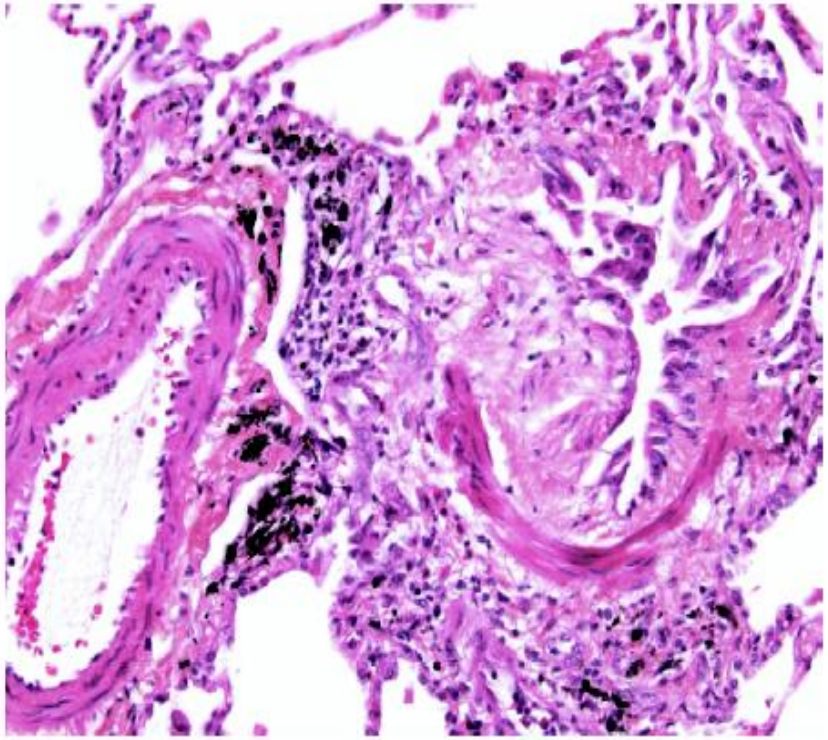

Figure 22. Obliterative bronchiolitis. In this transbronchial biopsy, an eccentric polypoid plaque of dense eosinophilic scar tissue is superimposed between attenuated respiratory epithelium and the smooth muscle wall of the airway. Such focal scarring of the airways is classified as obliterative bronchiolitis. H&E.

Causes de mortalité après Tx pulmonaire, selon période post-Tx. ISHLT,1992-2002.

Cause of death	Time of death		
	>1 year to 3 years (*N* = 1,096)	>3 years to 5 years (*N* = 572)	>5 years (*N* = 456)
Bronchiolitis	313 (28.6%)	185 (32.3%)	142 (31.1%)
Acute-rejection	21 (1.9%)	4 (0.7%)	2 (0.4%)
Lymphoma	23 (2.1%)	9 (1.6%)	18 (3.9%)
Malignancy, other	52 (4.7%)	43 (7.5%)	40 (8.8%)
CMV	17 (1.6%)	4 (0.7%)	2 (0.4%)
Infection, non-CMV	284 (25.9%)	113 (19.8%)	79 (17.3%)
Graft failure	175 (16.0%)	99 (17.3%)	58 (12.7%)
Cardiovascular	36 (3.3%)	24 (4.2%)	21 (4.6%)
Technical	12 (1.1%)	1 (0.2%)	2 (0.4%)
Other	163 (14.9%)	90 (15.7%)	92 (20.2%)

Bronchiolite oblitérante: 1ère cause de décès post-TX après 1 an post-Tx
= cause de plus de la moitié des décès

Traitement anti-inflammatoire de la BO
= Azythromycine /Montelukast

1- Azithromycine

= dérivé de la panbronchiolite diffuse (Far-est)

= inhibe la neutro

= effet anti-IL-8

= indication si neu

= Bénéfice prouvé Etude randomisée

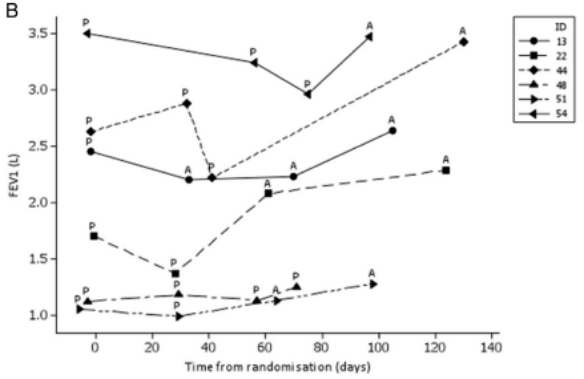

2 Montelukast

= Etude positive

Pathogénie BO *(études humaines)*
Rôle de la neutrophilie alvéolaire (2)

- **rôle supposé des neutrophiles dans les lésions épithéliales de la BO** (3)
  * via les radicaux libres de l'O2
  * via déséquilibre protéases-antiprotéases:
  = activité élastase neutrophilique
  = SLPI (secretory leucocyte protease inh)
  * via déséquilibre oxydants-anti-oxydants

-**Altération épithélium bronchique**, avec diminution des protéines anti-oxydatives telles CCSP (Clara cells Secretory protein) (4) : vulnérabilité au stress oxydatif

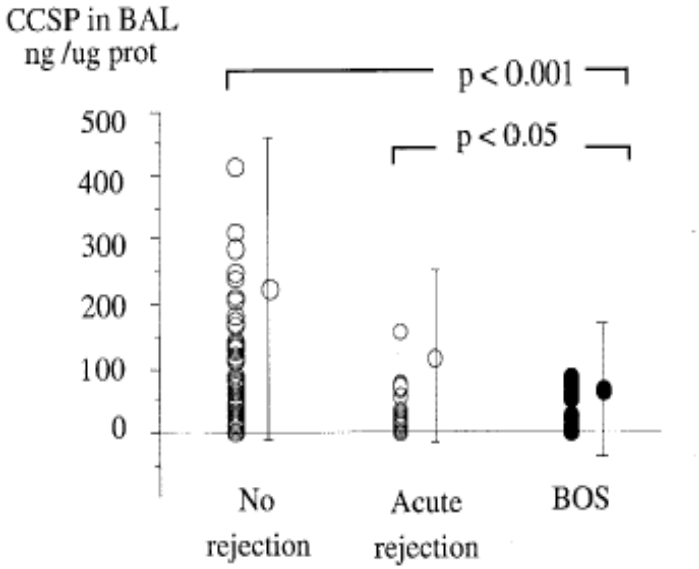

(3) Hirsch 1999 AJRCCM 1999; 160: 1640. (4) Riise . Eur Respir J 1998; 12: 82. (4) Nord. Transplantation 2002; 73: 1264.

Traitement anti-inflammatoire de la BO
= Azythromycine /Montelukast

1- Azithromycine

= dérivé de la panbronchiolite diffuse (Far-est)

= inhibe la neutrophilie alvéolaire

= effet anti-IL-8

= indication si neutrophilie alvéolaire

= Bénéfice prouvé Etude randomisée

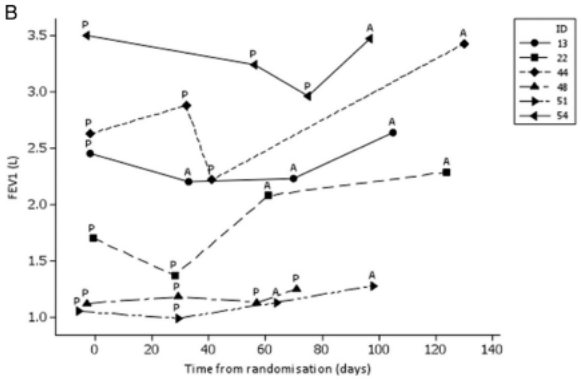

2 Montelukast

= Etude positive

FdR Bronchiolite oblitérante
Reflux gastro-oesophagien acide et non acide

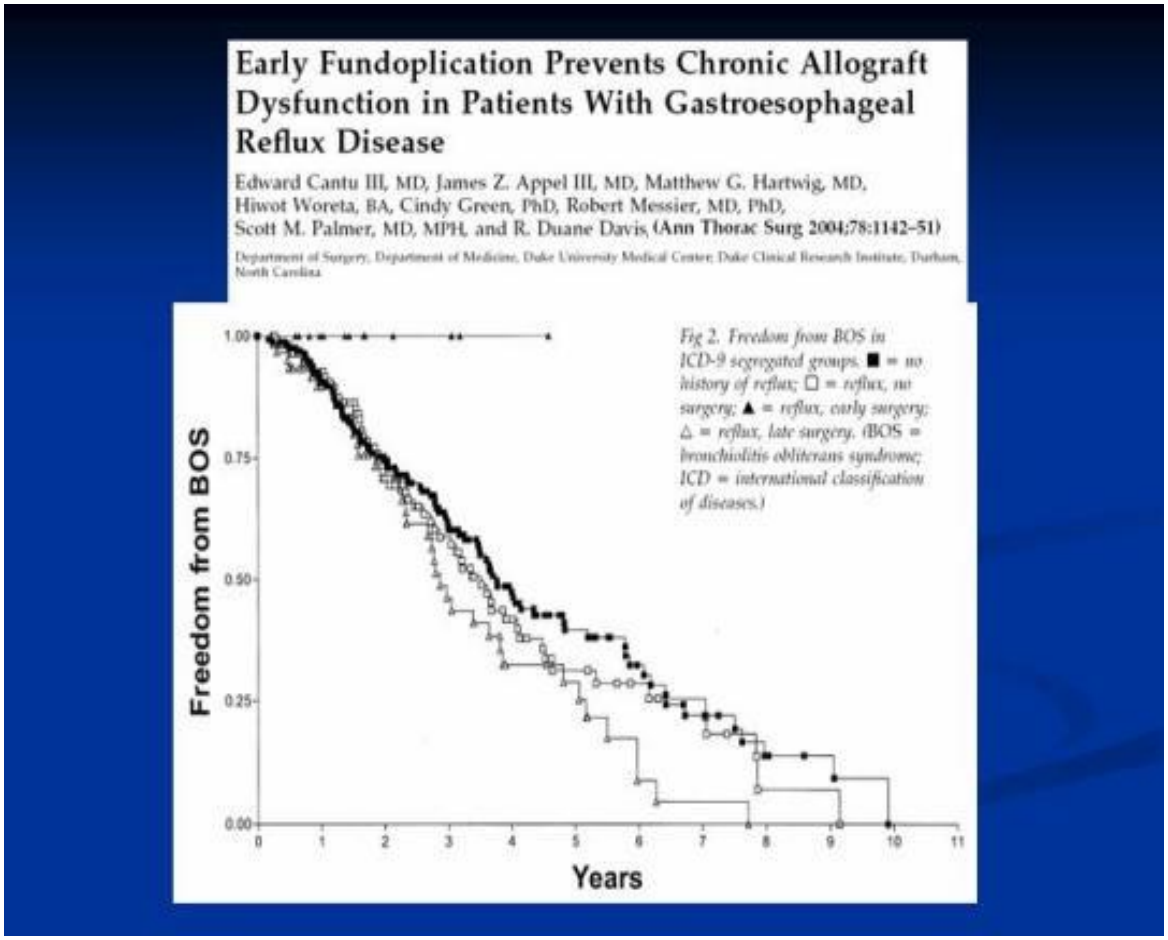

Concentration Pepsine
LBA greffés > LBA non greffés*

Concentration acides biliaires ds LBA
patients BO > patients non BO *

P < 0,05

ERJ 2008

Rejet chronique restrictif: 20%

Restrictive allograft syndrome (RAS): A novel form of chronic lung allograft dysfunction (CLAD) (1) environ 20% des CLAD

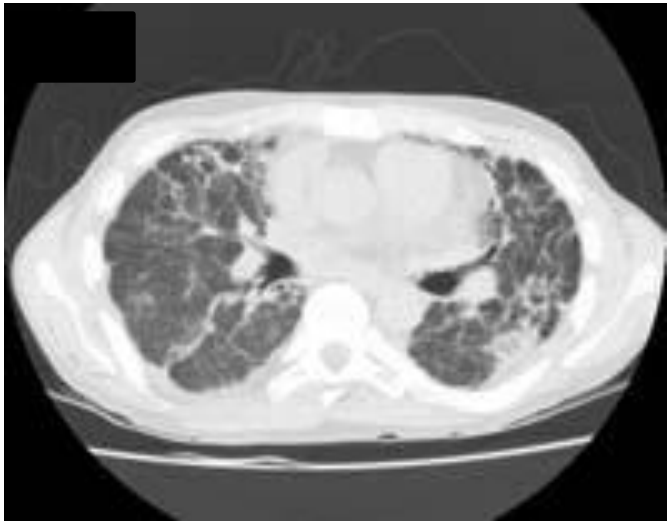

Images réticulaires interstitielles sur RP et TDM
+ consolidation sur TDM

Définition Fonctionnelle

TLC< 90% of baseline
Or FVC <80% of baseline
Or FEV1<80% + tiffeneau > 0,7

+/- associée à TDM:

Verre dépoli, réticulations, pleurésie, prédominance sous pleurale

Histologie pleiomorphe (2)

- pleuroparenchymal fibroelastosis (PPFE) =90%
- Bronchiolitis obliterans (BO) 50%
- Diffuse alveolar damage
- Fibroblastic foci (37%)

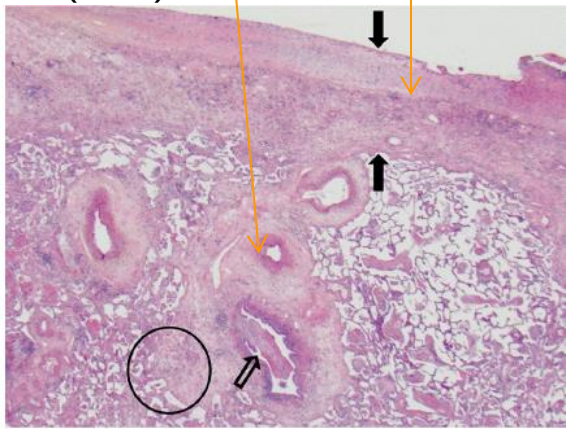

(1) Sato. J Heart Lung Transplant 2011

(2) Ofek E, 2013

Traitement de la BO
Modification des Treg = Photophérèse

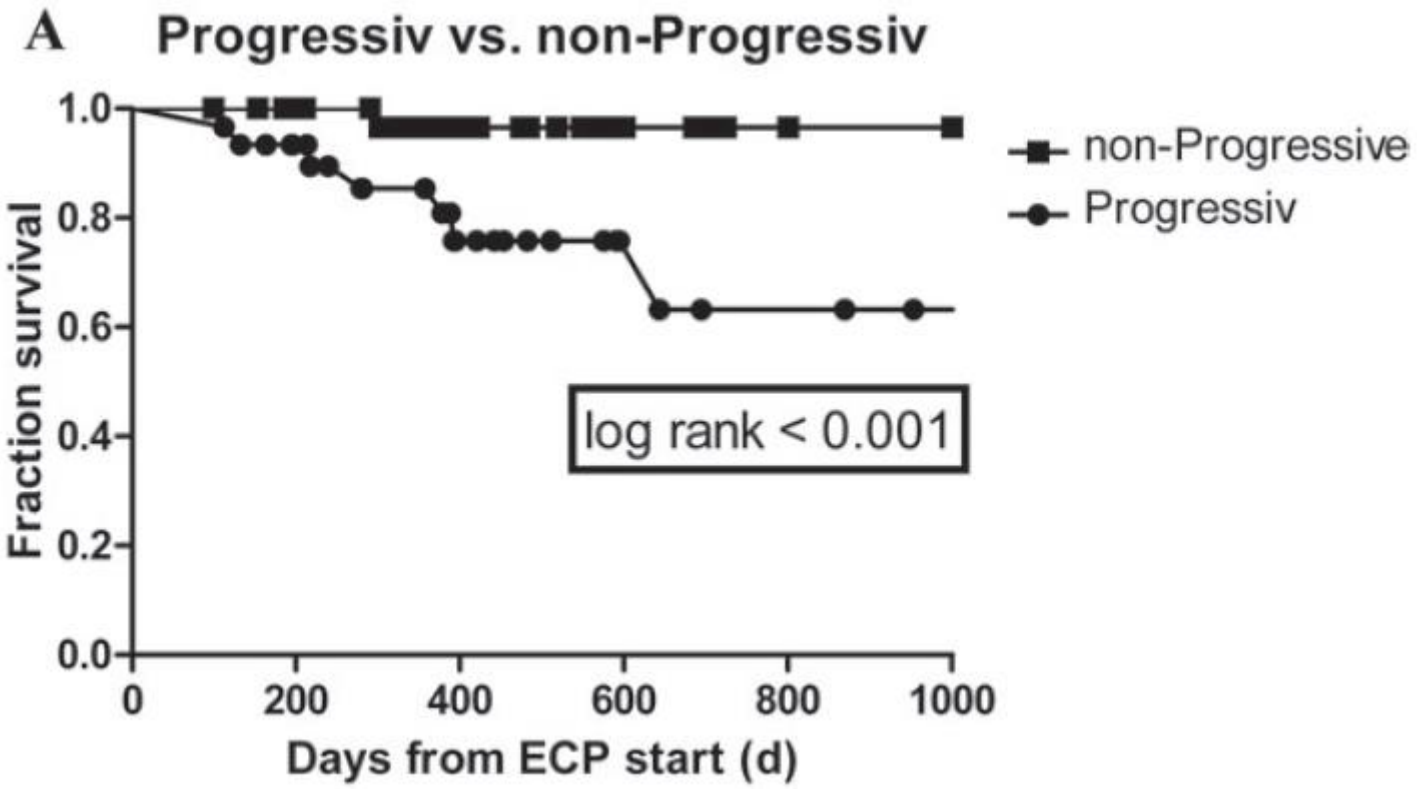

American Journal of Transplantation 2013; 13: 911–918

Mécanismes d'alloréactivité: réponse T

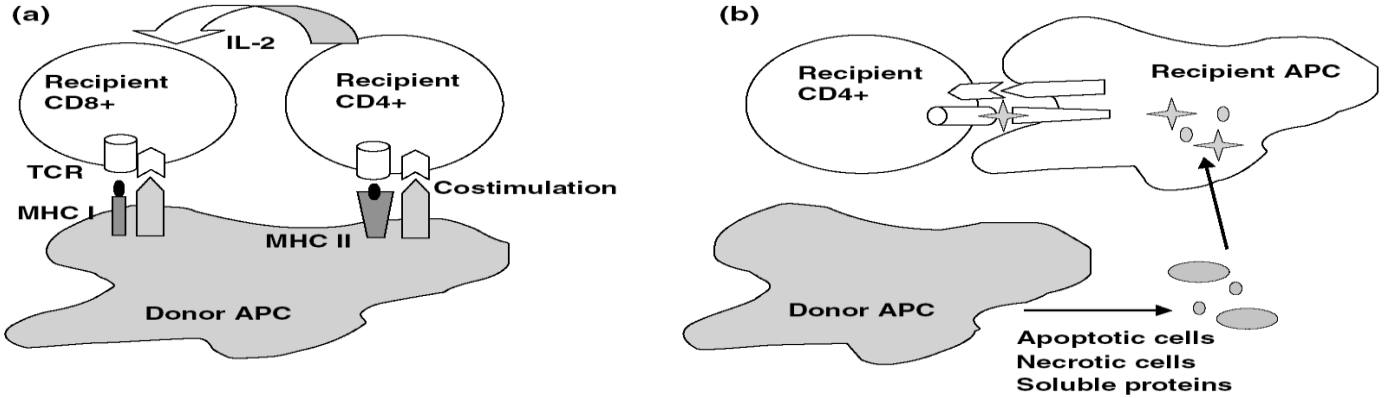

Figure 1 Pathways of allorecognition. (a) Direct pathway. Recipient T cells recognize intact allogeneic major histocompatibility complex (MHC) on donor antigen-presenting cells (APCs). Once primed by the donor APC, allospecific $CD4^+$ T cells can procure help for the effector function of $CD8^+$ T cells that have been activated by the same APC. (b) Indirect pathway. Allogeneic MHC molecules shed from the graft (soluble MHC molecules or dying/apoptotic cells) are taken up and processed by recipient APCs to be presented as peptides in the context of self-MHC molecules. (c) Semi-direct pathway. Recipient APCs acquire and present intact donor MHC I molecules to direct pathway $CD8^+$ T cells and simultaneously present internalized and processed donor MHC molecules to $CD4^+$ T cells with indirect allospecificity. As T cells with direct and indirect allospecificity are primed by the same APC, linked-help can occur.

© 2006 The Authors

BO: Histopathologie

Steward et al. JHLT 2007

Bronchiolite lymphocytaire (B1R)

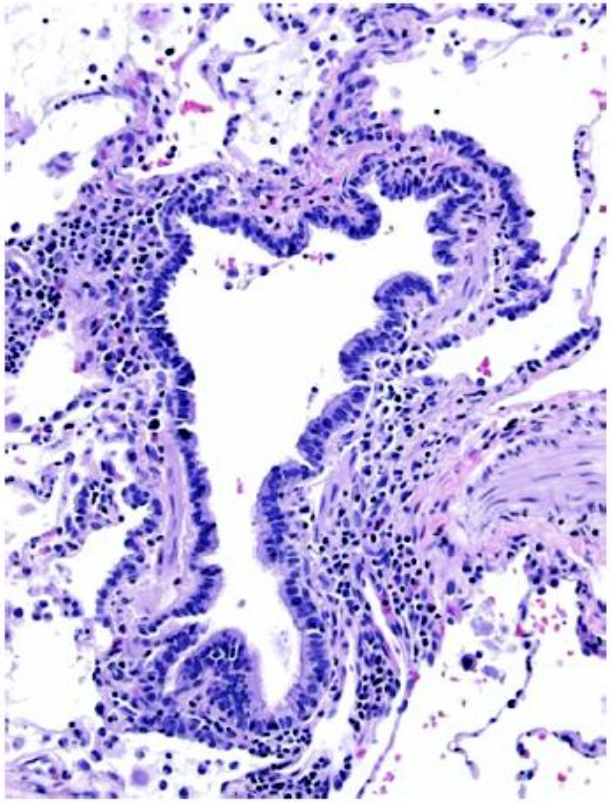

Figure 15. Low grade lymphocytic bronchiolitis (B1R). In this example the bronchiole shows a mild patchy peribronchiolar mononuclear cell infiltrate which spares the respiratory epithelium and is unassociated with epithelial injury. The infiltrate forms an incomplete circumferential band in places. There is no evidence of fibrosis in lymphocytic bronchiolitis in comparison with obliterative bronchiolitis. H&E.

Obliterative bronchiolitis (C)

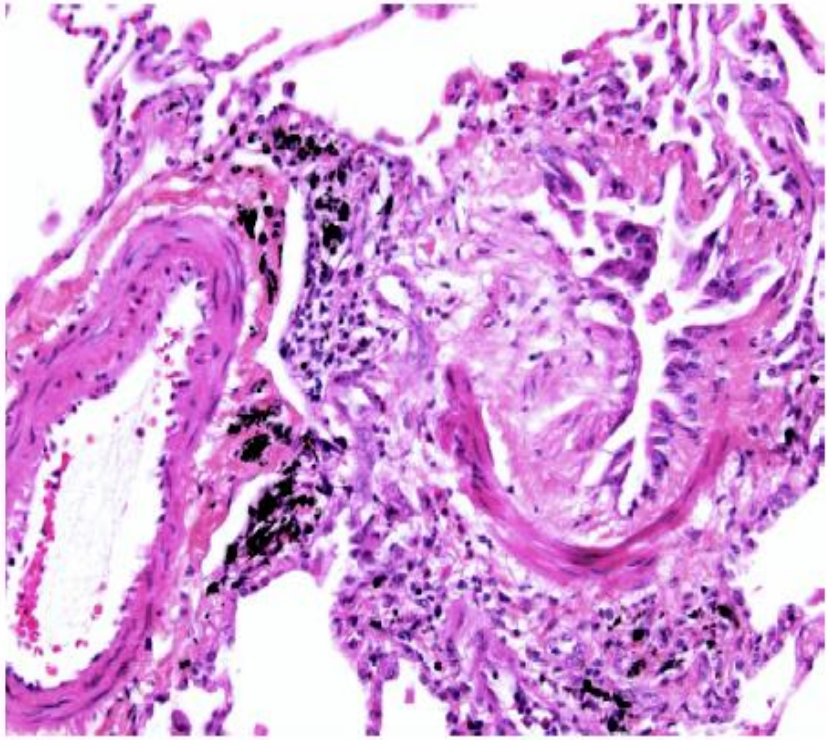

Figure 22. Obliterative bronchiolitis. In this transbronchial biopsy, an eccentric polypoid plaque of dense eosinophilic scar tissue is superimposed between attenuated respiratory epithelium and the smooth muscle wall of the airway. Such focal scarring of the airways is classified as obliterative bronchiolitis. H&E.

Pathogénie BO (études humaines)

= Rôle de la Fibrose de l'épithélium

-Augmentation dans le LBA des patients en BO des concentrations de MCP-1, RANTES, facteurs de croissance (PDGF, IGF-1, TGF-Béta) (1)

-Analyse de la FPA (Fibroblast proliferative activity) chez des greffés en BO (LBA)
= corrélée au déclin de la fonction

(1) Estenne (2) Jonosono. JHLT 1999; 18: 972.

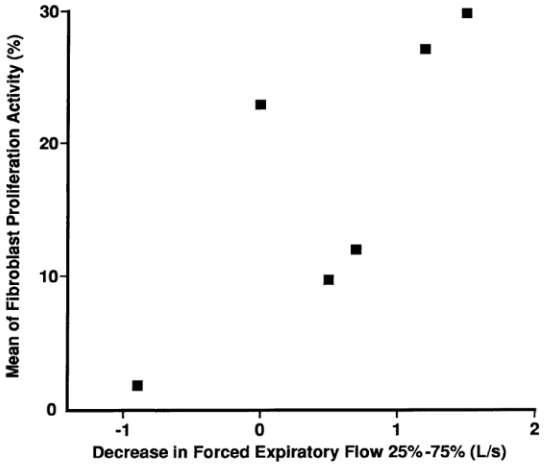

FIGURE 2 Each point represents the correlation between the decrease in the forced expired flow rate between 25% and 75% of expired volume, and the mean fibroblast-proliferative activity during the period of this study for each of the six transplant recipients (Spearman rank correlation, $r = 0.83$; $p = 0.04$). The

Jonosono. JHLT 1999; 18: 972.

Pathogénie BO (études animales)

Rôle de la Fibrose/réparation de l'épithélium

-Rôle du PDGF et VEFG (mitogène du muscle lisse et endothélium) dans la BO

Modèle d'allogreffe de trachée chez les rat (1):

= VEGF exprimé dans cellules mononuclées bronchioles, endothélium, cellules musc lisses artérioles

= PDGF exprimé à la phase fibro-proliférative (cellules de la média, musc lisses des Lésions fibreuses, cellules infla des voies aériennes)

= Inhibiteurs du récepteur de proteine tyrosine kinases
(inh récepteur VEGF (PTK) et PDGF (imatinib) prévient l'oblitération trachéale et diminue la néoangiogénèse

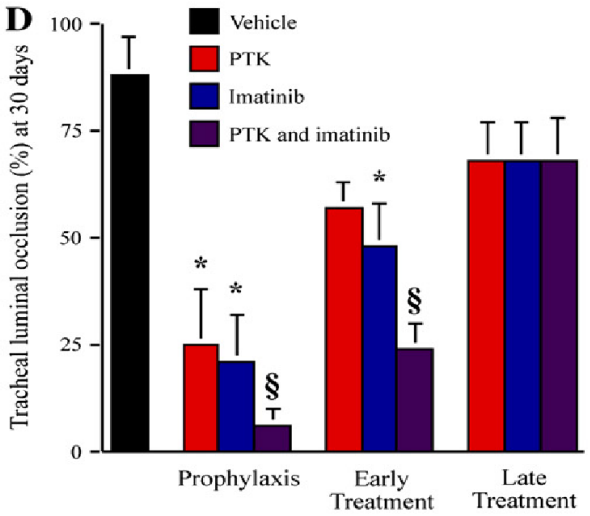

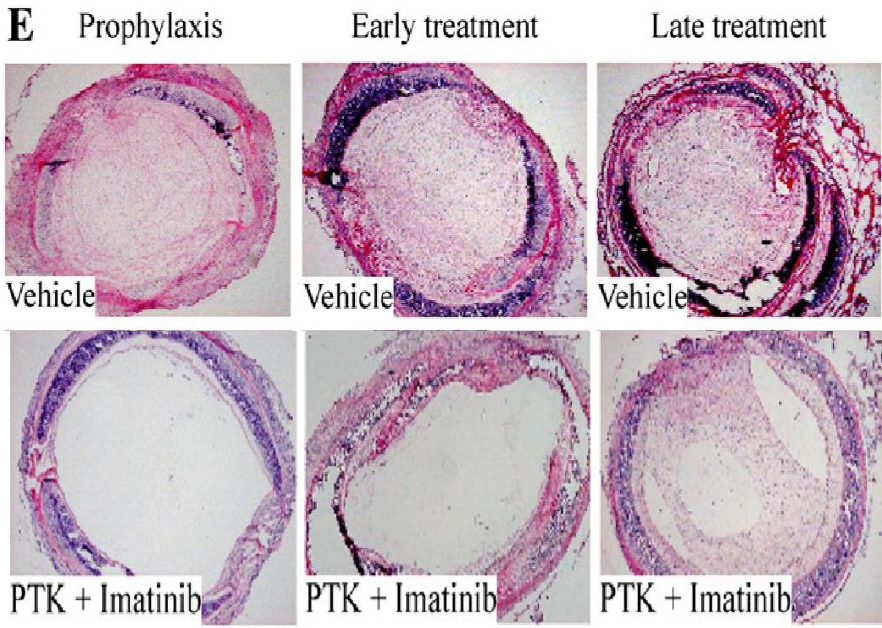

Tikkanen 2006. AJRCCM. 174.1445

Traitement de la BO: immunosuppresseurs

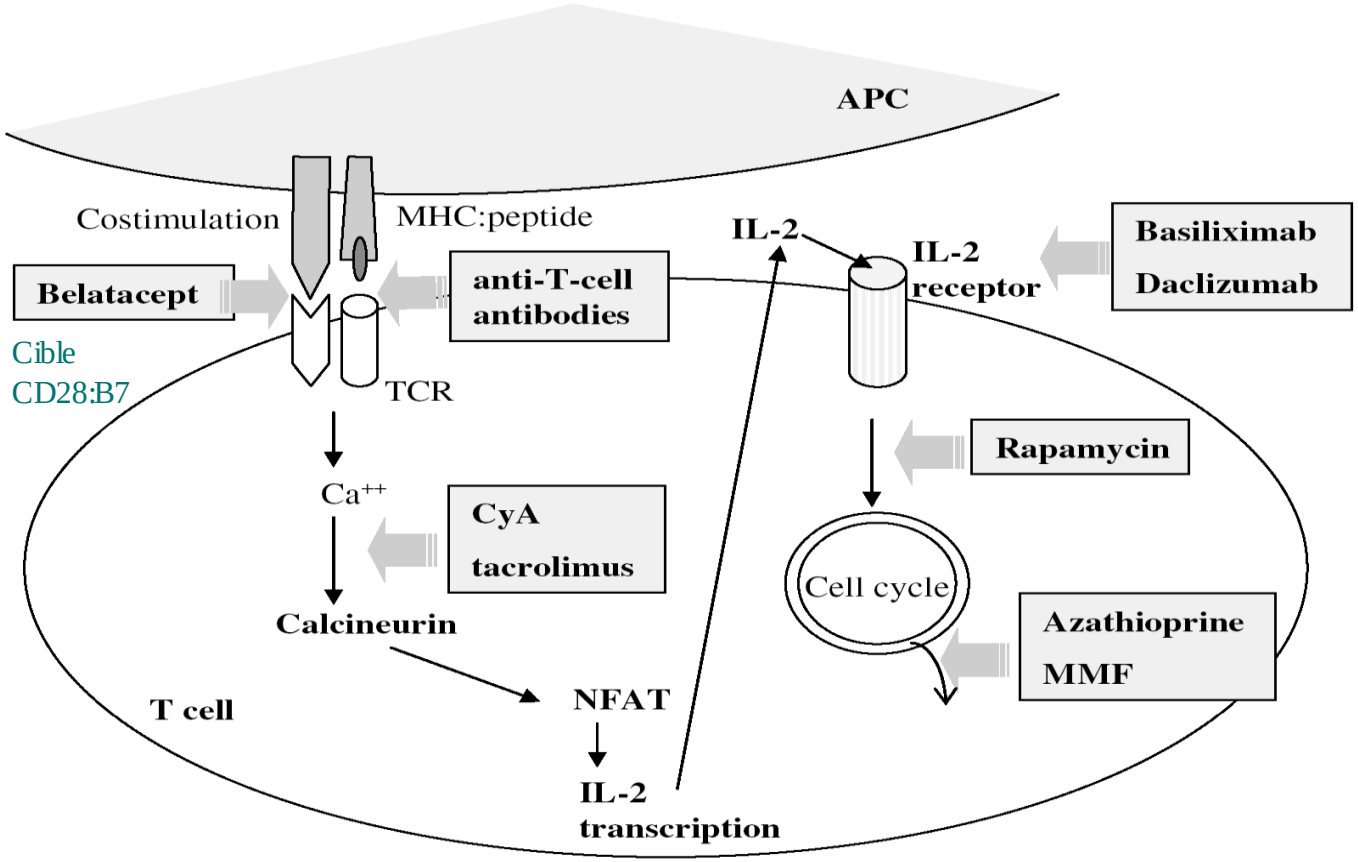

Figure 2 Targets for current immunosuppressive drugs. Signal 1 is delivered through the T-cell receptor (TCR) by recognition of peptide antigens presented in the context of major histocompatibility complex (MHC) molecules on the antigen-presenting cells. This stimulation results in calcineurin activation, a process blocked by cyclosporine A or tacrolimus. Activated calcineurin dephosphorylates the nuclear factor of activated T cells so that it can enter the nucleus and bind to the interleukin-2 (IL-2) promoter. Costimulatory signals (signal 2) are necessary for optimal IL-2 gene transcription in the T cell. IL-2 receptor stimulation induces the T cell to enter cell cycle and proliferate; this can be blocked by IL-2 receptor antibodies or by rapamycin which inhibits signalling induced by IL-2 receptor ligation. By blocking purine synthesis, azathioprine and mycophenolate mophetil MMF interrupt DNA replication and cell proliferation.

© 2006 The Authors

Pathogénie BO *(études humaines)*
Rôle de la neutrophilie alveolaire

-Augmentation IL-8 dans LBA si BO (chemoattracteurs des neutrophiles) (1)

= IL-8 produite par cellules bronchiques et cellules musculaires lisses (2)
dans LBA corrélée à la neutrophilie (7)

-Facteur prédictif de BO
de la neutrophilie alvéolaire

(4, 5, 6)

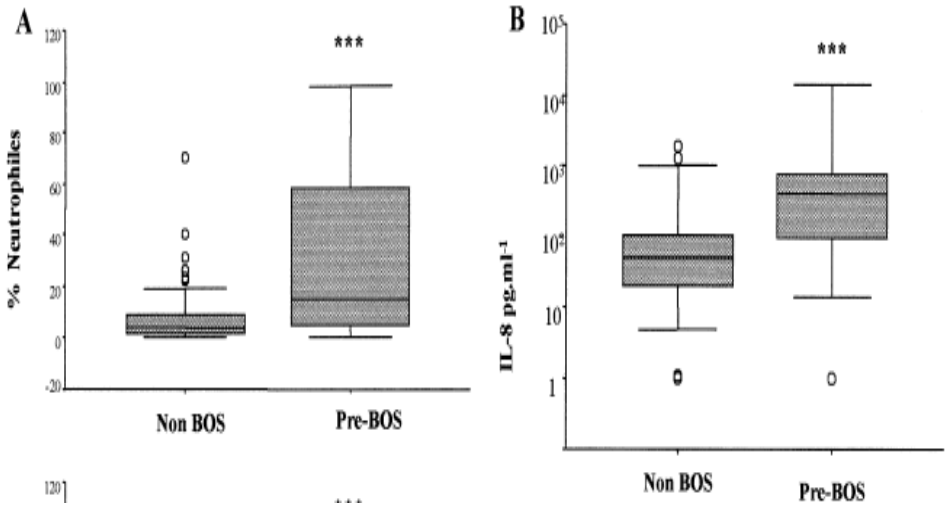

(1) Zeng. Thorax 2000; 53:50. (2) DiGiovine J Immunol 1996; 157: 4194. (3) I
(4) Thorax 2000; 55:53; (5) AJRCCM 2001; 163:259;(6) JHLT, 2004, 23:532 (

Pathogénie Bronchiolite oblitérante

Pathogénèse:

Concept de la réponse à une aggression: L' histopathologie de la BO suggère que les lésions et l'inflammation des cellules épithéliales des voies aériennes entrainent une fibro-prolifération excessive due à une régénération épithéliale inadéquate et un tissu de réparation excessif (1)

BO: stigmate histopathologique commun à plusieurs voies lésionnelles:

= alloimmuns

= non alloimmunes

(1) Halloran. Transplant Proc 1997; 29: 79.

BO: Classification Histopathologie

Table 1. Working Formulation for Classification and Grading of Pulmonary Allograft Rejection (1)

A. Acute rejection [with/without (B)]
- Grade A0, none
- Grade A1, minimal
- Grade A2, mild
- Grade A3, moderate
- Grade A4, severe

B. Airway inflammation—lymphocytic bronchitis/bronchiolitis
- B0, no airway inflammation
- B1, minimal airway inflammation
- B3, moderate airway inflammation
- B4, severe airway inflammation
- BX, ungradeable because of sampling problem, infection, tangential cutting, etc.

Yousem SA, Berry GJ, Cagle PT, et al. Revision of the 1990 working formulation for the classification of pulmonary allograft rejection: Lung Rejection Study Group. J Heart Lung Transplant 1996;15:1–15.

Pathogénie Bronchiolite oblitérante

Agression de l'épithélium = afflux massif de cellules inflammatoires via
Fragmentation membrane basale = secrétions cytokines et chemokines
Par cellules épithéliales, cellules T, MacroP activés, cellules musc. Lisses
= attraction de neutrophiles activés qui amplifient la réaction et altèrent balance protéases et balance oxyda
= processus de réparation abérrant.

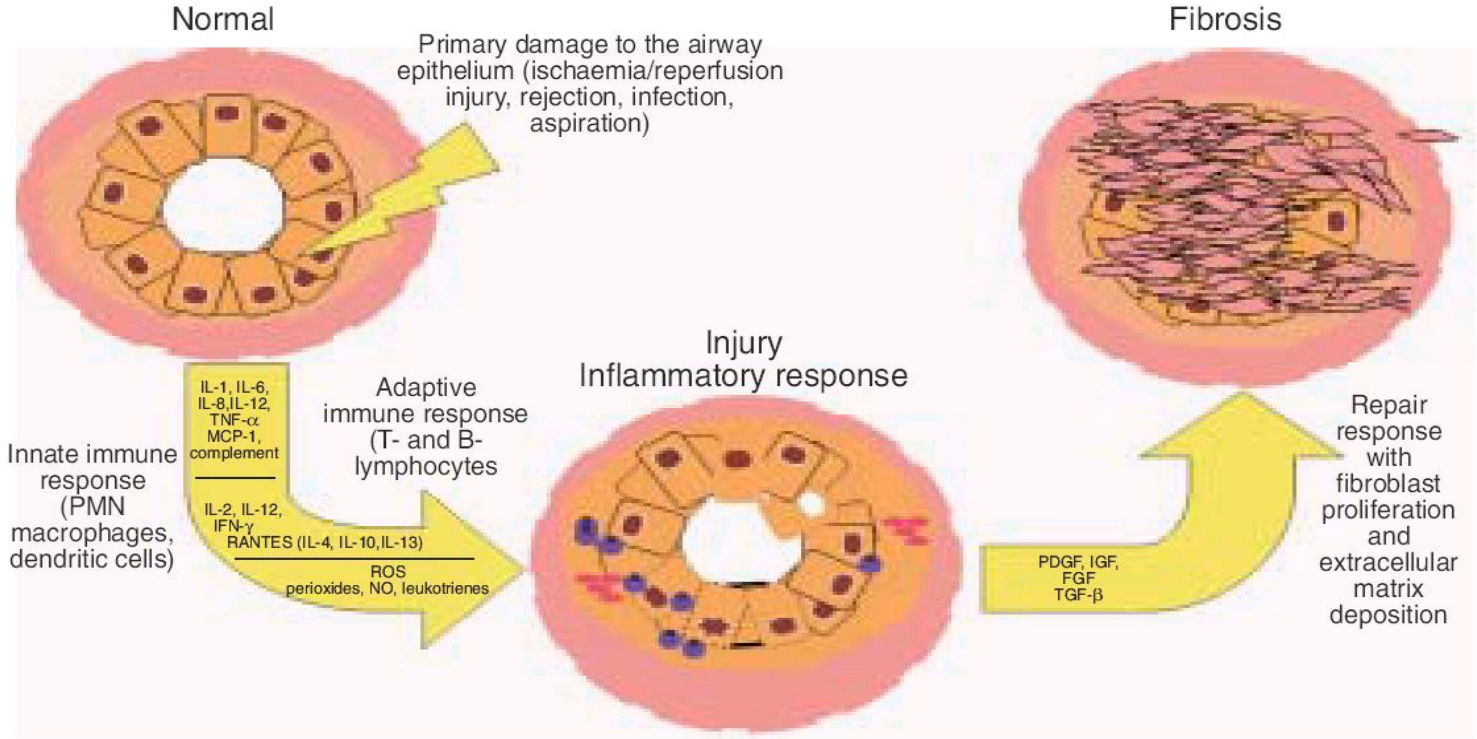

Fig. 1. – Primary damage to the lung allograft leads to activation of the innate immune system, which by interaction of dendritic cells and T-lymphocytes is followed by activation of the adaptive immune system. Injury to the airway epithelium and loss of epithelium leads to repair mechanisms finally ending in intrabronchiolar scar formation. PMN: polymorphonuclear; IL: interleukin; TNF: tumour necrosis factor; MCP: monocyte chemoattractant protein; IFN: interferon; RANTES: regulated on activation, T-cell expressed and secreted; ROS: reactive oxygen species; NO: nitric oxide; PDGF: platelet-derived growth factor; IGF: insulin-like growth factor; FGF: fibroblast growth factor; TGF: transforming growth factor.

Pathogénie BO (études humaines)

Rôle de la réponse allogénique T

- **Alloreconnaissance des antigènes HLA de Classe I donneur c**hez patients en BO = sensibilisation des Ly T (prolifération de PBMC périphériques) chez patients en BO avec HLA-MM Classe I (1)

- **Surexpression des molécules de co-stimulation B7** dans l'épithélium bronchique si BO (2). **Reconnaissance « indirecte » de l'Ag:** DC exprimant CD80 et CD86 (costimulation) augmente significativement si apparition BO (3).

- **Réponse oligoclonale Ly T CD4+** si BO comparés aux patients stables (répertoire des TCR), preuve d'une stimulation antigénique restreinte (5)

SivaSai. Transplantation 1999; 67:1094. (2) Elssner. ERJ 2002; 73.
(3) Leonard CT. AJRCCM 2000; 161:1345. (4) Yousem SA. Ann Thoracic Surg 1990; 49:424 (5) Duncan. AJRCCM 2002; 165.

Rejet aigu

Cellulaire

Bronchiolaire

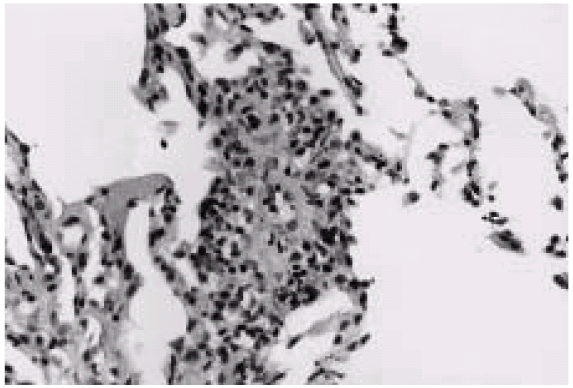

Fig. 2. – A dense perivascular infiltrate of mononuclear cells including small and large lymphocytes and macrophages with intimitis. The infiltrate does not extend into adjacent alveolar walls and the alveolar spaces are clear. Grade A2 acute rejection. Haematoxylin and eosin.

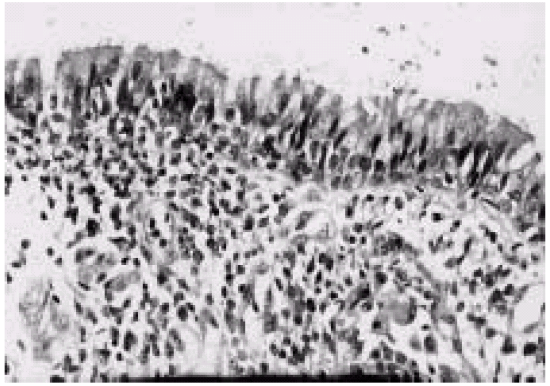

Fig. 5. – Bronchiolar mucosa showing a diffuse infiltrate of lymphocytes in subepithelial tissue and within the epithelium itself. The ciliated respiratory epithelial cells are intact with no evidence of ulceration or metaplasia. Grade B2 acute airways rejection. Haematoxylin and eosin.

Pathogénie Bronchiolite oblitérante

Modèles animaux: médiateurs impliqués: cytokines et chimiokines

- Cytokines impliqués dans la BO comporte une importante réponse Th1 ave la production IFN-Gamma et IL-2 (2) persistant après la fibroprolifération et une réponse Th2 plus modeste avec IL-4 et IL-10 (1)

- Chimiokines: Les RANTES (regulated upon activation , normal T-cell expressedand secreted) recrutant des cellules T mémoires, monocytes, et Eo sont exprimés fortement par cellules mononuclées infiltrant le greffon lors allogreffe de trachée (2)
  Et anti-RANTES diminuent CD4+ infiltrants et préviennent l'oblitération.

- Perte du signal MCP1/CCR2 réduit le nbre de phagocytes mononucléés et l'oblitération
- Perte du signal ligands/CXCR3 réduit le nbre de Lymphocyte et neutroP et l'oblitération

- Rappel: Les CC-chemokines, (RANTES, MIP-1alpha, MIP-1beta, MCP-1) et CXC-chemokines (IL-8, IP-10), jouent un rôle dans le recrutement des leucocytes (CC = macrophages, et CXC (IL-8) = neutrophiles) et et leur expression sont correlées à l'expression des recepteurs correspondants (CCR1, CCR5, CCR2 ,CXCR3).

(1) Neuringer. Transplantation 2000. 69; 399 (2) Boehler. AJRCCM 1999; 159: 1910. (3) Belperio J Clin Invest 2001;
(2) 108. Reynaud-Gaubert. JHLT 2002; 21:692.

FdR Bronchiolite oblitérante

RA humoral en TP: ***Peu de séries avec résultats contradictoires:***

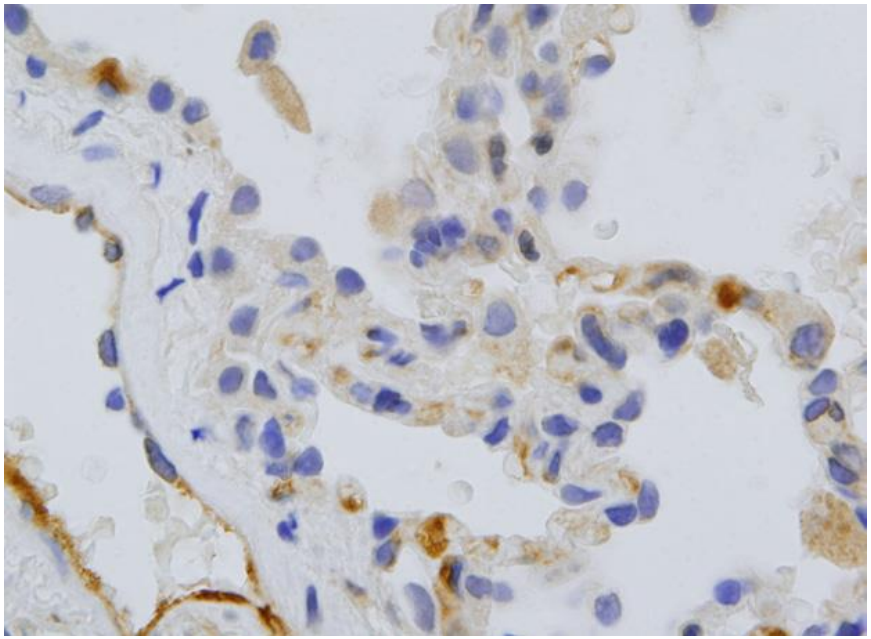

(A) Prominent endoluminal C4d staining throughout the septal capillaries

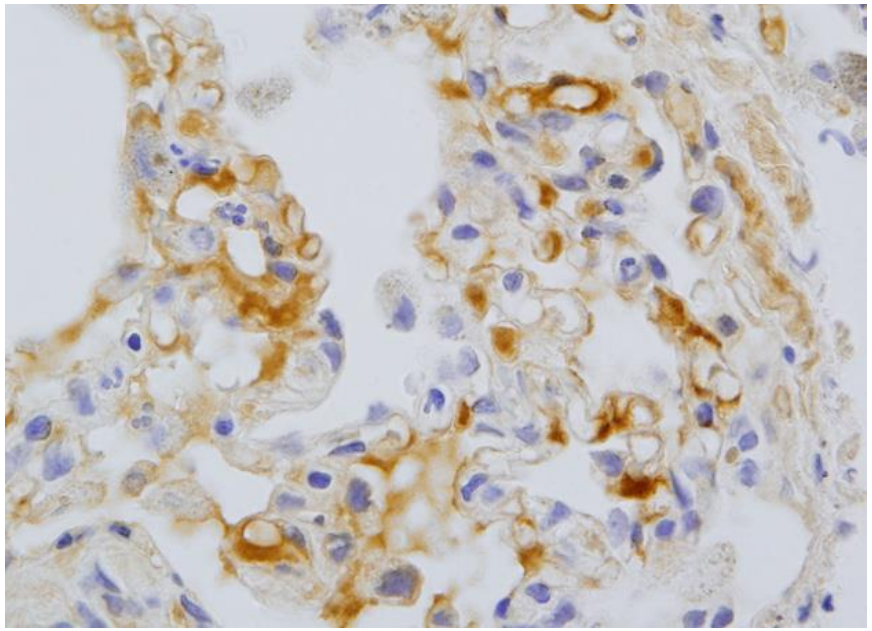

(B) Striking endoluminal C3d deposition within the septal capillaries.

Activation du complément, évaluée sur dépôts **C3d and C4d pourraient être associés à BO rapide** via RA humoral silencieux (Westall J Heart Lung Transplant 2008)

BO: pathogénie

Phenotype of airway epithelial cells suggests epithelial to mesenchymal cell transition in clinically stable lung transplant recipients

C Ward, I A Forrest, D M Murphy, G E Johnson, H Robertson, T E Cawston, A J Fisher, J H Dark, J L Lordan, J A Kirby and P A Corris

Thorax 2005;60:865-871; originally published online 21 Jun 2005; doi:10.1136/thx.2005.043026

Marqueurs de l'EMT:
- acquisition de protéines telle que S100A4,
-expression métalloprotéinases de la matrice (MMP-7, MMP-2, MMP-9) qui peuvent rompre la membrane basale

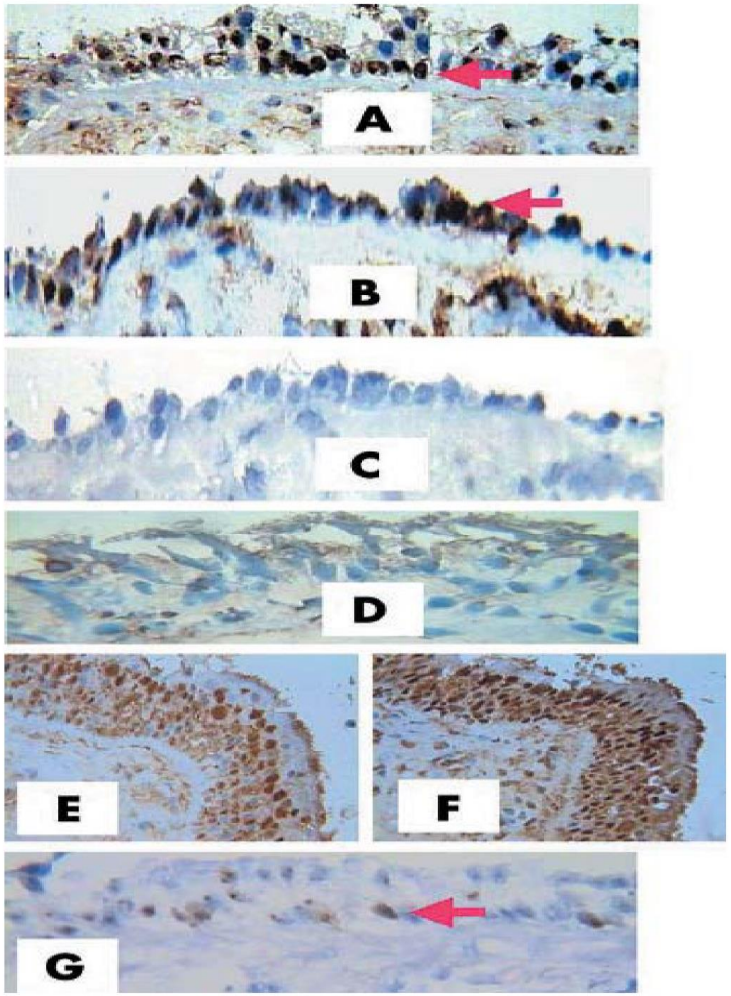

Figure 1A–G Epithelial-mesenchymal transition in vivo. Representative S100A4 positive staining in airway biopsy specimens from lung allografts (B and C) together with a negative staining control (A). S100A4 staining (arrowed) was sometimes observed in areas of the epithelium where morphology was consistent with injury, with only residual basal epithelium remaining on the section (B, same subject as control section). (D) Biopsy specimen from a normal volunteer was borderline positive for epithelial S100A4 due to staining in intraepithelial immune cells but not in epithelial cells. In some subjects sections sequential to S100A4 staining (E) with intact airway epithelium were available and stained positively for the collagenase MMP-7 (F), a further marker of EMT.[21 22] This was in the context of a frankly hyperplastic and proliferative epithelium expressing Ki67 in one subject (G).

Freedom from Bronchiolitis Obliterans

For Adult Lung Recipients ISHLT (Follow-ups: April 1994-June 2002)



Bronchiolite oblitérante

Caractérisation de l'antigène

localisation de l'Ag ?

= Rôle des antigènes HLA démontré, réponse sur l'épithélium démontrée, mais cellules du greffon contenant le stimulus allogénique non précisées

Site antigénique: cellules épithéliales bronchiques?

= Expression constitutive des Ag HLA Classe I par cellule épithéliale

= Expression des Ag HLA classe II par ischémie-reperfusion (2),
Ou lors d'infection virale (3)

Site antigénique: cellules endothéliales?

= Rejet aigu: infiltration périvasculaire avec Augmentation expression HLA-DR dans les cellules endothéliales

= BO: augmentation de l'expression HLA-DQ
Et Ag de classe I, et Répétition RA = fdR de BO,

Mais où se situe le shift de la réaction alloimmune du compartiment De l'endothélium vers l'épithélium des voies aériennes?

Dysfonction chronique du greffon post-TX pulmonaire

Table 1. – Chronic allograft dysfunction in solid organ transplantation

Organ	Pathological features	Incidence 5 yrs after transplant %
Liver	Vanishing bile duct syndrome	5
Kidney	Glomerular sclerosis/tubular atrophy	30
Heart	Coronary artery sclerosis	20
Lung	Bronchiolitis obliterans	50–60

Incidence très supérieure comparée aux autres greffes organes solides

FdR Bronchiolite oblitérante
Reflux gastro-oesophagien
acide ou non acide

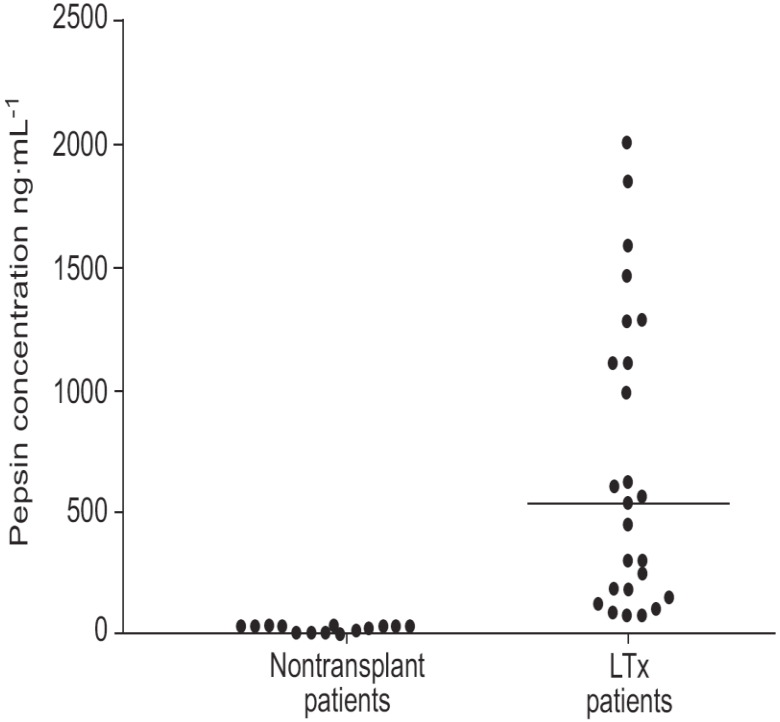

FIGURE 2. The concentration of pepsin in the bronchoalveolar lavage fluid was significantly higher in lung transplant (LTx) recipients (532 (184–1,190) ng·mL^{-1}) compared with controls (23.83 (0–25) ng·mL^{-1}).

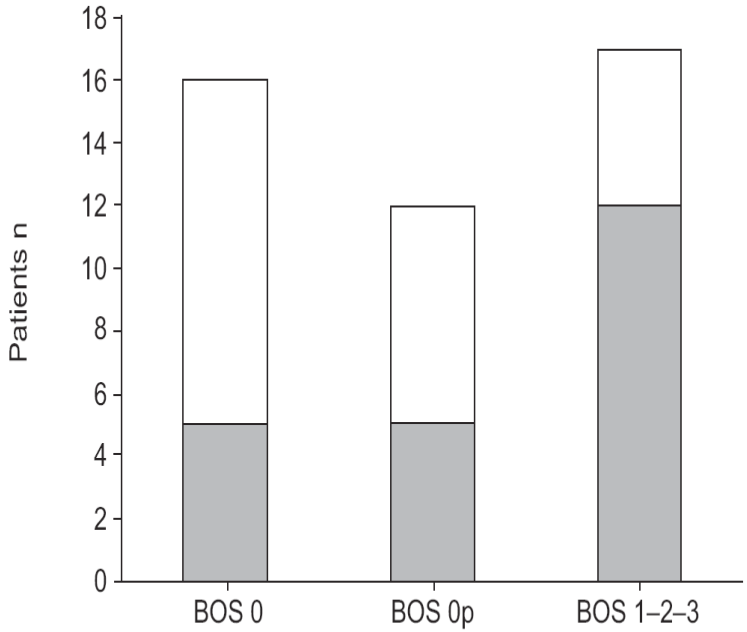

FIGURE 3. The proportion of patients with bile acids in the bronchoalveolar lavage fluid (BALF; ■) compared with no bile (□) in relation to the bronchiolitis obliterans syndrome (BOS) stage. Significantly more patients with BOS had detectable bile in the BALF compared with stable patients (p=0.03). BOS 0: BOS not present; BOS 0p: probable BOS; BOS 1–2–3: BOS grade 1, 2 or 3 present.

Blondeau ERJ 2008; 31: 707

BO

Prolifération Ly T effecteurs

Différentes cinétiques d'OAD sur un modèle murin d'allogreffe de trachée induits opar les cellules CD4+ et CD8+

Methods. **Tracheal allografts from BALB/c and HLAA2-transgenic (HLA-A2) mice were heterotopically transplanted into C57BL/6, CD4-knockout (KO), CD8-KO**

Results. **HLA-A2 allografts transplanted into C57BL/6, CD8-KO, and Ig-KO mice demonstrated OAD lesions by day 30. In contrast, allografts transplanted into CD4-KO mice showed no OAD lesions at day 30, partial OAD development by days 60 and 90, and complete OAD development by day 180.**

These results show that both CD4 and CD8 T cells have a role in the pathogenesis of OAD

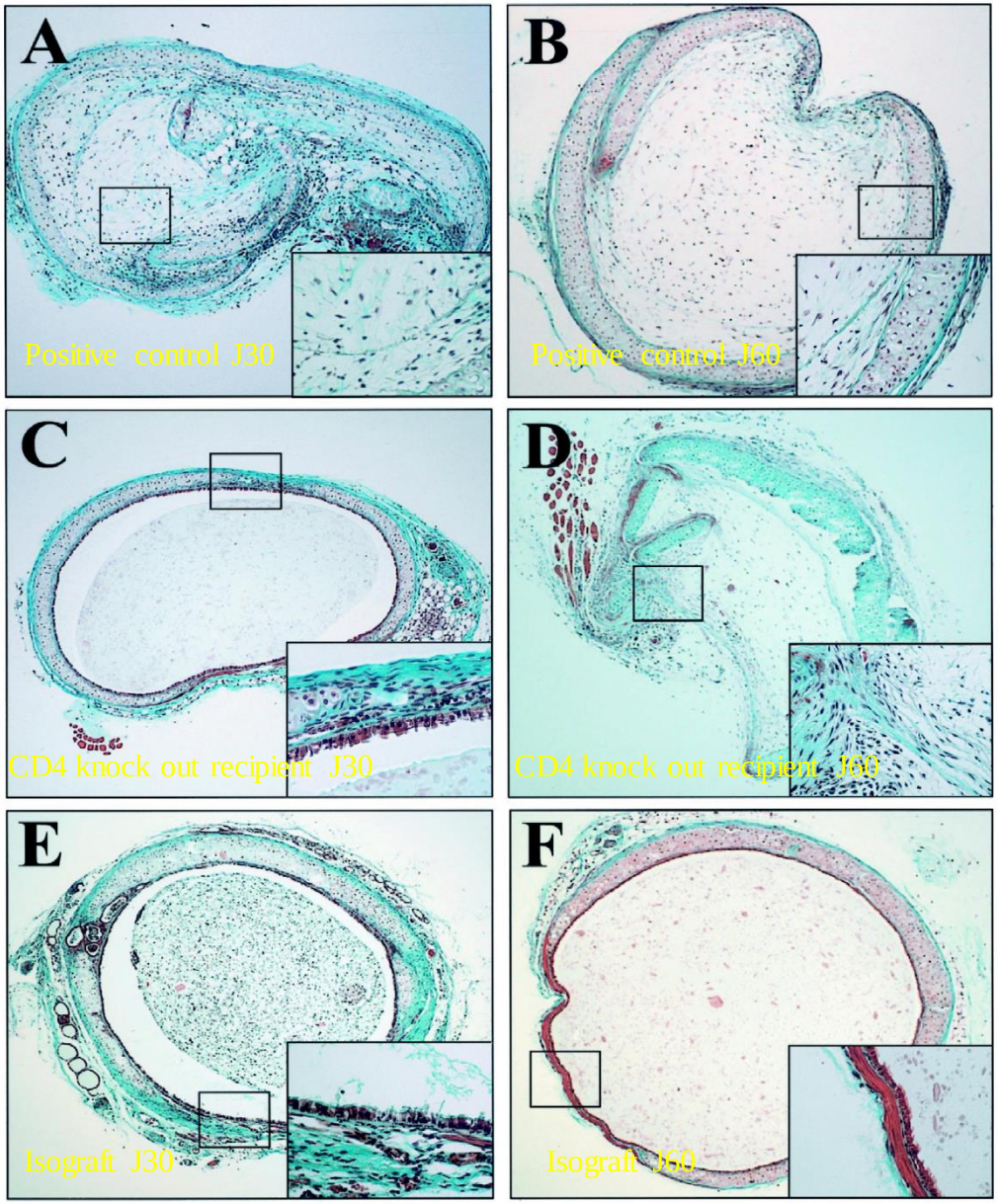

FIGURE 1. Histological analysis of BALB/c tracheal allograft rejection. Tracheal grafts were fixed in 10% paraformaldehyde, embedded in paraffin, cut into 5-μm sections, and stained with Masson's trichrome. BALB/c allografts were harvested from C57BL/6 (A) and CD8-KO mice (B) at day 30 and from CD4-KO mice at days 30 (C) and 60 (D). C57BL/6 isografts were harvested from C57BL/6 mice at days 30 (E) and 60 (F) (magnification × 400; insets × 1000).

Higuchi Transplantation 2002; 74: 646.

Bronchiolite oblitérante

Quel celllule ou type de tissu est le plus antigénique dans la BO?
Site antigénique: cellules épithéliales bronchiques?

- Expression constitutive des Ag HLA Classe I par cellule épithéliale

- Libération de molécule HLA classe I/B(2)m et Beta(2)m isolée liée à l'activation des métalloprotéases de la matrice (1)

- Expression des Ag HLA classe II par ischémie-reperfusion (2), Ou lors d'infection virale (3)

- Antigène non-HLA: human epithelial-glycoprotein (4)

- L'épithélium bronchique peut participer à l'activation du second signal par une Augmentation de l'expression des ligands co-stimulation B7, CD 80, CD86

(1) Haynes LD. Hum Immunol 2002; 63:893. (2) Serrick C. Ann Thorac Surg 1997; 63: 202. (3) Milne Transplantation 1994; 57: 1762.
(2) (4) Qu N. Transplantatin 2003;76: 1022.

Bronchiolite oblitérante

Site antigénique: cellules endothéliales?

Rejet aigu: infiltration périvasculaire avec
Augmentation expression HLA-DR dans
Les cellules endothéliales

BO: augmentation de l'expression HLA-DQ
Et Ag de classe I

Répétition RA = fdR de BO,
Mais où se situe le shift de la réaction alloimmune du compartiment
De l'endothélium vers l'épithélium des voies aériennes?

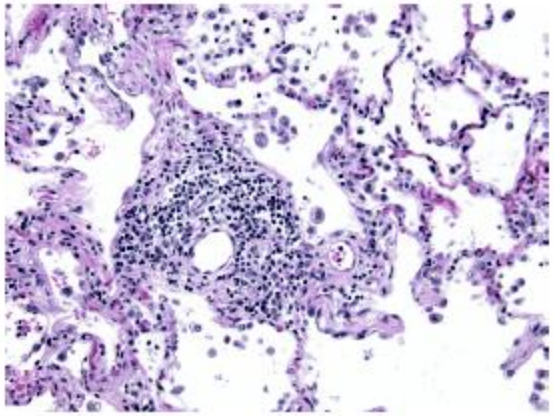

Figure 4. Mild acute cellular rejection (A2). In mild acute cellular rejection, the perivascular interstitium of small vessels, venules and arterioles, demonstrates significant circumferential expansion of the perivascular interstitium by mononuclear inflammatory infiltrate. The infiltrate consists largely of mononuclear cells with occasional activated lymphocytes and plasmacytoid lymphocytes. The mononuclear inflammatory infiltrate within the perivascular zones may be accompanied by alveolar macrophages. No infiltration of adjacent alveolar septa by the mononuclear infiltrate is present. H&E.

Bronchiolite oblitérante

Réponse allo-immune: tolerance

tolerance par délétion centrale (modèles animaux)

-injection intrathymique de moelle osseuse du donneur

Avant allogreffe de poumon chez le rat:

= augmentation de la durée de vie (1),

-Transfusion de cellules dendritiques thymiques du donneur « homed » vers le thymus du receveur où une délétion centrale des lymphocytes allogéniques se produit, augmentant la durée de vie (2)

Microchimérisme : prédictif d'une tolérance

Une augmentation du microchimérisme dans le sang périphérique

Semble liée à une survie sans BO > greffe de poumon (homme)

= test prédictif d'une tolérance (3)

(1) Li S. Ann Thorac Surg 2003. (2) Li S. Ann Thorac Surg 2003; 75: 257. (3) McSherry. J Leukoc Biol 1999; 66: 306

BO : pathogénie

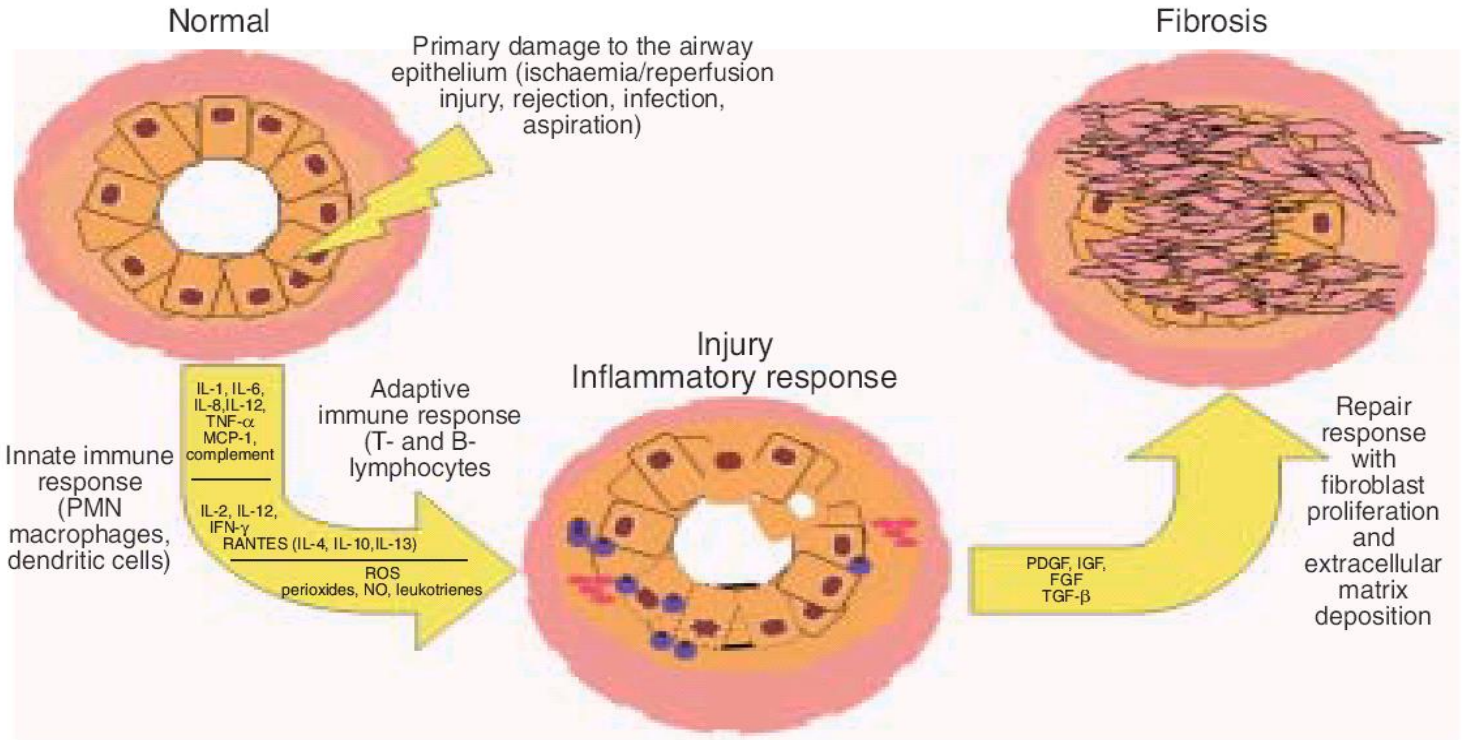

Fig. 1. – Primary damage to the lung allograft leads to activation of the innate immune system, which by interaction of dendritic cells and T-lymphocytes is followed by activation of the adaptive immune system. Injury to the airway epithelium and loss of epithelium leads to repair mechanisms finally ending in intrabronchiolar scar formation. PMN: polymorphonuclear; IL: interleukin; TNF: tumour necrosis factor; MCP: monocyte chemoattractant protein; IFN: interferon; RANTES: regulated on activation, T-cell expressed and secreted; ROS: reactive oxygen species; NO: nitric oxide; PDGF: platelet-derived growth factor; IGF: insulin-like growth factor; FGF: fibroblast growth factor; TGF: transforming growth factor.

Bronchiolite oblitérante post-TxP

- TxP: Situation unique où le greffon est exposé à une réaction alloimmune, et facteurs non spécifiques

- la BO = stigmate histopathologique commun à plusieurs voies lésionnelles

- Epithélium bronchique :
  = acteur de la BO : initie la réponse
  = cible

- rôle des facteurs de croissance et de réparation = à préciser

Bronchiolite oblitérante

Après la reconnaissance de l'antigène:

Prolifération des Ly T effecteurs et production de cytokines *(Neuringer 2005)*

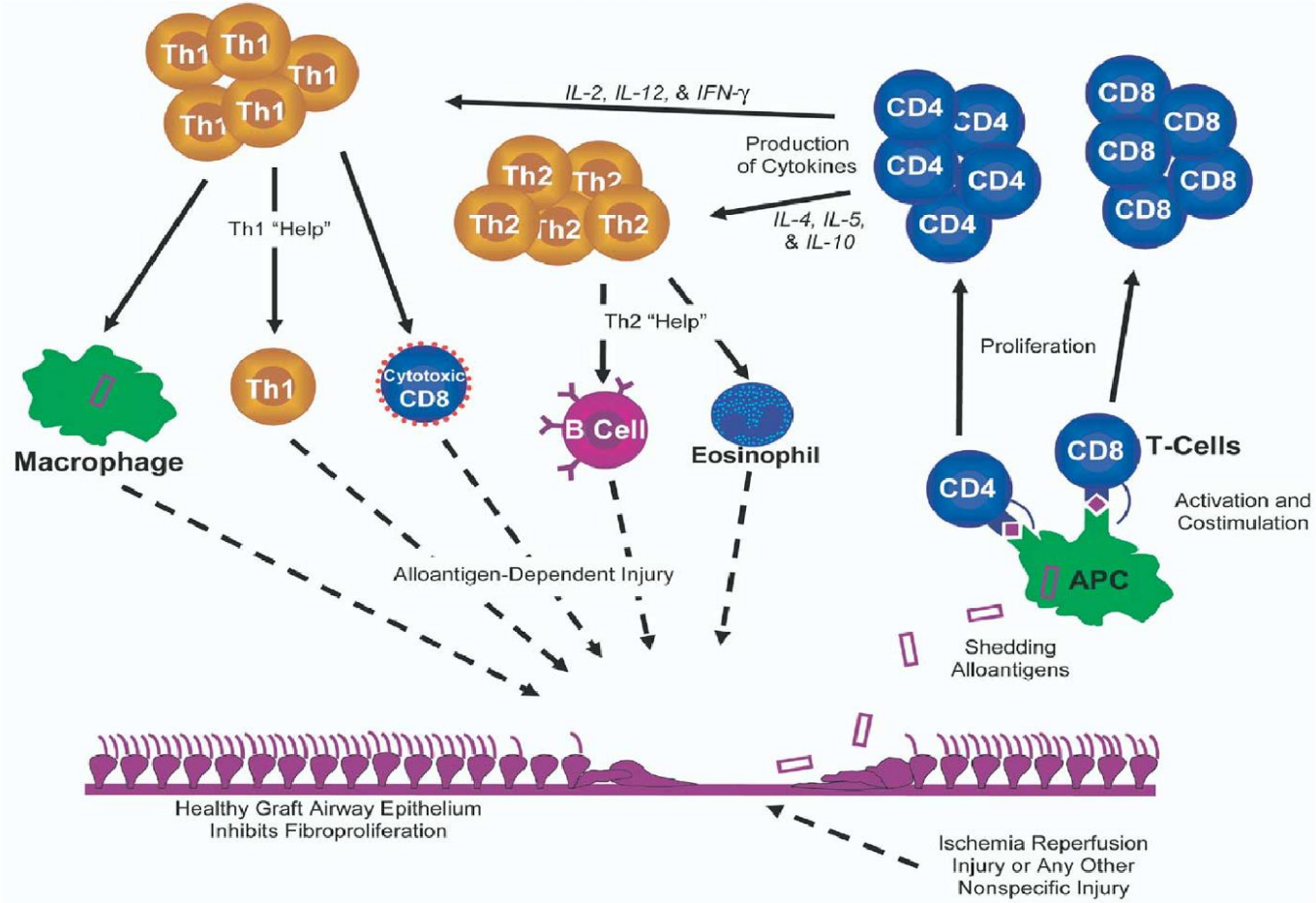

Figure 2. Proposed mechanisms that begin with non-specific graft injury that leads to shedding of alloantigens, endocytosis, and procession of antigens by antigen-presenting cells (APCs) and antigen recognition. Lymphocyte activation and proliferation of both CD4 (T helper [Th]1 and Th2) and CD8 clones that have varying allospecificities follows and leads to the development of Th1-directed, cell-mediated immunity (delayed-type hypersensitivity and cytotoxic lymphocyte [CTL]), and Th2-directed immune responses (humoral, antibody-dependent cell cytotoxicity and complement-mediated, and eosinophil recruitment) against graft antigens that results in cell death and tissue injury.

FdR BO :altérations de la microvascularisation des petites voies aériennes (PVA)

- Diminution de la densité des microvaisseaux des voies aériennes
= Situation d'ischémie lors des aggressions (infection et/ou RA) favorise une réponse inadéquate avec fibroprolifération des PVA= OB

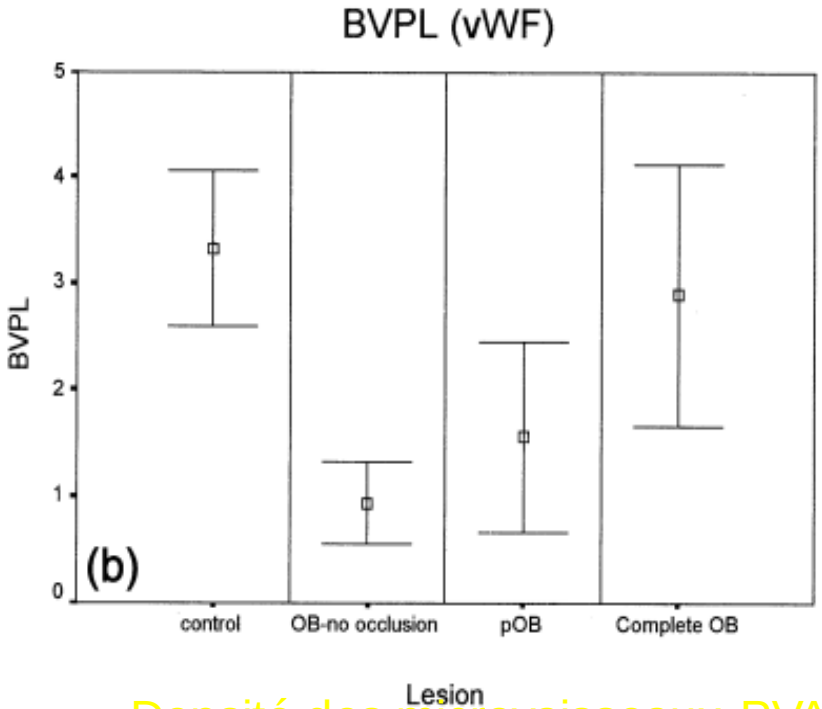

Densité des microvaisseaux PVA

Figure 2. Median number of blood vessels per unit length of SA circumference (BVPL) using (a) CD31 and (b) vWF for the 4 groups.

Réaugmentation secondaire de la densité des microvaisseaux lors de la BO via fibroblastes, facteurs croissance endothelium, néoangiogénèse

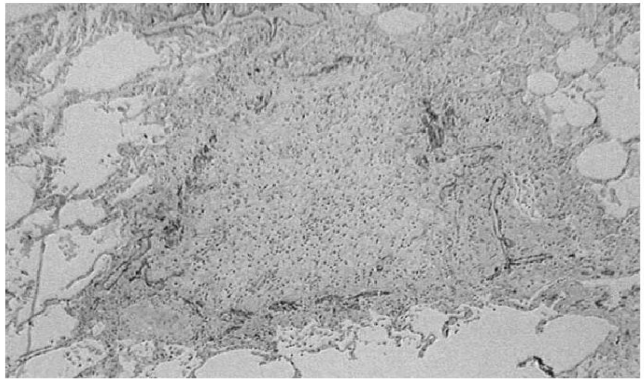

Figure 3. Four-fold magnification of an OB-affected small airway to demonstrate the altered morphology and increased density of microvessels on the muscular layer. The specimen has been doubly stained with vWF and smooth muscle actin antibodies.

Luckraz. JHLT 2004

Pathogénie Bronchiolite oblitérante

médiateurs impliqués

Cytokines TH 1 : IL-2, IFN G (modèle animal)

- Homme: Rôle prédictif de l'IL-12 pour l'apparition de la BO (un taux bas est prédictif de BO, via production IFN-Gamma inh fibrose?) (1)

Cytokines TH 2: IL 4, IL 10 (modèle animal)

- Homme: IL-10 significativement augmentée chez les patients stables vs BO (Taux bas IL-10 si BO = augmentation de l'inflammation et du remodelage ?) (2)

Chimiokines

- RANTES. Homme: Rôle prédictif augmentation RANTES (CC chimiokine attractant des Ly T mémoires, Eo, et monocytes). Modèle OAD: Anti-RANTES diminuent les CD4+ et l'oblitération.
- MCP1. Homme: Rôle prédictif augmentation MCP-1 (CC chimiokine) < apparition BO (3). Modèle OAD: perte signal MCP 1-CCR2: inh infiltration par phagocytes et oblitération)
- Augmentation des ligands du récepteur de chimiokines CXCR3 chez les patients en BO (3), qui explique le recrutement péribronchique des cellules mononuclées exprimant CXCR3 (Ly activés, NK). Perte du signal supprime l'oblitération Sur modèle d'OAD.

(1) Meloni JHLT 2004; 23: 1053. (2) Beeh. JHLT 2001; 20: 1144. (3) Reynaud Gaubert JHLT 2002, 21: 721 Belperio J Clin Invest 2001

Pathogénie Bronchiolite oblitérante

Etudes cliniques humaines

Rôle de l'immunité humorale chez l'homme

- **production AC anti-HLA Cl I** (1) associés à la BO, qui semblent pouvoir induire en retour une prolifération de l'épithélium voies aériennes, (autre facteur potentiel étiologique de la BO: ref 2)

- **Développement d'AC non HLA dirigé contre l'épithélium**, associé à la BO (3), qui pourraient stimuler facteur de croissance (tel TGF-Beta)

- **Activation du Complément** :
  - C4d : controversé
  - C3d : dépôt dans les bronches associé à lésions microvasculaires, fibrose bronchique et développement BOS ***(Human Immunol 2006; 67:274)***.

(1) Jaramillo. Transplantation 1999; 67: 1155. (2) Reznik. J Thorac Cardiovasc Surg 2000; 119: 39.
(3) Jaramillo Transplantation 2001; 71: 966.

Pathogénie BO: *Etudes cliniques humaines*

Fibrose et réparation de l'épithélium

Démonstration que des cellules circulantes
précurseurs de fibroblastes sont impliquées dans les lésions de fibrose
Et qu'elle dérivent probablement de la MO du receveur
= les processus de fibrose de la BO n'impliquent pas
que des phénomènes de réparation locale.

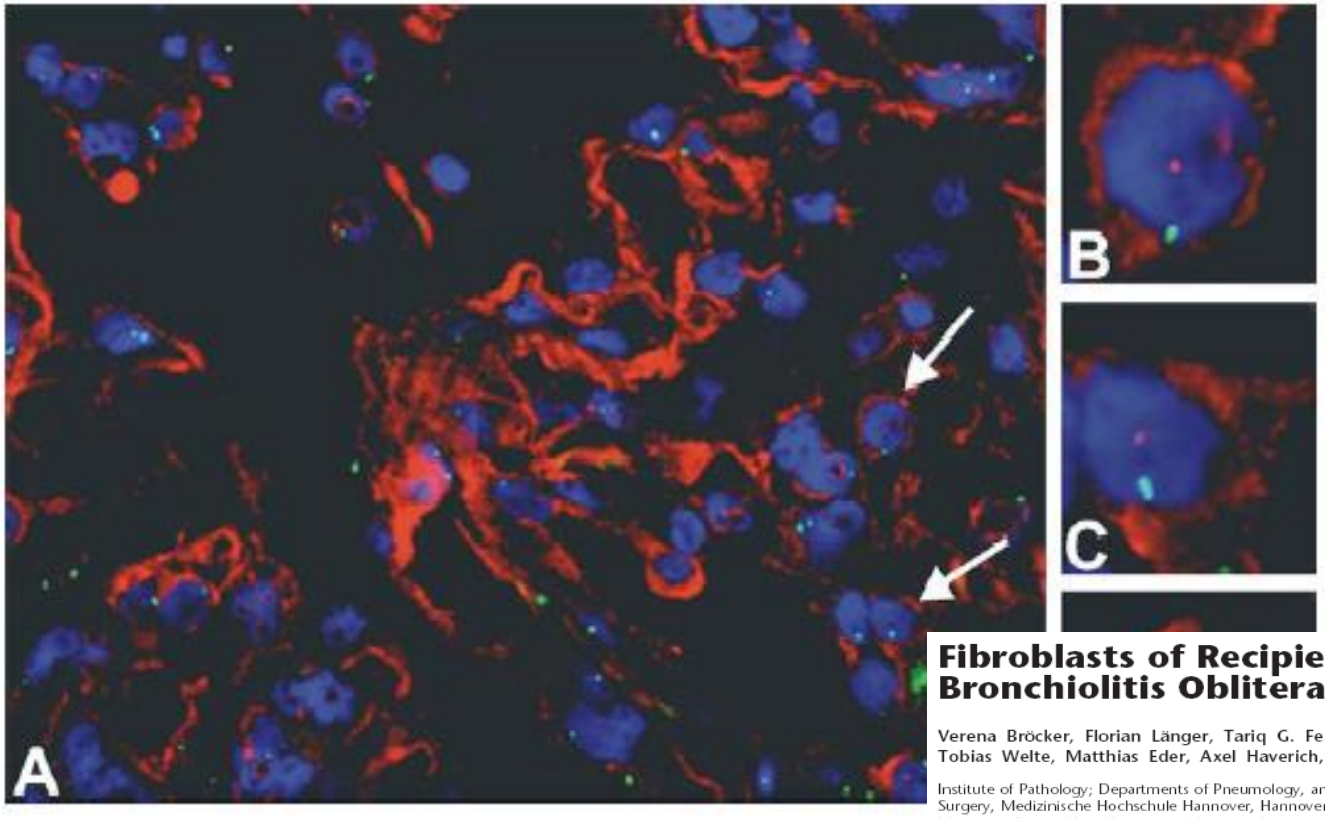

SMA:
Smooth cell actin

Figure 6. Combined immunohistochemistry and fluorescence *in situ* hybridization analysis of Patient 7. A subset of the allograft recipient–derived cells (Y-chromosome positive) is unequivocally SMA positive. For details of the quantitative evaluation, *see* text (*green nuclear dot*: X chromosome; *red nuclear dot*: Y chromosome).

Fibroblasts of Recipient Origin Contribute to Bronchiolitis Obliterans in Human Lung Transplants

Verena Bröcker, Florian Länger, Tariq G. Fellous, Michael Mengel, Mairi Brittan, Martin Bredt, Simone Milde, Tobias Welte, Matthias Eder, Axel Haverich, Malcolm R. Alison, Hans Kreipe, and Ulrich Lehmann

Institute of Pathology; Departments of Pneumology, and Hematology, Hemostaseology, and Oncology; Division of Thoracic and Cardiov Surgery, Medizinische Hochschule Hannover, Hannover, Germany; and Institute of Cell and Molecular Science, Diabetes and Metabolic Medicine, Queen Mary University of London, London, United Kingdom

Non utilisé

Dysfonction chronique du greffon post-TX pulmonaire

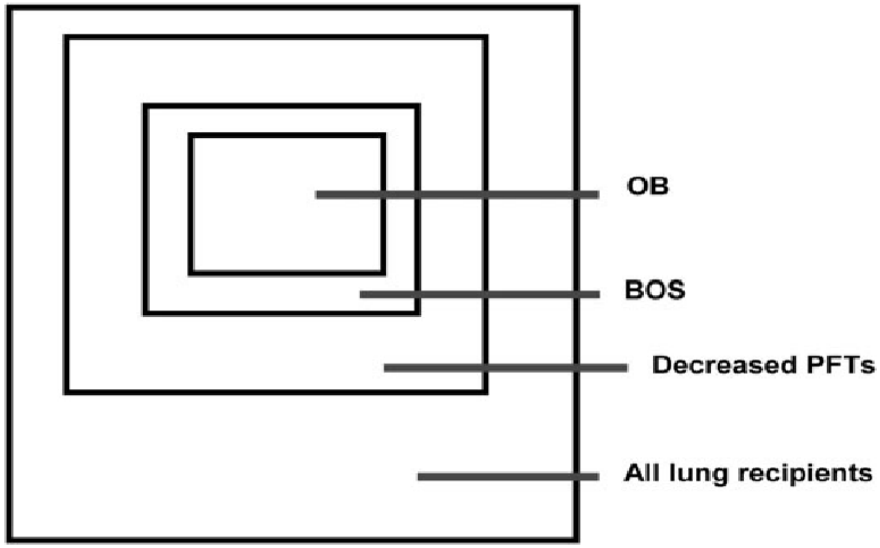

Figure 3. Venn diagram of airway dysfunction after lung transplantation. Schematic representing the relative caliber of the airways, which often presages the fate of lung transplant recipients. Many patients post-transplant will develop airflow obstruction as measured by pulmonary function testing (PFT). This is sometimes related to infection, but often due to development of bronchiolitis obliterans syndrome (BOS). Often, but not always, BOS is associated with histologic demonstration of obliterative bronchiolitis (OB). (Courtesy of Marshall Hertz, M.D., University of Minnesota.)

BO: Histopathologie

BO : stigmate histopathologique commun à plusieurs voies lésionnelles, avec :

- infiltration inflammatoire, nécrose épithéliale, épaississement fibreux de la paroi bronchiolaire.
- oblitération des VA distales
- lésions très hétérogènes (1) (variabilité des réponses aux traitements ?)

(1) Chest 2006, 129:1016

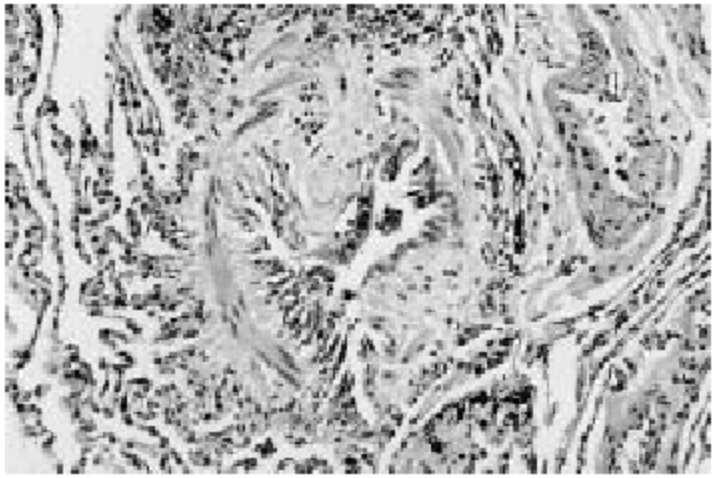

Fig. 7. – A bronchiole showing marked reduction in the lumen due to poorly cellular plaque-like fibrosis internal to the circular muscle. Intact epithelial cells line the residual lumen. A very minimal infiltrate of mononuclear cells is present in the bronchiolar adventitia but no active cellular infiltrates are seen within the lesion itself. Inactive obliterative bronchiolitis. Grade C2. Haematoxylin and eosin.

Obliterative Bronchiolitis (OB)
Pathology

Proliferative

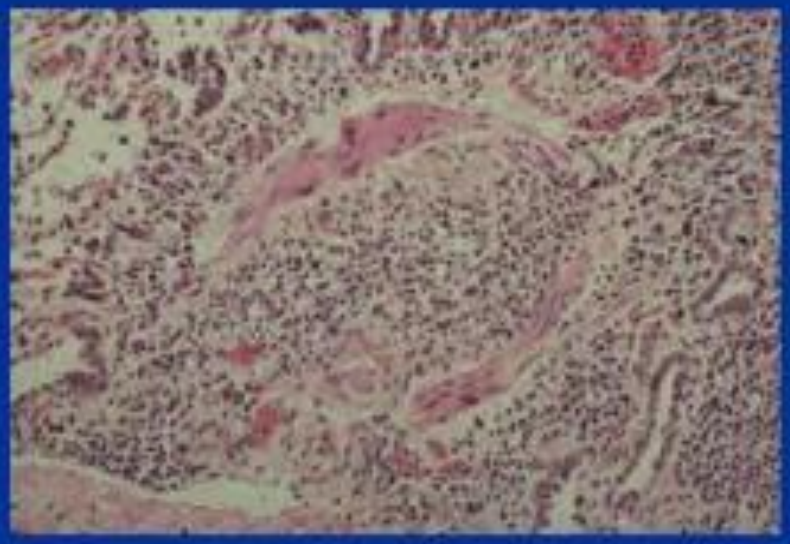

Lymphocytes CD8
Neutrophils
Macrophages

Fibrotic

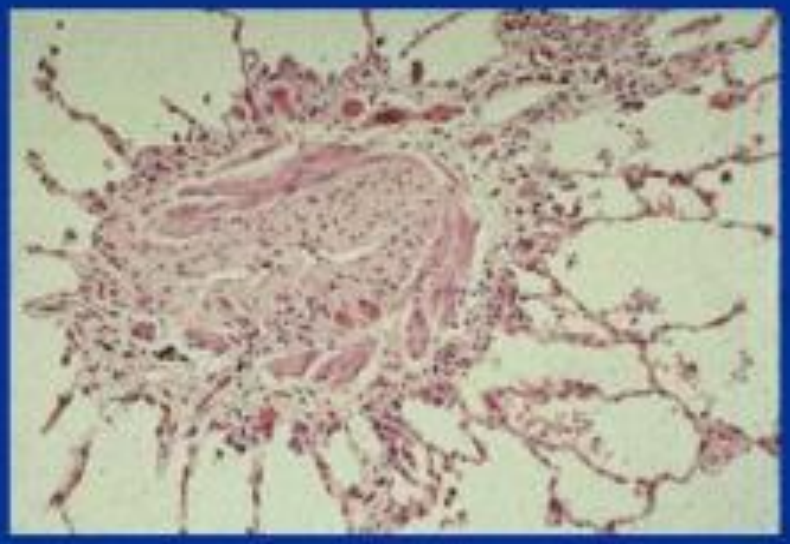

(Myo)fibroblasts
Collagen Deposition
Remodelling

Rejet aigu 1

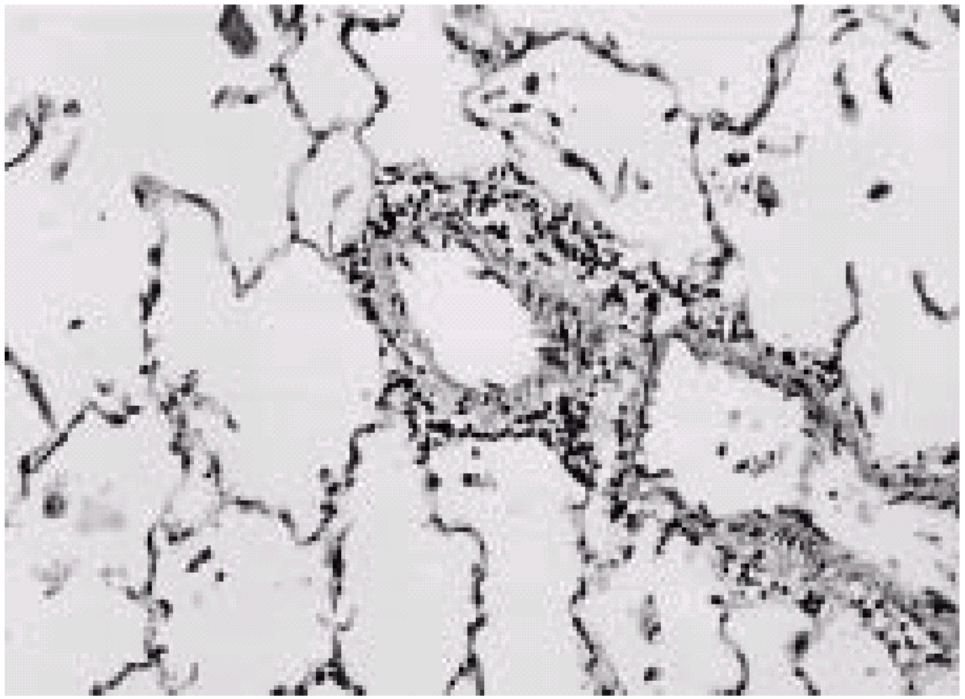

Fig. 1. – High-power view of a perivascular mononuclear cell infiltrate that was not visible at scanning magnification. Grade A1 acute rejection. Haematoxylin and eosin.

Rejet aigu

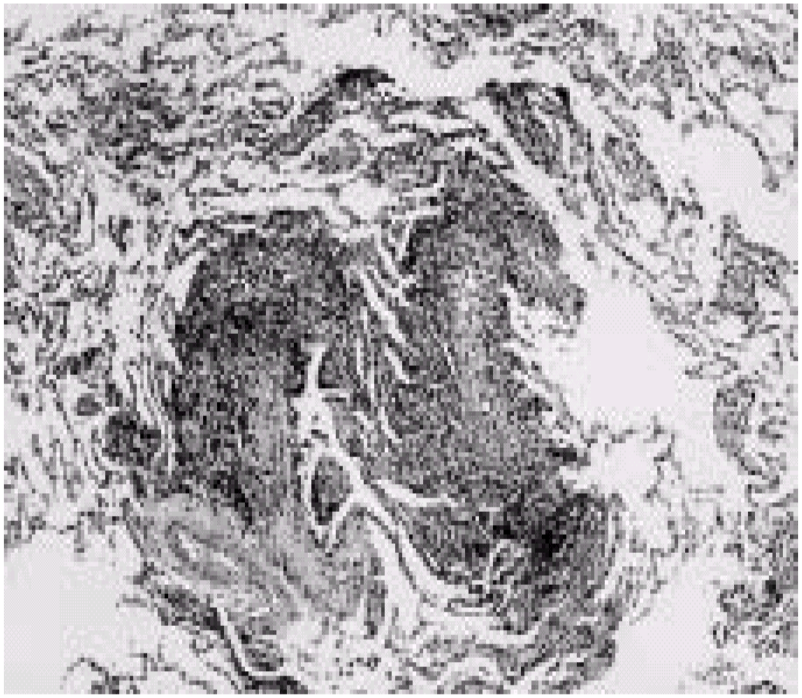

Fig. 3. – Low power view of perivascular infiltrates, dense in nature with extension into alveolar septa and adjacent alveolar spaces. Grade A3 acute rejection. Haematoxylin and eosin.

Rejet aigu bronchiolaire

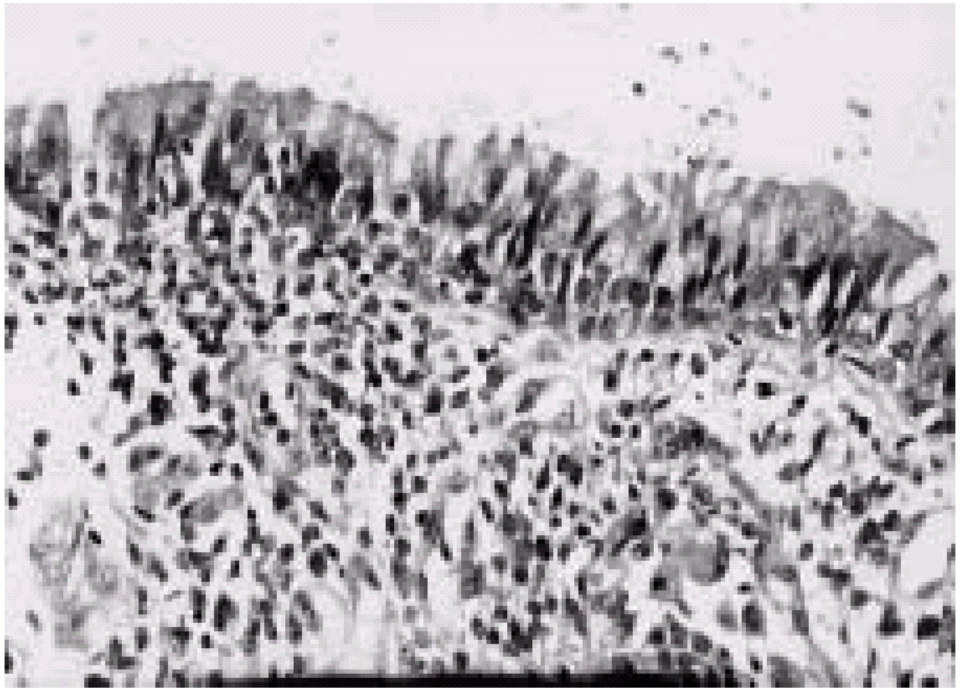

Fig. 5. – Bronchiolar mucosa showing a diffuse infiltrate of lymphocytes in subepithelial tissue and within the epithelium itself. The ciliated respiratory epithelial cells are intact with no evidence of ulceration or metaplasia. Grade B2 acute airways rejection. Haematoxylin and eosin.

FdR Bronchiolite oblitérante RA humoral en TP

-***Peu de séries avec résultats contradictoires:***
= Magro 2002: 22 cas de lésions capillaires septales (nécroses septales, HIA,
dépôt d'AC et activation complément en IF, dépôt de complément dans le noyau
ou cytoplasme des cellules endothéliales), mais SANS AC anti-HLA (AC anti-endothéliaux)

-***Rôle du C4d comme marqueur*** diagnostique du RA humoral controversé en poumon
= Wallace 2005: aucun marquage C4d corrélé au statut (RA ou BO)

- ***Rôle C3d associé à BO ?***
= Magro 2006: Marquage épithélium avec C3d sur l'endothélium des septa et sur l'épithélium bronchique en cas de BO

-***Lien avec le rejet chronique vasculaire ?***

Magro 2006

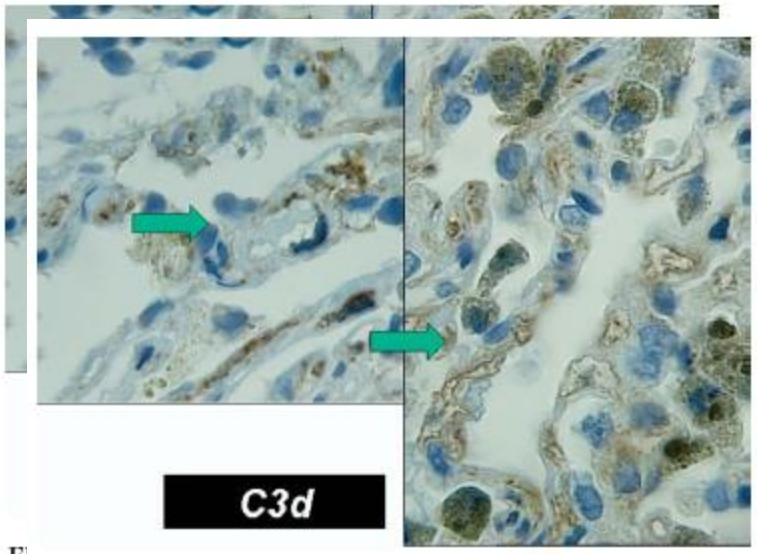

FIGURE 7 Patient 21 is 800 days posttransplantation and developed bronchiolitis obliterans syndrome quite rapidly. The biopsy shows prominent deposition of C3d within the septal microvasculature.

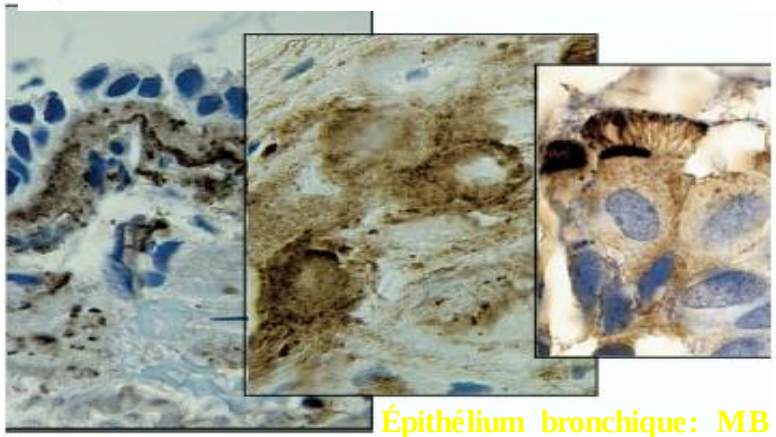

FIGURE 9 Patient 11 was Day 99 posttransplantation and had developed a progressive decrement in his pulmonary function test. Even though at the time of the biopsy, he did not have diagnostic features, at least from a physiologic perspective of bronchiolitis obliterans syndrome (BOS), he had a progressive decline in his forced expiratory volume in 1 s and eventually fulfilled criteria for BOS. There is prominent deposition of C3d within the BMZ, cartilage, and respiratory epithelial cells.

Antibody Mediated Rejection

Girnita et al, Paediatric Transplantation 2006

Development of anti-HLA antibodies associated with:

- High grade and refractory acute vascular rejection
- Lymphocytic Bronchiolitis
- Increased use of Immunosuppression
- BOS development (may preceed BOS by 1 year)

Pathogénie Bronchiolite oblitérante

Modèles animaux

-*TX mono G* sur rats ou cochons (1)

= rejet aigu (lésions chroniques rares)

- *Modèle d'allogreffe de trachée hétérotopique* (rat, souris)

= OAD: « airway obliteration disease » reproductible, proche des lésions de BO chez l'homme, plus aisé, d'apparition rapide

= Biais: dépend exclusivement d'une néovascularisation (ischémie prononcée)

= phases successives: ischémique, perte complète de l'épithélium, infiltration par Lymphocytes, et oblitération fibreuse

(1) Al-Dossari. Ann Thorac Surg 1994; 58: 34

Pathogénie Bronchiolite oblitérante

Modèles animaux

- *Modèle d'allogreffe de trachée hétérotopique* (rat, souris) (1)

= OAD: « airway obliteration disease » reproductible, rejet aigu, proche des lésions de BO chez l'homme

= Biais: dépend exclusivement d'une néovascularisation (ischémie prononcée)

= phases successives: ischémique, perte complète de l'épithélium, infiltration par Lymphocytes, et oblitération fibreuse

(1) Al-Dossari. Ann Thorac Surg 1994; 58: 34

Pathogénie Bronchiolite oblitérante

Modèles animaux:
Démonstration de fibroprolifération

-modèle allogreffe bronchique chez le porc

↗ Cellules type fibroblastes dans paroi bronchique (mRNA procollagène type I et III positif) (1)

-Médiateurs de fibro prolifération augmentés si BO: PDGF , VEGF, fibroblast growth factor, TGF- béta, insulin-like growth factor (IGF)-1 (2).

(1) Alho AJRCCM 2001; 164: 1519. (2) Aris. AJRCCM 2002; 166: 417.

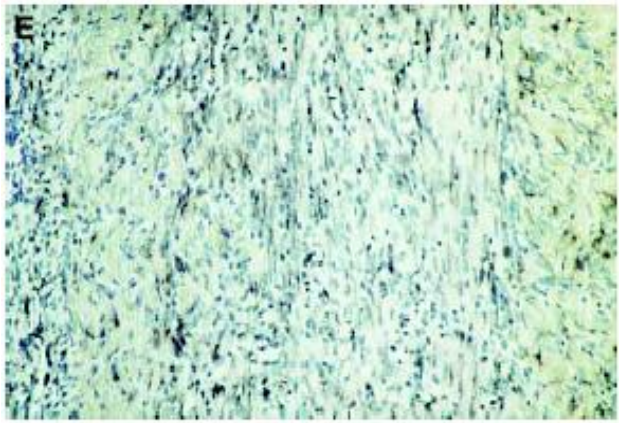

the increased number of cells expressing type III collagen mRNA in the respective areas (*E*) and (*F*) (original magnification: ×20).

Collagens I and III in a Porcine Bronchial Model of Obliterative Bronchiolitis

HANNI S. ALHO, KAIJA A. INKINEN, ULLA-STINA SALMINEN, PAULA K. MAASILTA, EERO I. TASKINEN,

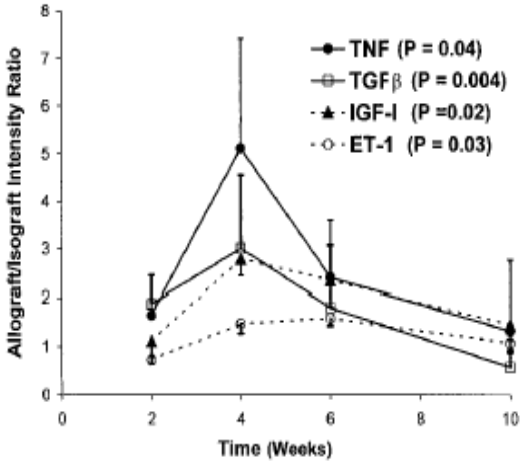

Figure 3. Allograft/isograft intensity ratios (mean ± SEM) of the PCR products during the evolution of OB showing significant upregulation of TGF-β, TNF-α, IGF-1, and endothelin-1 (ET-1). Growth factor data are corrected for actin.

Pathogénie Bronchiolite oblitérante

Modèles animaux (rat, souris)

-modèles d'allogreffe trachéale = OAD immune, mais des facteurs non immuns (protéases dénudant l'épithélium) provoquent des OAD (1)

-Perte membrane basale + bronchiolite lymphocytaire, précurseur de la BO (2).

-Cellules infiltrantes: Ly CD8+> CD4+, NK, Macro, Et plus tard myofibroblastes

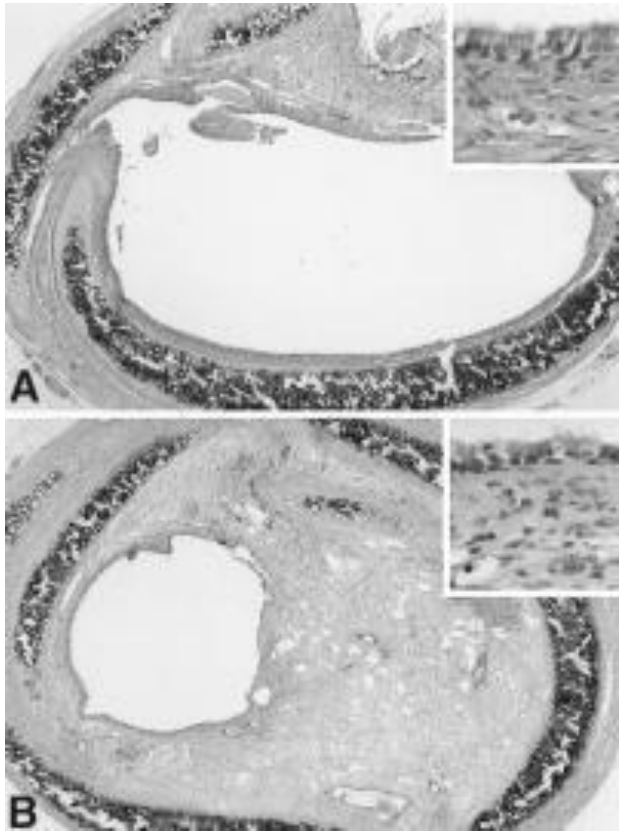

Figure 1. (A) Denuded/reseeded tracheal graft showing minimal eccentric narrowing at the noncartilaginous segment (H&E; original magnification, × 40). (Inset) The airway is covered by ciliated respiratory epithelium (H&E; original magnification, ×400). (B) Denuded tracheal graft showing greater than 50% luminal obliteration by fibrous connective tissue (H&E; original magnification, ×40). (Inset) The airway is covered by ciliated respiratory epithelium (H&E; original magnification, ×400).

(1) Adams. Transplantation 2000; 69:311 . (2) Boehler A. Transplantation 1997; 64: 311. Am J Translant 2005; 5: 131

Pathogénie Bronchiolite oblitérante

Modèles animaux:
-Reconnaissance CMH Classe I et II, lésions d'OAD
avec 1 seul HLA-mismatch Classe I (1)

-Implique Costimulation des lymphocytes par 2ème signal dont l'inhibition induit une tolérance
= CTLA-4Ig inhibe le signal de la voie CD28/B7 (molécule de costimulation) diminue de 50% l'oblitération de l'OAD (3)

= le blocage de la costimulation CD40-CD154 dans un modèle d'allogreffe supprime le rejet(4)

(1)Smith Transplantation 2002; 73: 186 *(2) Szeto J Thorac Cardiovac Surg 2000; 120: 1070* (3)Yamada. Transplantation 2000; 69: 743. (4) Rumbley. Transplantation 2001

Pathogénie Bronchiolite oblitérante

Etudes cliniques humaines

Etude prospective (29 patients, 3 ans, LBA, BB et BTB sériés)

LBA : infiltration +++ de CD8 +, et persistante de CD4 +.

Bronches : infiltration de CD3+ et de CD8+, augmentant avec le temps chez patients stables, et chez BO +

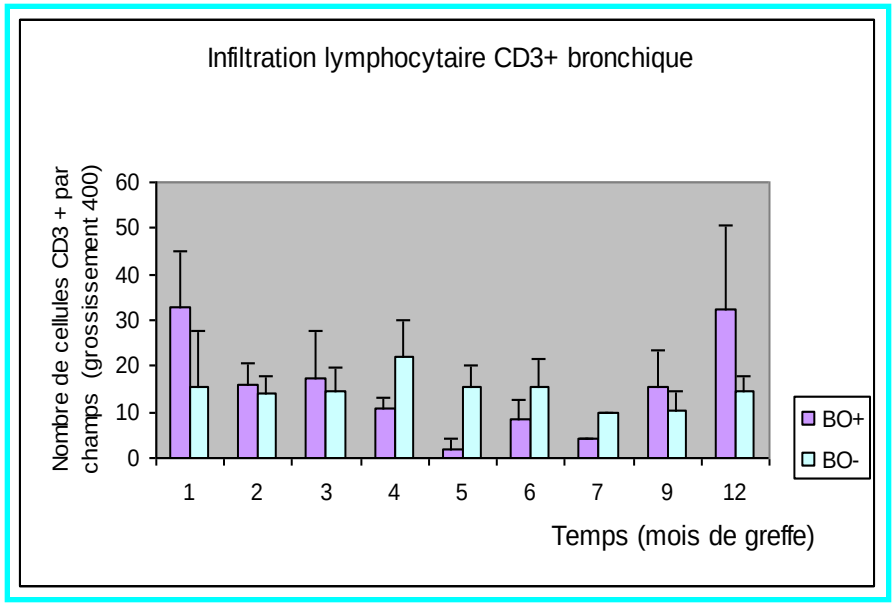

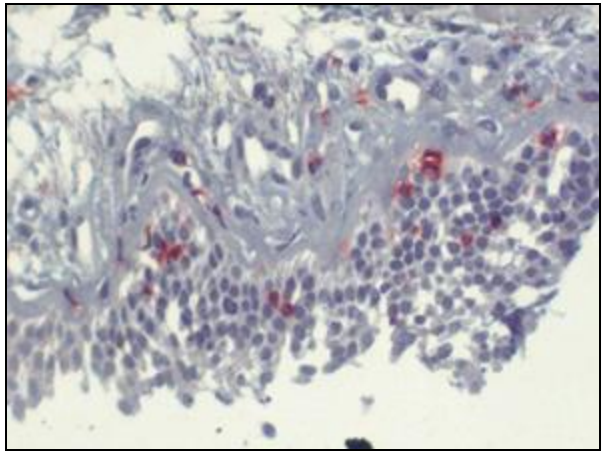

CD8