Maladies Kystiques Pulmonaires

Abdellatif Tazi
Service de Pneumologie
Hôpital Saint-Louis, Paris, France

abdellatif.tazi@aphp.fr

Pas de conflit d’intérêt

Plan

- Définitions

- Démarche diagnostique
  - PID avec kystes associées
  - PID nodulo-kystiques
  - PID kystiques « pures »

- Synthèse

Définitions

- Diagnostic positif et caractérisation
  - TDM-HR pulmonaire ++

- Kyste
  - Hyperclarté parenchymateuse entourée d'une paroi fine: < 2mm
    peut contenir du liquide ou du matériel solide

- Bulle: taille > 1cm, paroi < 1mm
- Bleb: bulle de taille < 1cm , sous pleurale ou pleurale, apicale
- Pneumatocèle: paroi fine, contexte, le plus souvent résolutif

- Cavité
  - Hyperclarté parenchymateuse entourée d'une paroi épaisse: > 4mm
  - (condensation, masse, nodule) cavitaires

- Différencier de:
  - emphysème, bronchectasies kystiques
  - rayon de miel
  - miniMIP, expiration, reconstructions

Kystes

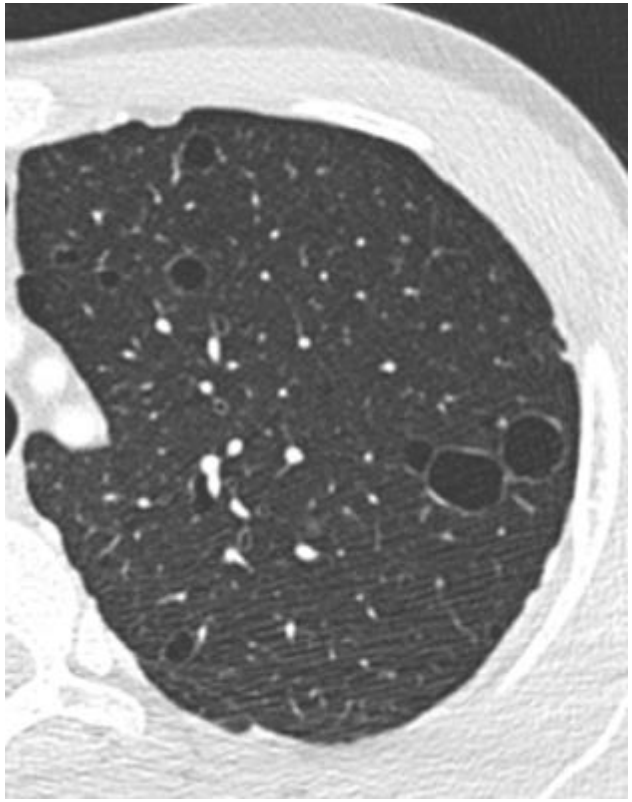

Bulles

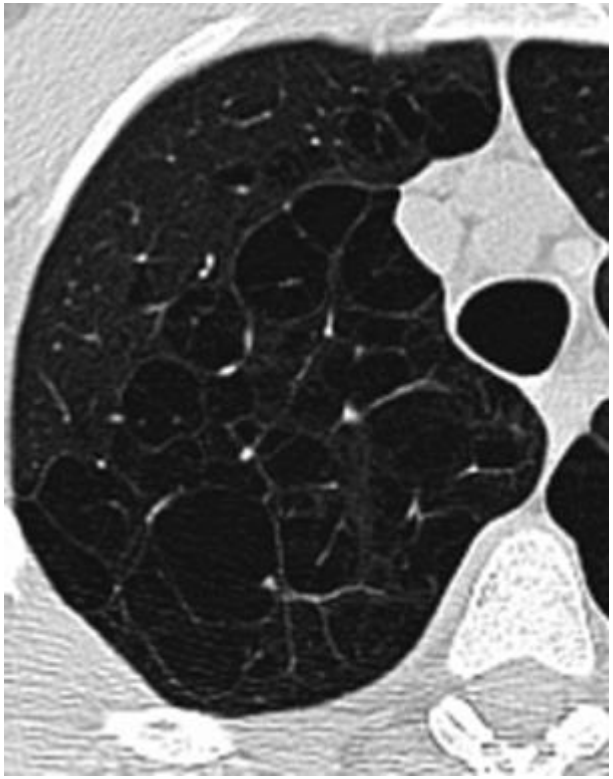

Cavités

PID Kystiques
Première approche

Diffuse Cystic Lung Disease at High-Resolution CT

Langerhans cell histiocytosis

Lymphangioleiomyomatosis

- Sporadic
- Associated with tuberous sclerosis complex

Follicular bronchiolitis and LIP

Amyloidosis, LCDD

Birt-Hogg-Dubé syndrome

Cystic metastases

Seaman et al. AJR 2011

- Analyse radiologique
  - distribution
  - anomalies associées
  - imagerie antérieure++
  - séquence évolutive

Kystes pulmonaires associées à une PID

Kystes ne sont pas la lésion prédominante

- Pneumopathie interstitielle lymphoïde (LIP)
  - Sjögren
  - Autres causes de LIP
- Pneumopathies d'hypersensibilité (PHS)
- Pneumopathie infiltrante macrophagique
  - RB/ILD-DIP (parfois HL sous-jacente)
- Pneumocystose
- Raretés
  - Tumeurs (sarcomes…..)
  - Niemann Pick B, mastocytose…
  - …Covid19
- Diagnostic repose sur autres lésions radiologiques, LBA, contexte

Angiosarcome du scalp métastatique

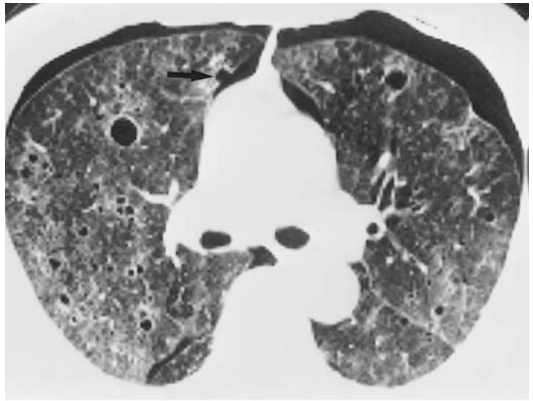

LIP-Sjögren

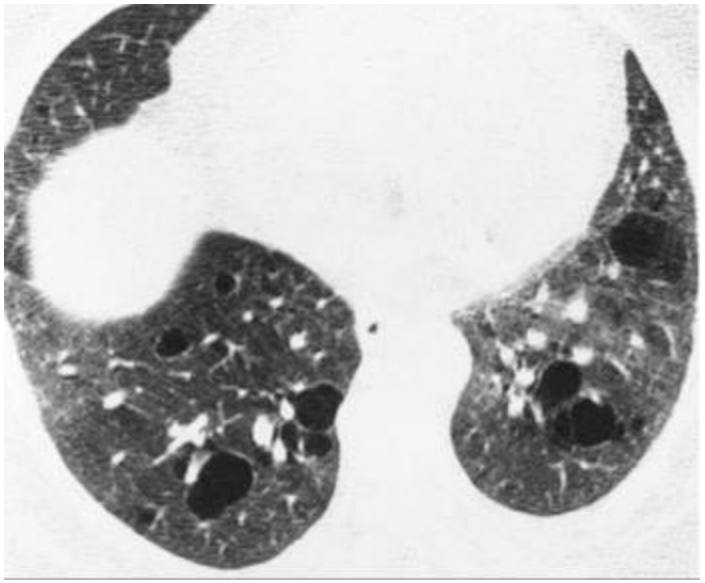

PHS

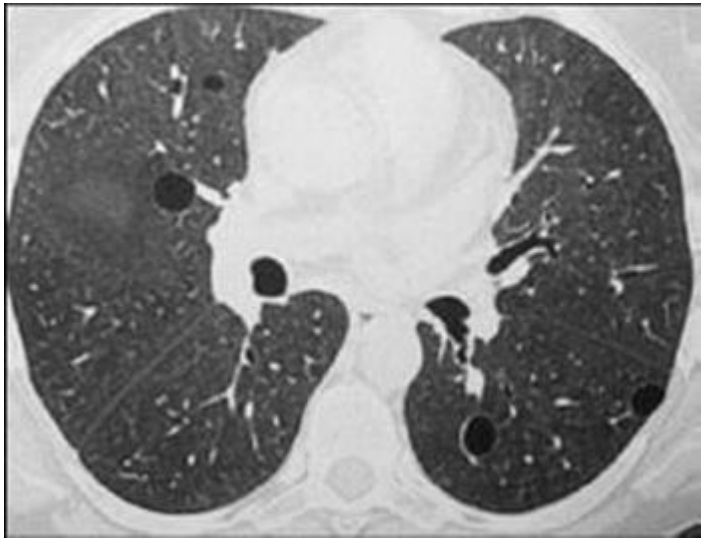

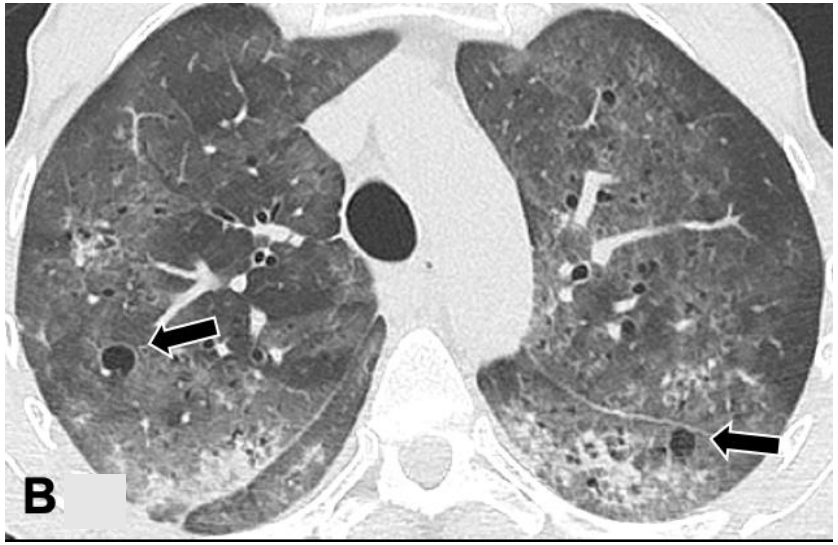

Pneumocystose

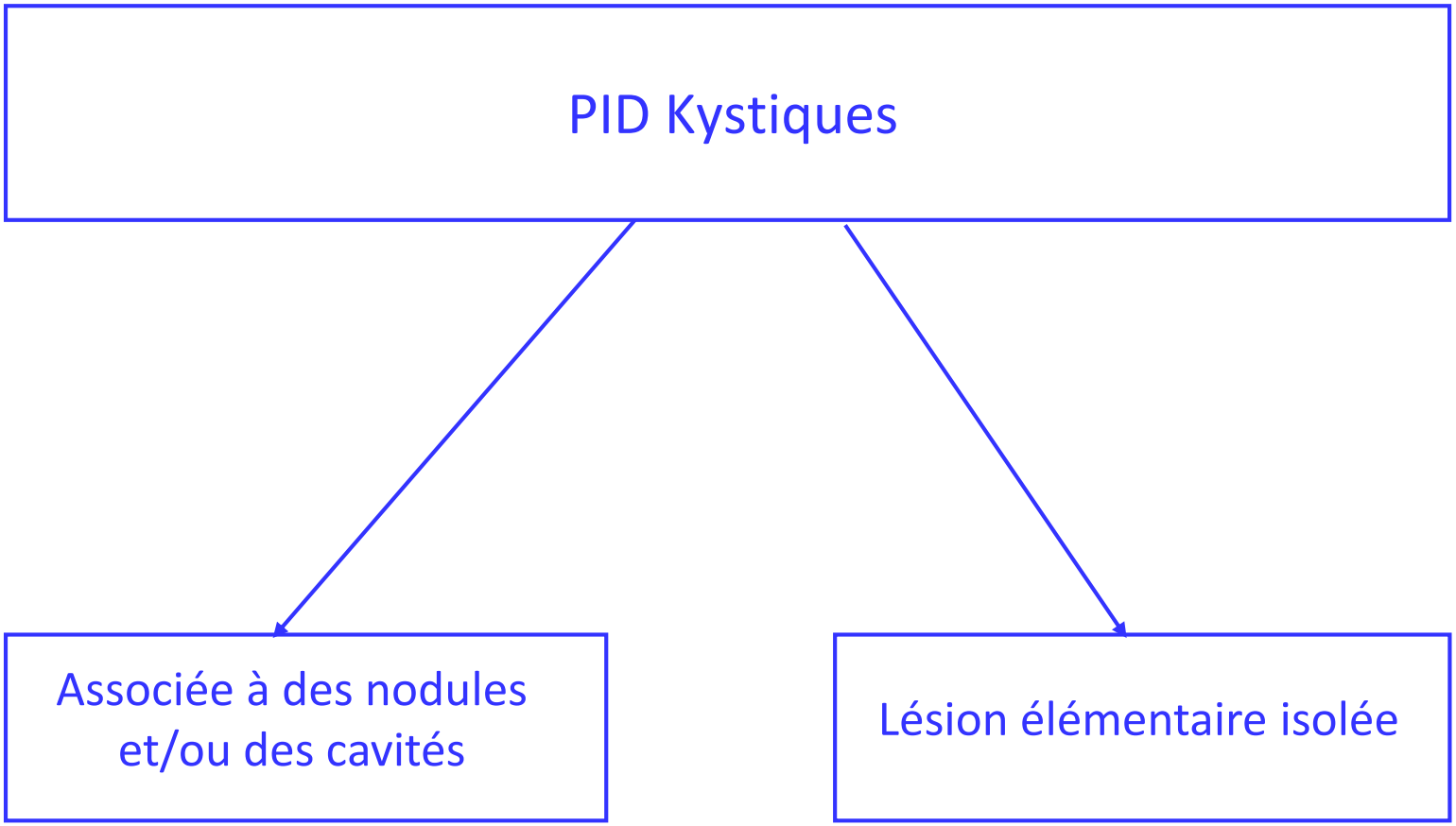
PID Kystiques
Associée à des nodules et/ou des cavités
Lésion élémentaire isolée

Kystes associées à des nodules et/ou cavités pulmonaires

- Infections
  - mycobactéries, mycoses endémiques (histoplasmose, coccidioidomycose…..)
  - *pneumocystis jiroveci ++*
- HL pulmonaire
- Métastases pulmonaires de certains cancers
- Amylose, dépôts de chaines légères
- ….
- (micronodules d'hyperplasie PII dans LAM/STB)
- Éléments d'orientation
  - tabac
  - pathologie connue (tumeur, hémopathie)
  - signes généraux
  - signes extra-thoraciques
  - immunodépression (lymphocytes sanguins), EPP
  - LBA

Histiocytose Langerhansienne

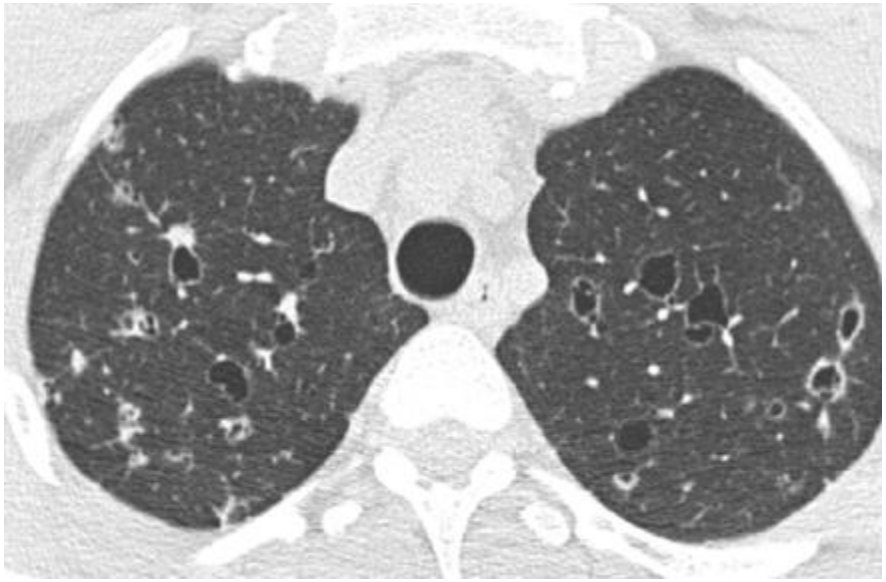

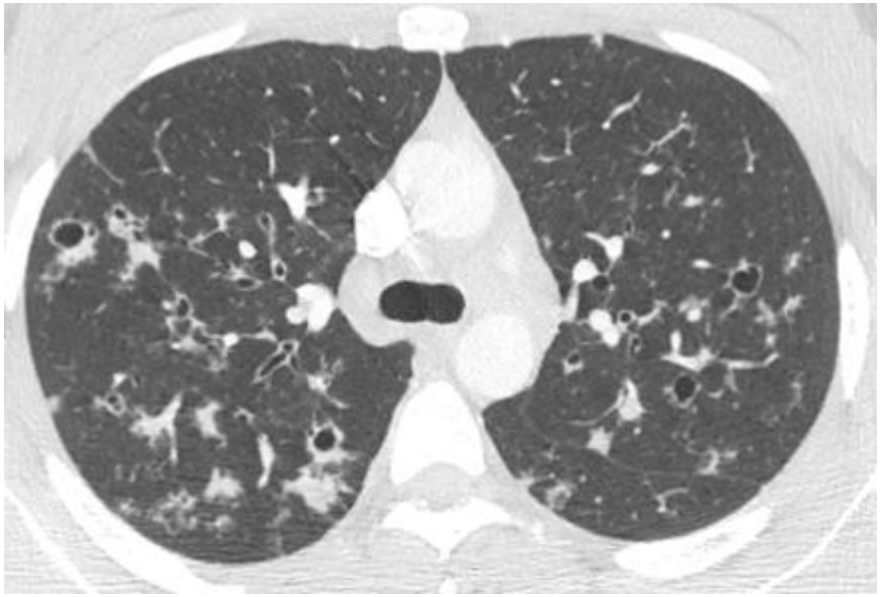

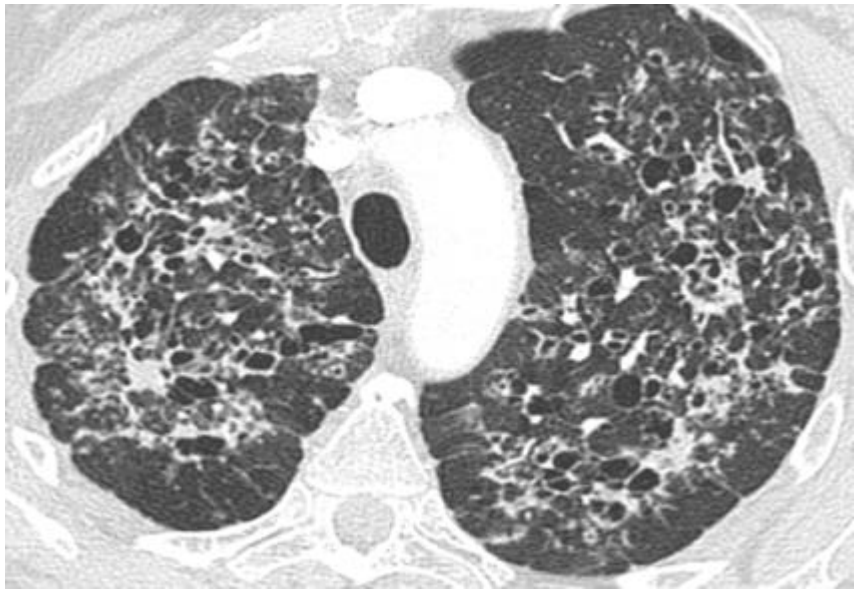

Pneumocytose

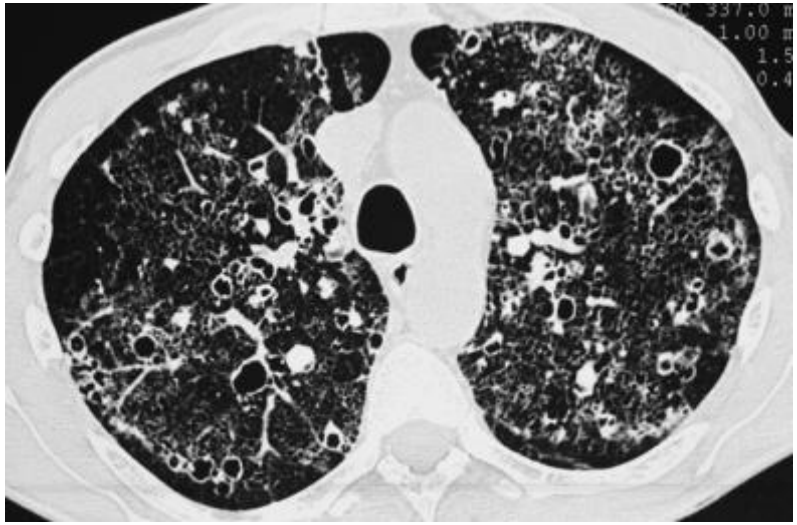

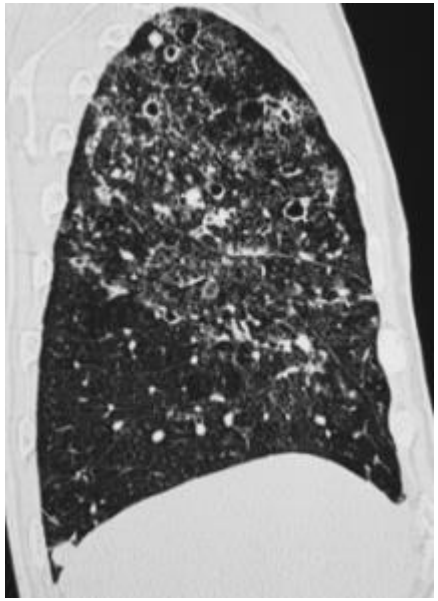

Métastases d'ADK colique

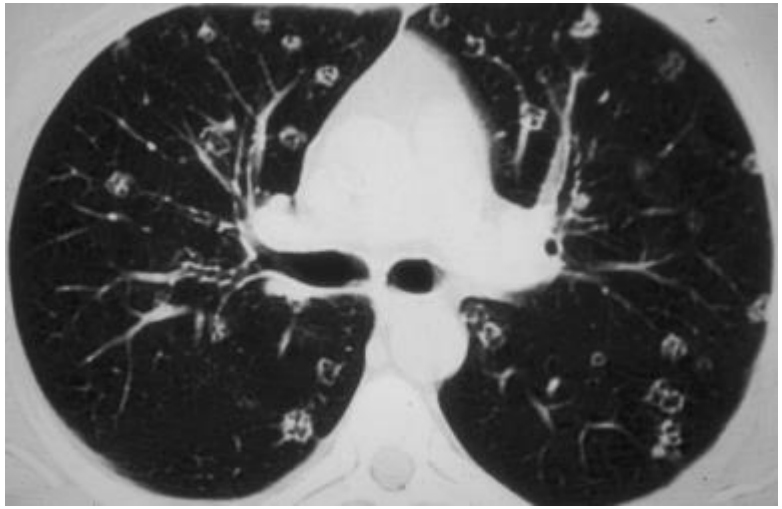

ADK pulmonaire

Sjögren + LIP + amylose + prolifération lymphoïde

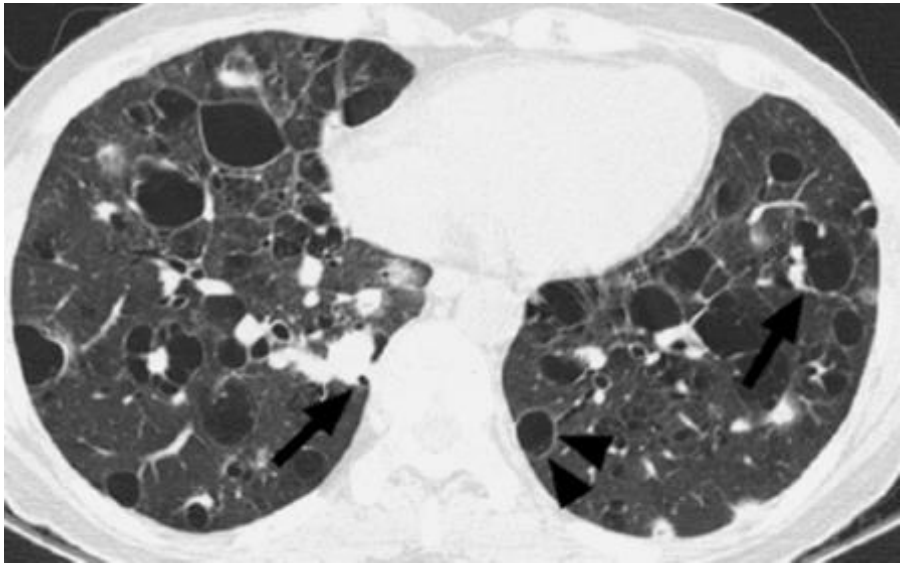

Pathologie pulmonaire kystique diffuse
Kystes seules lésions élémentaires

- Vieillissement pulmonaire (≤ 5 kystes, >50 ans)
- Pièges diagnostiques
  - emphysème
  - bronchectasies
- Lymphangioléiomyomatose pulmonaire (LAM)
  - sporadique
  - sclérose tubéreuse de Bourneville
- Histiocytose Langerhansienne pulmonaire (HL)
- Syndrome de Birt-Hogg-Dubé (BHD)
- Dépôts de chaines légères
- *LIP*
- Raretés
  - *cancers (sarcomes, ORL, autres..)*
  - *amylose*
  - neurofibromatose…….GATA-2, …polykystose…papillomavirus…
  - (syndrome de Marfan……)
    - ✓ bulles d'emphysème plus que kystes
  - ….

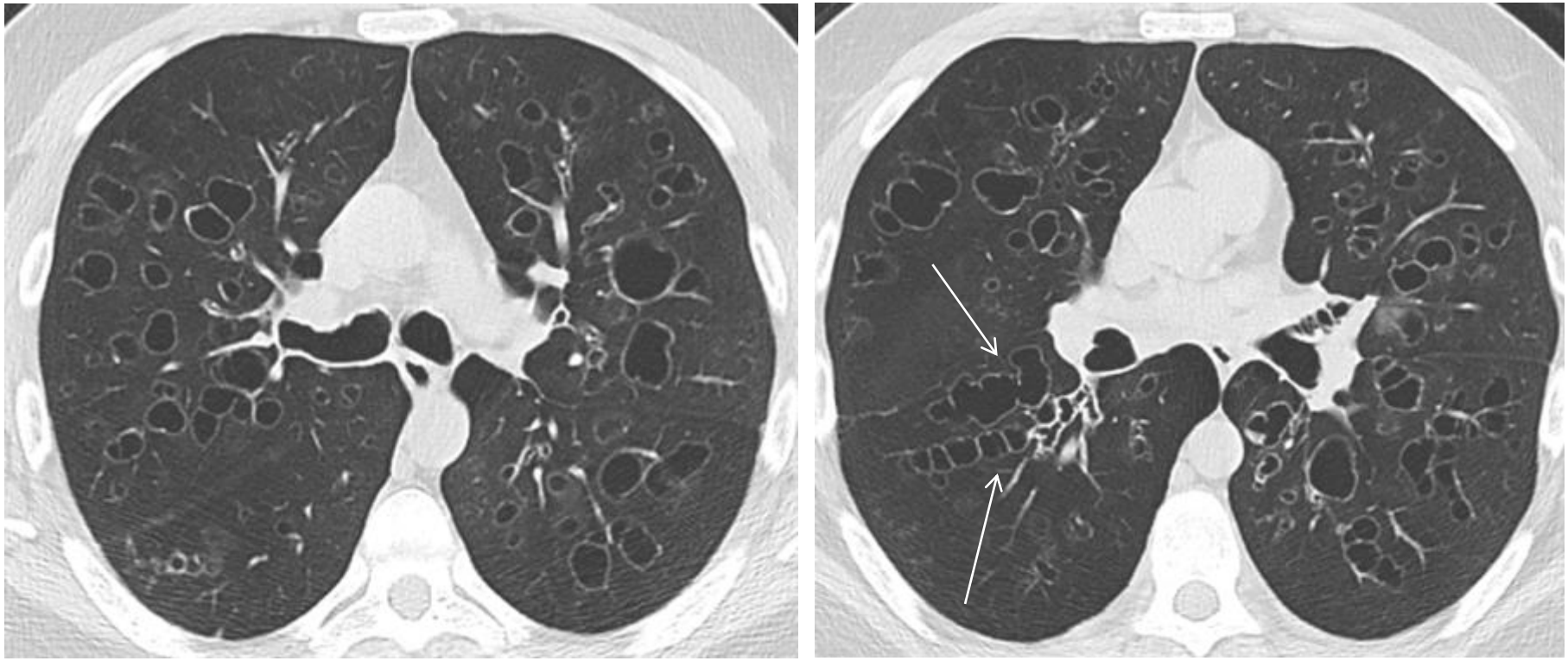

Bronchectasies

Lymphangioléiomyomatose (LAM)

- Pathologie rare de la femme jeune
  - médiane 35 ans
  - âge plus élevé dans séries récentes
  - cas post ménopausiques
- Dyspnée d'effort, toux
- PNO récurrent ++
- Hémoptysie, chylothorax, chyloptysie
- Atteintes extra thoraciques
  - formes sporadiques
  - sclérose tubéreuse de Bourneville
- EFR:
  - TVO (réversible), piégeage aérique, altération de la DLC0

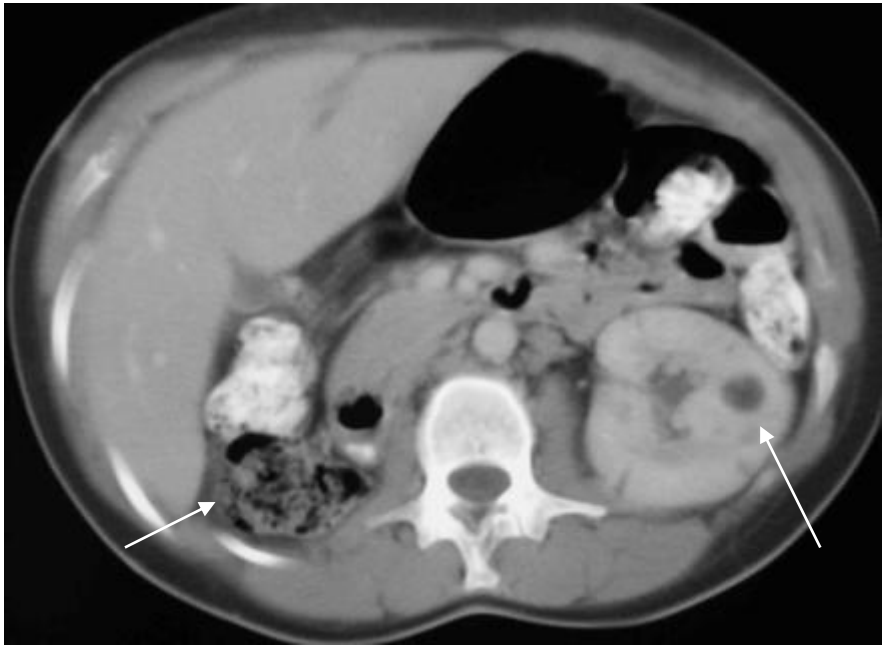

Tuberous sclerosis

Panel: Diagnostic criteria for tuberous sclerosis[7]

Major features

- Facial angiofibromas or forehead plaque pits in dental enamel
- Non-traumatic ungula or periungual fibroma
- Hypomelanotic macules (three or more)
- Shagreen patch (connective tissue nevus) migration lines
- Multiple retinal nodular hamartomas
- Cortical tuber
- Subependymal nodule
- Subependymal giant-cell astrocytoma
- Cardiac rhabdomyoma, single or multiple
- Lymphangiomyomatosis, renal angiomyolipoma, or both

Minor features

- Multiple, randomly distributed
- Hamartomatous rectal polyps
- Bone cysts
- Cerebral white matter radial
- Gingival fibromas
- Non-renal hamartoma
- Retinal achromic patch
- Confetti-like skin lesions
- Multiple renal cysts

Curatolo et al. Lancet 2008

Angiofibromes

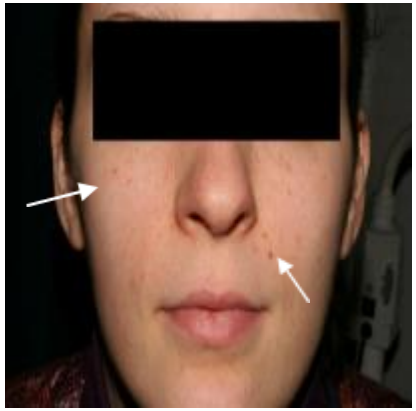

Plaques peau de chagrin

Fibromes péri-unguéaux

Anomalies de l'émail dentaire

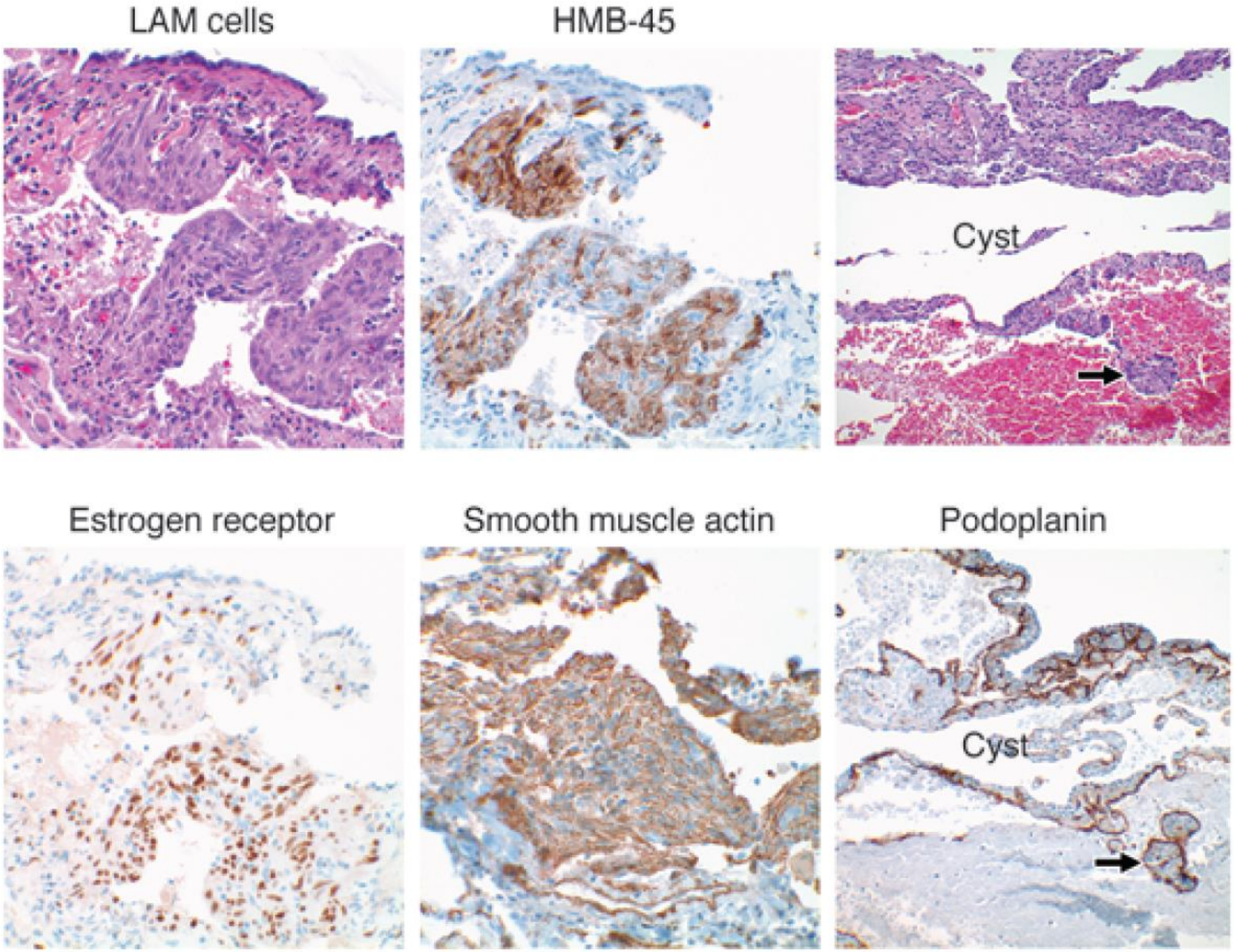

Henske & McCormack JCI 2012

Serum Vascular Endothelial Growth Factor-D Prospectively Distinguishes Lymphangioleiomyomatosis From Other Diseases

Young et al Chest 2010

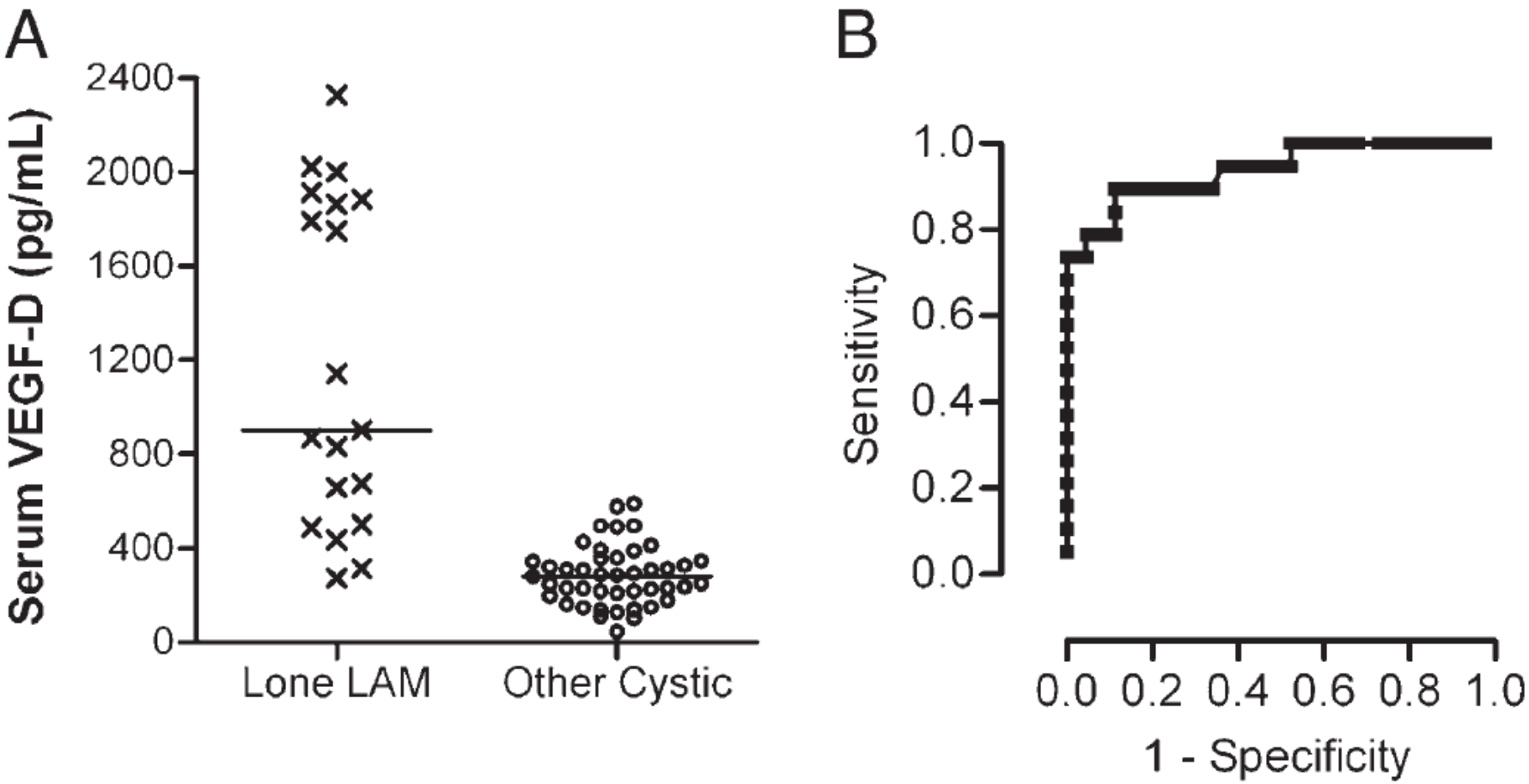

LAM is a multisystem disorder that affects the lungs, pleural space, kidney, liver, lymphatics, and uterus

	TSC-LAM	S-LAM
Lung cysts	Often mild	Often profuse
Elevated serum VEGF-D	100%	70%
Chylous pleural effusion	10%	30%
Pneumocyte hyperplasia	12%	0%–1%
Abdominal lymphangioleiomyoma	9%	29%
Renal angiomyolipoma	93%	32%
Single	0%	46%
Bilateral	92%	19%
Uterine PEComas	100%	70%

Henske & McCormack JCI 2012

McCarthy C et al. Lancet Respir Med 2021

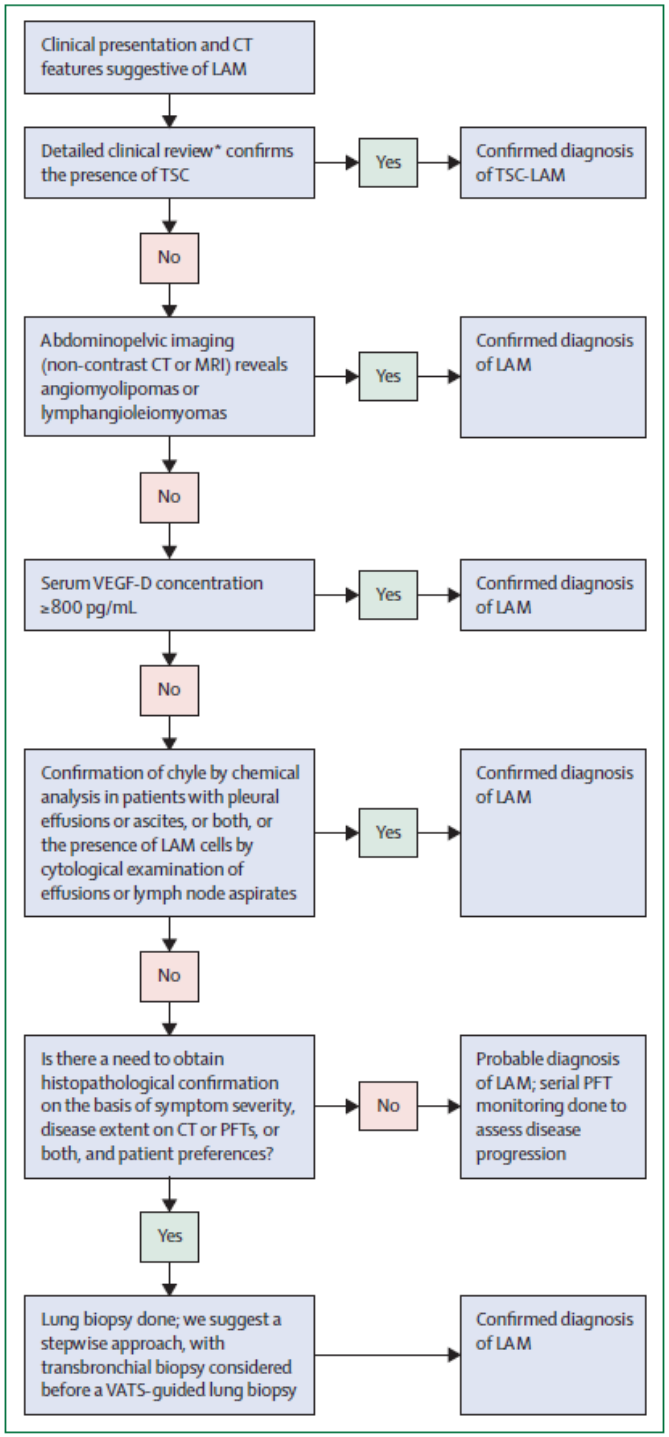

LAM
Evolution et pronostic

- Pathologie lentement progressive
  - 50% dyspnée mMRC3, 10 après début des symptômes
    - avant inhibiteurs de mTOR
  - Déclin annuel du VEMS 89 +/- 53 ml
    - plus rapide dans formes pré-ménopausiques
    - VEMS
      - 200 ml *vs* 40 ml/an
      - 118 *vs* 74 ml

- Médiane de survie: >20 ans après diagnostic
  - Survie sans transplantation: 85% à 10 ans, 64% à 20 ans
  - Age préménopause, VEMS, DLCO, VEMS/CVF bas
    - moins bon pronostic

McCarthy et al. Lancet Respir Med 2021

Lymphangioleiomyomatosis — a wolf in sheep's clothing

JCI 2012

Elizabeth P. Henske[1] and Francis X. McCormack[2]

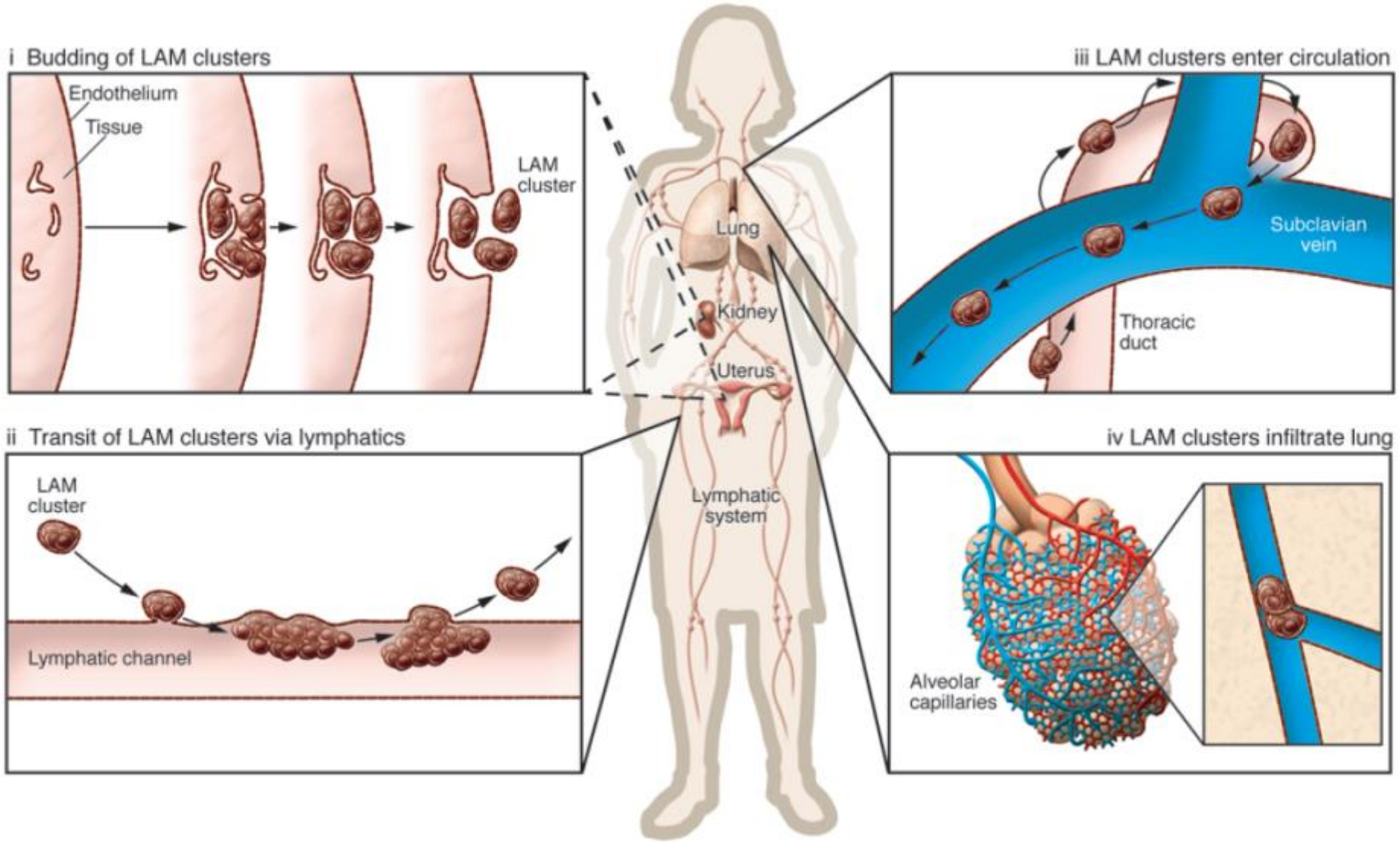

Lymphangioleiomyomatosis — a wolf in sheep's clothing

JCI 2012

Elizabeth P. Henske[1] and Francis X. McCormack[2]

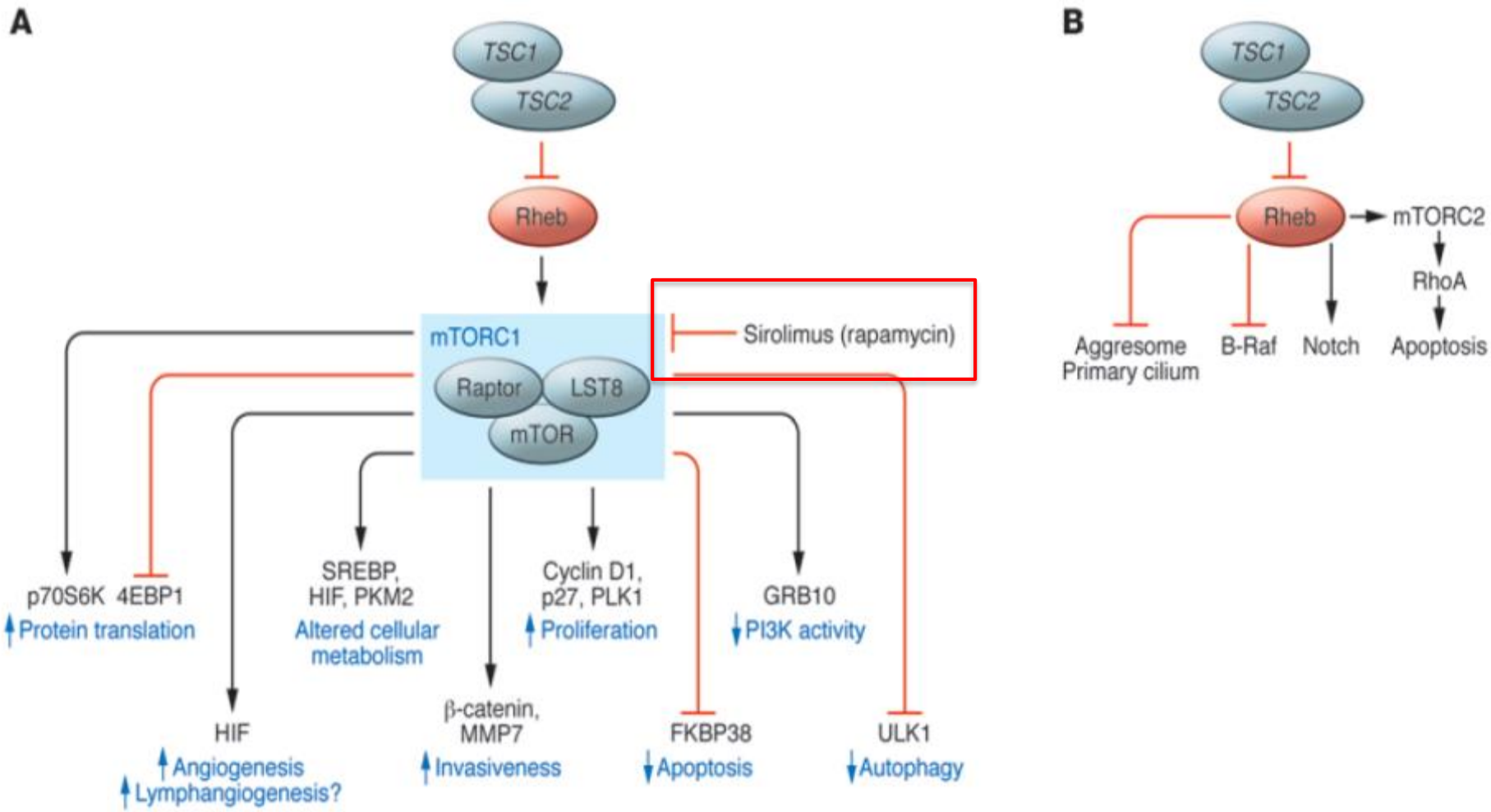

The NEW ENGLAND JOURNAL of MEDICINE

Efficacy and Safety of Sirolimus in Lymphangioleiomyomatosis

McCormarck et al. 2011

A

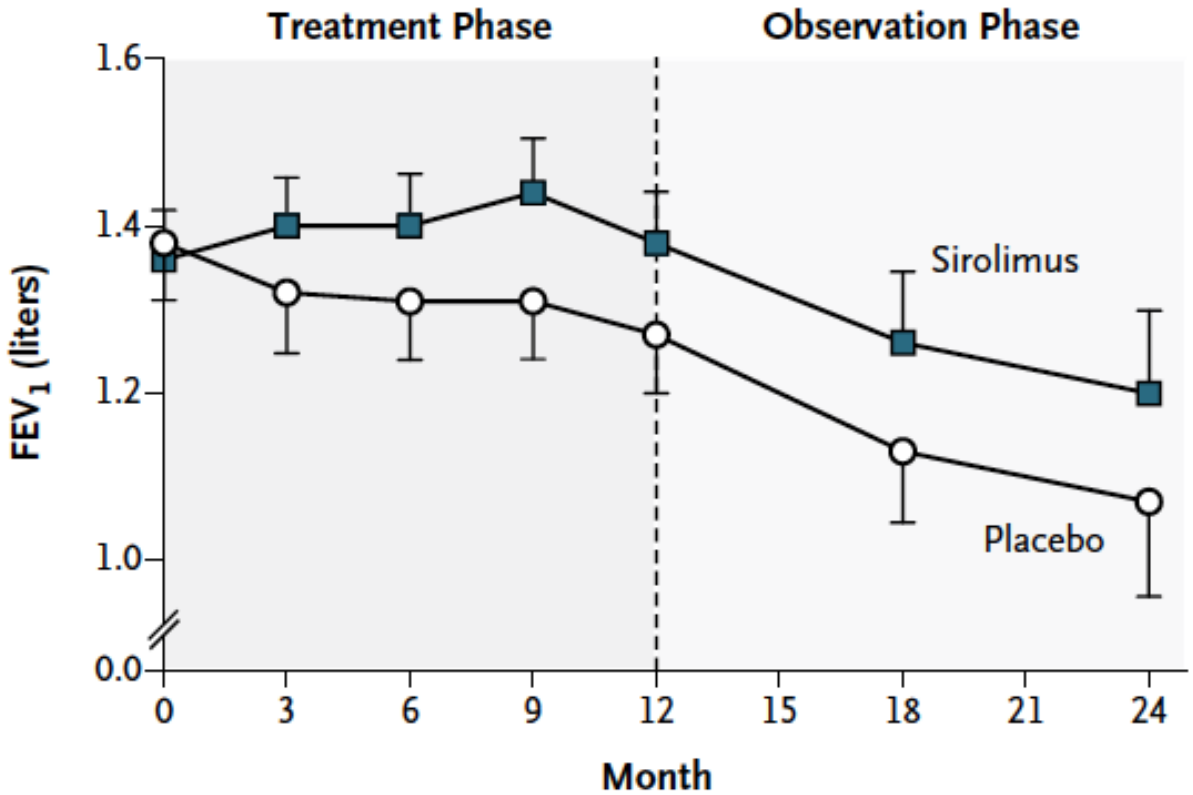

No. at Risk

Sirolimus	46	43	41	38	41	21	14
Placebo	43	40	42	39	34	22	13

Everolimus for angiomyolipoma associated with tuberous sclerosis complex or sporadic lymphangioleiomyomatosis (EXIST-2): a multicentre, randomised, double-blind, placebo-controlled trial *Bissler et al. Lancet 2013*

Everolimus for the treatment of lymphangioleiomyomatosis: a phase II study *Goldberg et al. Eur Respir J 2015*

Sustained Effects of Sirolimus on Lung Function and Cystic Lung Lesions in Lymphangioleiomyomatosis *Yao et al. AJRCCM 2014*

Long-term efficacy and safety of sirolimus therapy in patients with lymphangioleiomyomatosis *Hu et al. OJRD 2019*

Impact of Age, Menopause, and Sirolimus on Spontaneous Pneumothoraces in Lymphangioleiomyomatosis *Cortinas et al. Chest 2022*

Sirolimus reduces the risk of pneumothorax recurrence in patients with lymphangioleiomyomatosis: a historical prospective self-controlled study *Cheng et al. OJRD 2022*

Prise en charge de la LAM

- Mesures générales (sevrage tabagique, vaccinations, activité physique adaptée, oxygénothérapie)
- Bronchodilatateurs inhalés (réversibilité TVO)
- Pneumothorax: prévention et prise en charge spécifique
  - voyages aériens
- Eviction estrogènes (contraception et post ménopause)
- Grossesse
- Pleurésie chyleuse, angiomyolipomes, lymphangioléiomyomes
- Inhibiteurs de mTOR dans les formes progressives (VEMS<70%)
  - autres voies thérapeutiques à l'étude
- Transplantation pulmonaire (rechutes)
- Prise en charge multidisciplinaire

McCarthy et al. Lancet Respir Med 2021

HL pulmonaire de l'adulte

- PID kystique diffuse rare, sporadique
- Infiltration et destruction de la paroi des bronchioles distales par des cellules *CD1a+/langerine+*
  - atteinte variable des autres compartiments pulmonaires (interstitiel, vasculaire): diversité des phénotypes cliniques
- Sujets jeunes des 2 sexes (20-40 ans)
- >90 fumeurs ou ex-fumeurs
  - ≃20% cannabis (registre CRMR)
- Prévalence inconnue (sous-estimée)
  - ≃3-5% des PID
  - rareté chez les sujets de peau noire
  - bien décrite chez les sujets asiatiques

Vassallo R, Harari S, Tazi A. Thorax 2017

Présentation clinique

- Circonstances de découverte
  - Signes fonctionnels respiratoires (≈ 2/3 des cas)
    - ✓ Toux++, dyspnée d'effort (parfois sifflements respiratoires)
    - ✓ Douleurs thoraciques
    - ✓ Signes généraux associés (≈ 10% des cas, diagnostics ≠)
    - ✓ Hémoptysie signe inhabituel (complication; diagnostic alternatif)
  - Pneumothorax (10-15% des cas)
  - Découverte fortuite
  - Bilan d'une HL extra thoracique

- Examen physique
  - Le plus souvent normal (pas d'hippocratisme digital)
  - Complications (pneumothorax; IRCO ± HTP)
  - *Recherche systématique de localisations extra thoraciques*
    - ✓ Os (lyse), tige pituitaire (diabète insipide central), peau

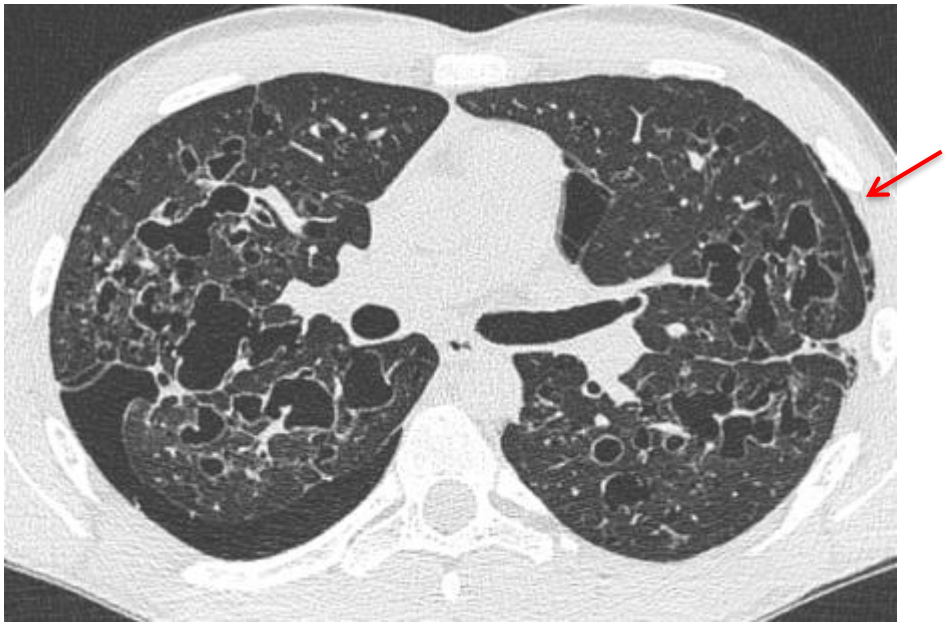

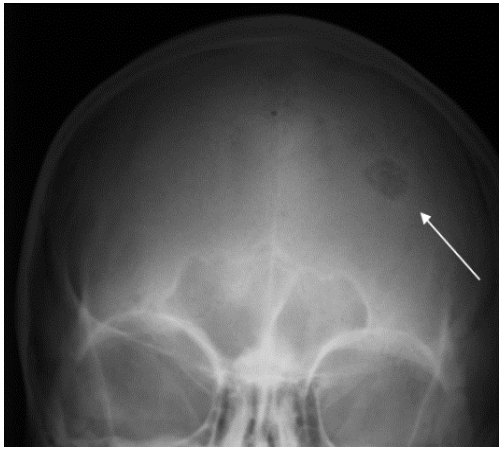

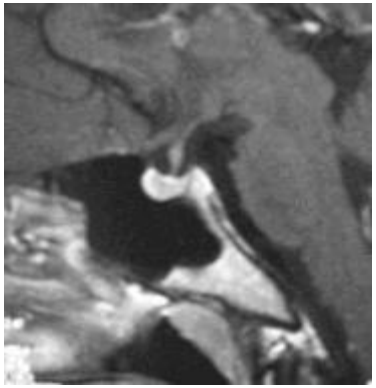

Formes adolescent

HL Pulmonaire de l'Adulte
Fibroscopie bronchique

- Macroscopie: normale ou inflammation
- Biopsies bronchiques: diagnostics ≠
- TBB: rentabilité:15-50%
- Alvéolite macrophagique
  - fonction du tabagisme quotidien
- Hyper éosinophilie modérée (<10%)
- **Pas de lymphocytose**
- Attention CD1a (langerine)
- *Éliminer une infection (signes généraux)*

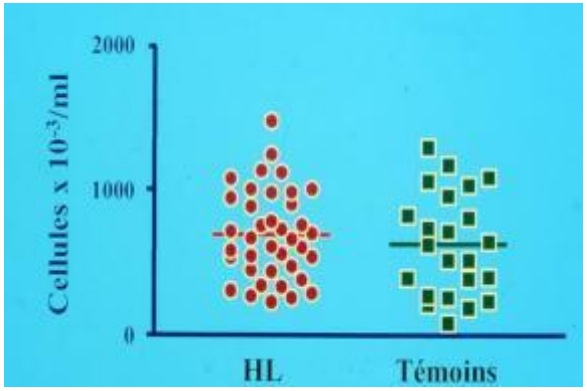

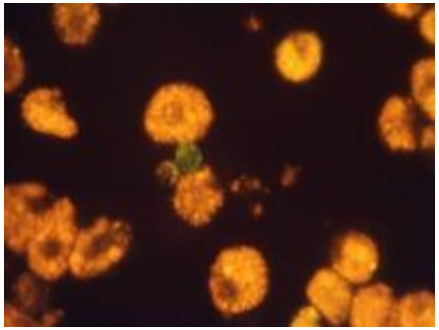

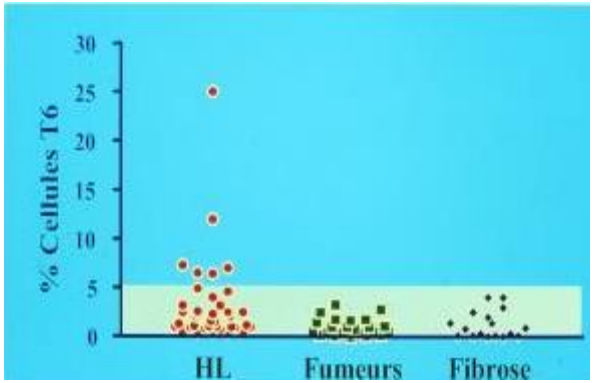

Approche diagnostique

- Diagnostic de certitude= histologique
  - Biopsie pulmonaire chirurgicale guidée par TDM-HR (nodules)
  - Biopsie d'une lésion extra thoracique si tableau radio-clinique caractéristique

- Indication de la biopsie pulmonaire chirurgicale
  - En même temps que symphyse chirurgicale d'un PNO
  - Au cas par cas, expertise
  - Fonction respiratoire++
  - Diagnostic présomptif si contexte clinique et tableau scanographique nodulo-kystique typique

Histologie pulmonaire

- Lésions focales, d'âge différent, bronchiolo-centrées
- Extension aux alvéoles adjacents, artérioles et parfois veinules
- Immuno-histochimie
  - CD1a, langerine (PS100 non spécifique)
- *Génotypage MAPK*

CD1a

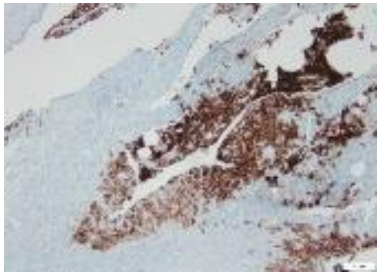

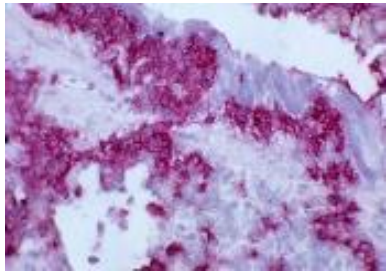

CD1a

H&E

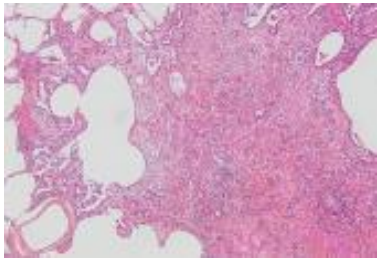

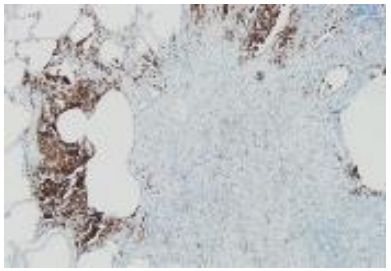

CD1a

H&E

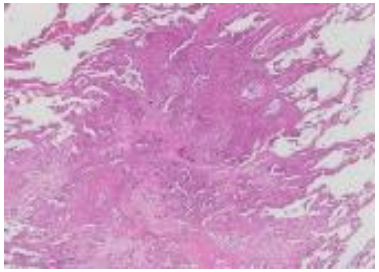



CD1a

Evolution spontanée

- Très variable, difficile à prévoir au diagnostic (sauf HTP sévère)

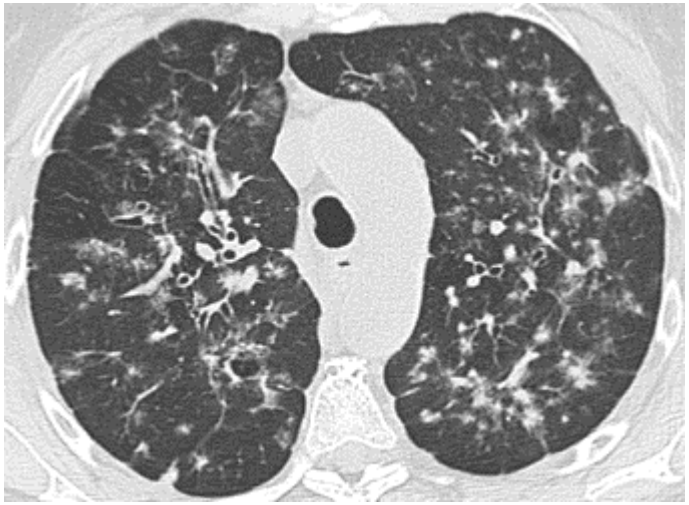

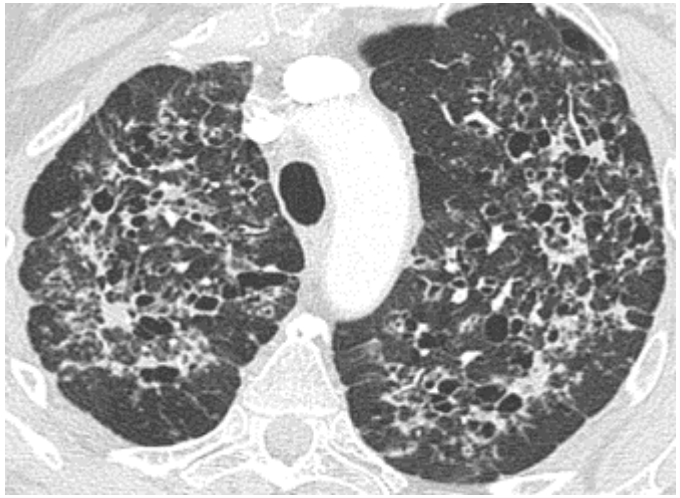

HL Pulmonaire de l'Adulte

Hypertension Pulmonaire

Le Pavec et al. Chest 2012

- Patient de 58 ans, diagnostic histologique par biopsie chirurgicale

	Diagnostic	6 mois	12 mois
Dyspnée NYHA	II	III	III
VEMS	94 %	100 %	98 %
CV	86 %	90 %	101 %
Tiffeneau	77 %	75 %	73 %
TLCO	66 %	39 %	41 %
PaO_2	72 mm Hg	64 mm Hg	53 mm Hg

- Échographie cardiaque : « normale », IT non mesurable
- KT droit : PAPm à 41 mm Hg, IC à 3 l/min/m^2

Long-term outcomes of adult pulmonary Langerhans cell histiocytosis: a prospective cohort

TABLE 1 Characteristics of the pulmonary Langerhans cell histiocytosis (PLCH) patients at the time of diagnosis

Characteristic	
Subjects, n	206
Age, years	39.3±12.8
Sex	
Female	123 (59.7)
Male	83 (40.3)
Smoking status	
Current smokers	196 (95.1)
Ex-smokers	8 (3.9)
Pack-years	21.7±15.9
Non-smokers[#]	2 (1)
Cannabis consumption[¶]	35 (17.0)
Histological diagnosis[+]	66 (32%)
LCH extent	
Isolated PLCH	157 (76.2)
Multisystem PLCH[§]	49 (23.8)
Bone	35
Diabetes insipidus	11
Skin	6
Liver	2
Other[f]	2

Benattia et al. ERJ 2022

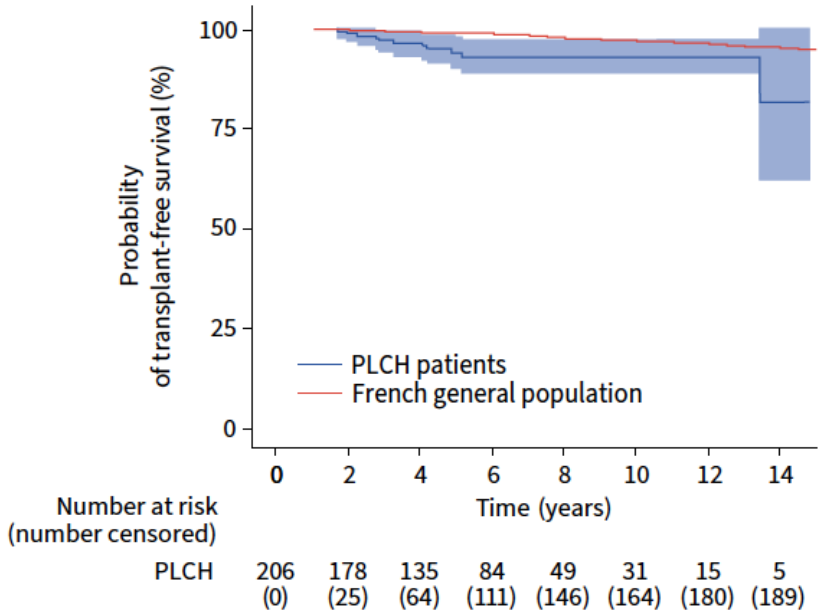

– Multivariate analyses of characteristics of PLCH patients during follow up associated with survival

Parameters	Values	HR	95%CI	pvalue
Age		1.07	(1.01 ; 1.13)	0.017
FEV1		0.96	(0.92 ; 1)	0.046
Smoking status at time t	Non smoker	1.00		
	Smoker	1.54	(0.42 ; 5.6)	0.52
Previous use of Systemic treatment	No	1.00		
	Yes	1.53	(0.36 ; 6.54)	0.57

Benattia et al. ERJ 2022

TABLE 2 Characteristics of the 12 pulmonary Langerhans cell histiocytosis (PLCH) patients who died during the study period

Patient	Age at diagnosis, years	Sex	Smoking status at diagnosis	Pack-years at diagnosis	Extent of LCH	CRF	PH	Time to death, years	Cause of death
1	58	M	Former	20	Isolated	Yes	Yes	13	Lung cancer
2	35	M	Current	10	Isolated	No	No	5	Lung cancer
3	35	F	Current	14	Multisystem	No	No	5	Lung cancer
4	49	F	Former	20	Isolated	No	No	2	Lung cancer
5	33	M	Current	30	Isolated	Yes	Yes	2	Respiratory failure
6	47	M	Current	80	Isolated	Yes	Yes	2	Respiratory failure
7	48	M	Current	30	Isolated	Yes	Yes	4	Respiratory failure
8[#]	38	F	Former	20	Multisystem	Yes	Yes	4	Pulmonary mucormycosis
9[¶]	72	F	Current	50	Isolated	Yes	Yes	4	CMML
10	49	F	Current	60	Isolated	No	Yes	3	Acute coronary syndrome
11	79	M	Former	60	Multisystem	No	No	3	Bacterial pneumonia
12	87	M	Non-smoker	0	Multisystem	No	No	2	Heart failure

Benattia et al. ERJ 2022

Cladribine dans l'HL pulmonaire

- 2-CDA: analogue des purines
- 2ème ligne de traitement de l'HL systémique
- Toxique pour monocytes et lymphocytes quiescents
- Très immunosuppresseur (lymphopénie prolongée)
- Plusieurs cas cliniques rapportés:
  - *Aerni et al. Respir Med 2008*
  - *Lazor et al. Thorax 2009*
  - *Lorillon et al. Am J Respir Crit Care Med 2012*
  - *Grosbost et al. Orphanet J Rare Disease 2014*
  - *Epaud et al. Eur Respir J 2015*
  - *Nasser et al. ERJ Open Res. 2018*

Cladribine Is Effective against Cystic Pulmonary Langerhans Cell Histiocytosis

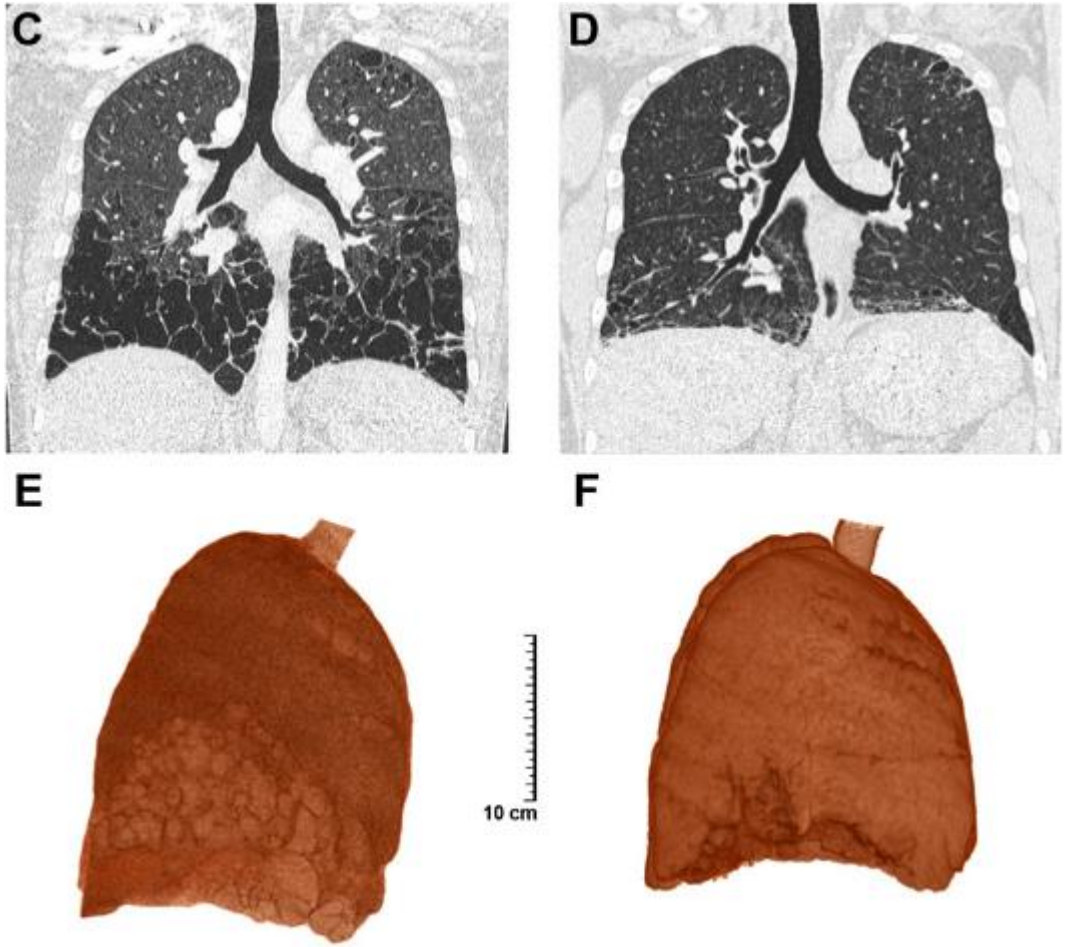

Lorillon et al. AJRCCM 2012

Avant traitement

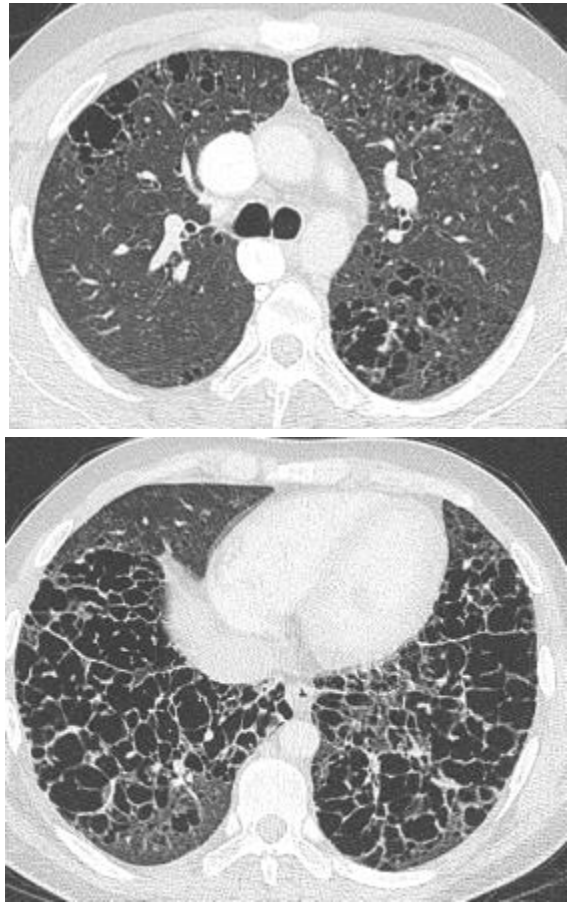

6 mois après traitement

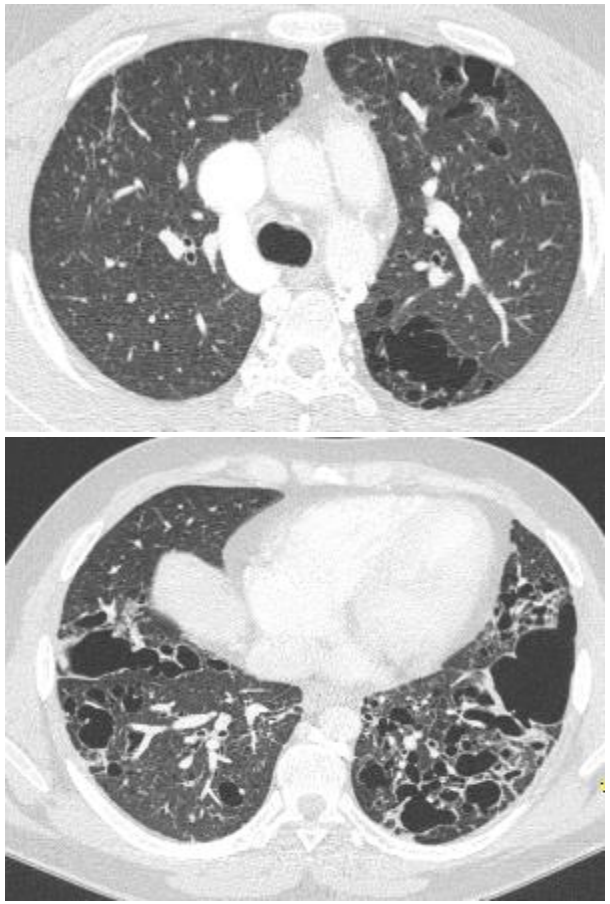

4 ans après traitement

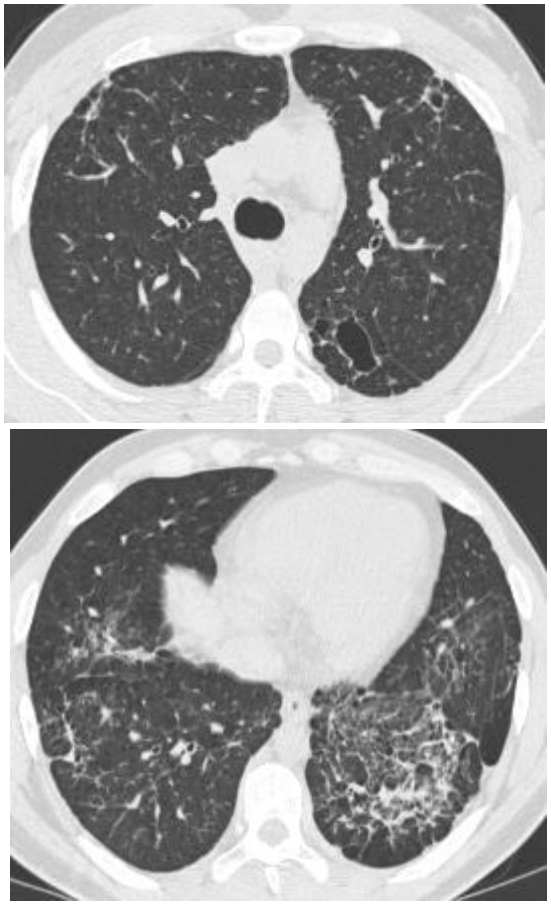

	Patient 1				Patient 2				Patient 3			
PFTs	M0	M6	M12	M48	M0	M6	M21*	M48	M0	M6	M16	M-48
TLC	6360	6800	7130		7240	6810	7260	7820	5000	4170	4980	4940
%	73	78	83		93	88	93	100	80	67	79	78
VC	3830	4320	4700		4610	3920	3850	3380	3060	2660	3030	3450
%	57	65	71		80	69	68	60	63	55	63	72
RV	2520	2470	2430		2630	2890	3530	4440	1930	1510	1950	1520
%	133	130	126		134	146	181	217	128	100	129	97
FEV_1	2520	3090	2940	3000	3790	2700	2470	2180	1840	2300	2550	3030
%	42	53	51		78	56	52	46	46	57	63	78
FEV_1/VC	66	72	63		82	67	64	58	73	86	84	88
DL_{CO} %	22	23	26		24	35	35	35	53	53	45	61

*2 additional courses of cladribine

ECLA Study "NCT01473797"

Recurrent *BRAF* mutations in Langerhans cell histiocytosis *Blood 2010*

Gayane Badalian-Very,[1-3] Jo-Anne Vergilio,[4,5] Barbara A. Degar,[6-8] Laura E. MacConaill,[9] Barbara Brandner,[1-3] Monica L. Calicchio,[4] Frank C. Kuo,[5,10] Azra H. Ligon,[5,10,11] Kristen E. Stevenson,[12] Sarah M. Kehoe,[9] Levi A. Garraway,[1-3,9,13] William C. Hahn,[1-3,9,13] Matthew Meyerson,[1,2,9,13] Mark D. Fleming,[4,5] and Barrett J. Rollins[1-3]

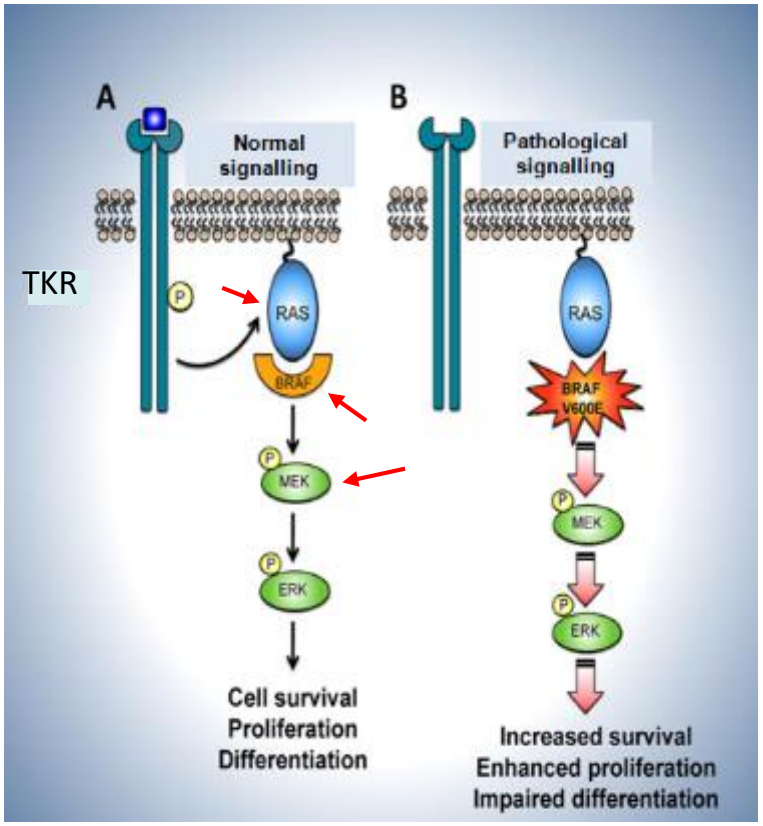

Nichols KE and Arceci RJ Blood 2010

p-MEK

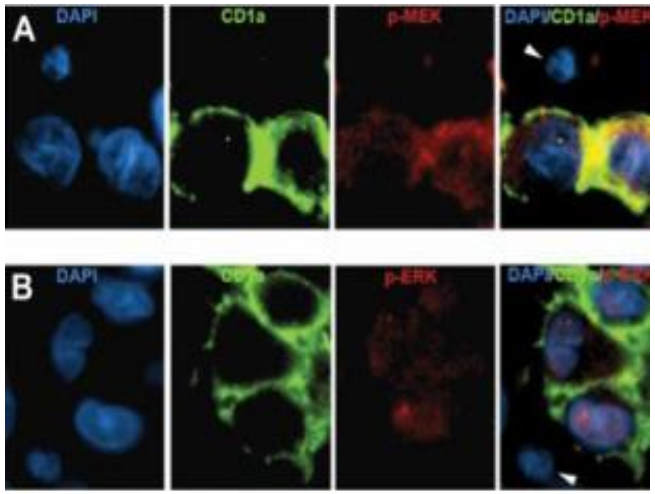

p-ERK

Brown et al. Blood 2014
Chakraborty et al. Blood 2014
Mourah et al. ERJ 2016
Chakraborty et al. Blood 2016
Jouenne et al. ERJ 2020

Mutations MAPK dans l'HL

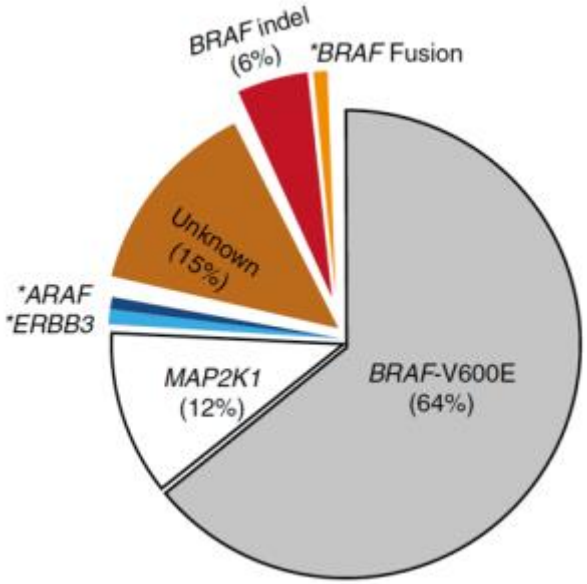

HL pédiatrique

Chakraborty et al. Blood 2016

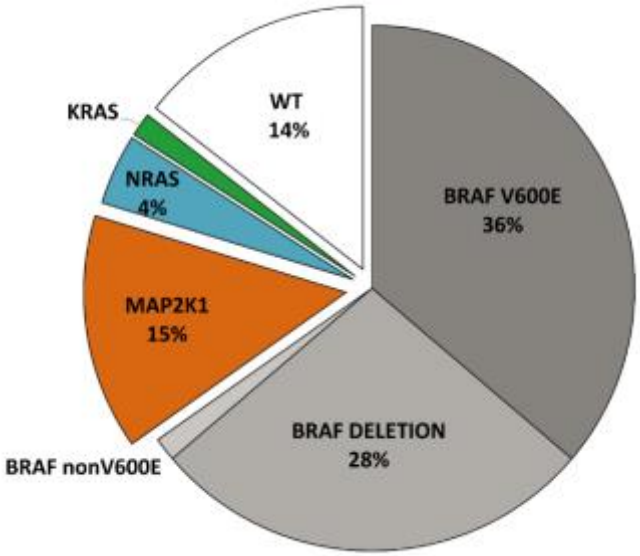

HLP adulte

Jouenne et al. ERJ 2020

Activating mutations in *CSF1R* and additional receptor tyrosine kinases in histiocytic neoplasms

Durham et al. Nature Med 2019

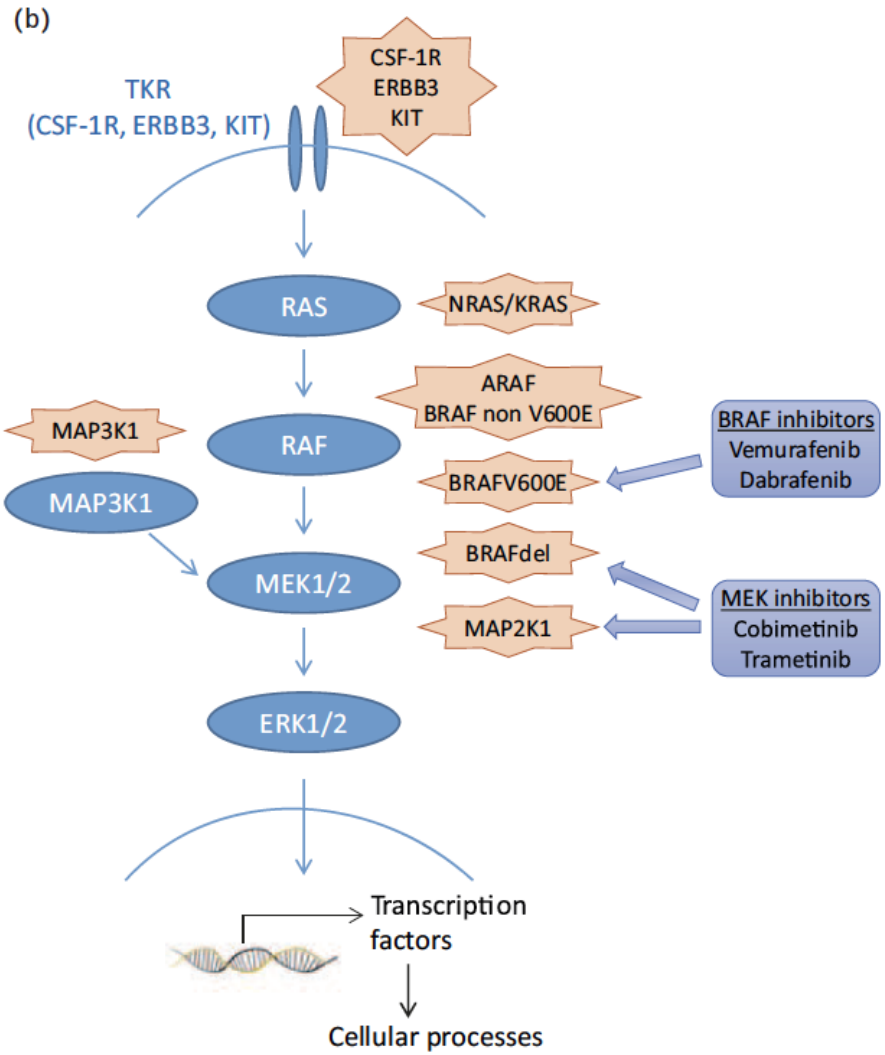

Jouenne et al. Current Opin Oncol 2021

Response to Trametinib of a Pulmonary Langerhans cell Histiocytosis Harboring a MAP2K1 deletion

Lorillon et al. AJRCCM 2018

cladribine

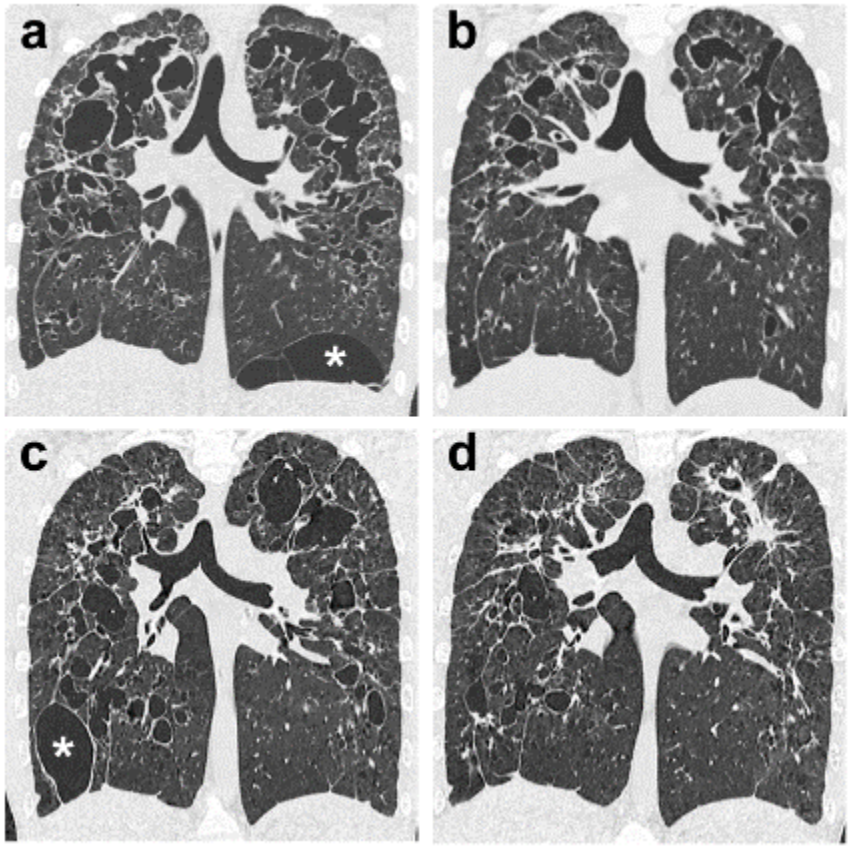

trametinib

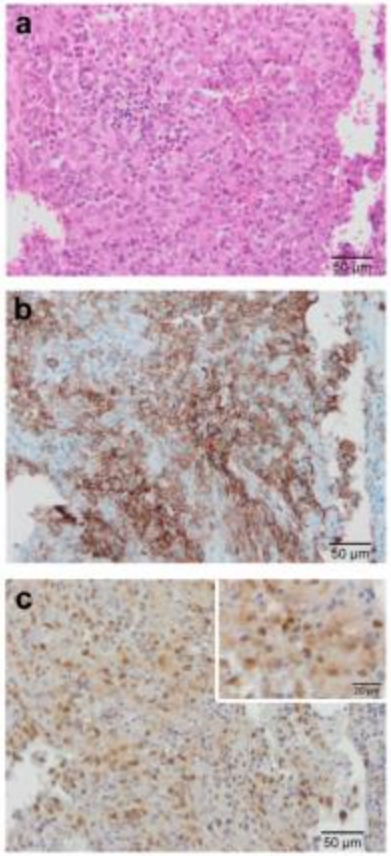

HES

CD1a

p-ERK

Hematopoietic origin of Langerhans cell histiocytosis and Erdheim-Chester disease in adults

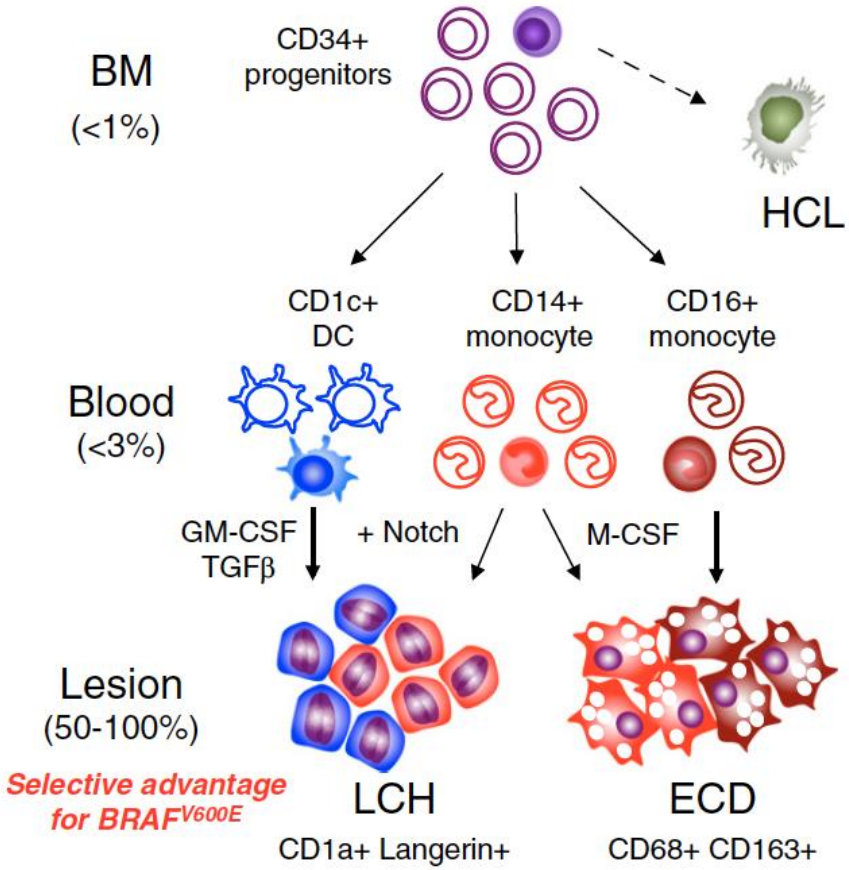

Milne et al. Blood 2017

MAPK mutations and cigarette smoke promote the pathogenesis of pulmonary Langerhans cell histiocytosis

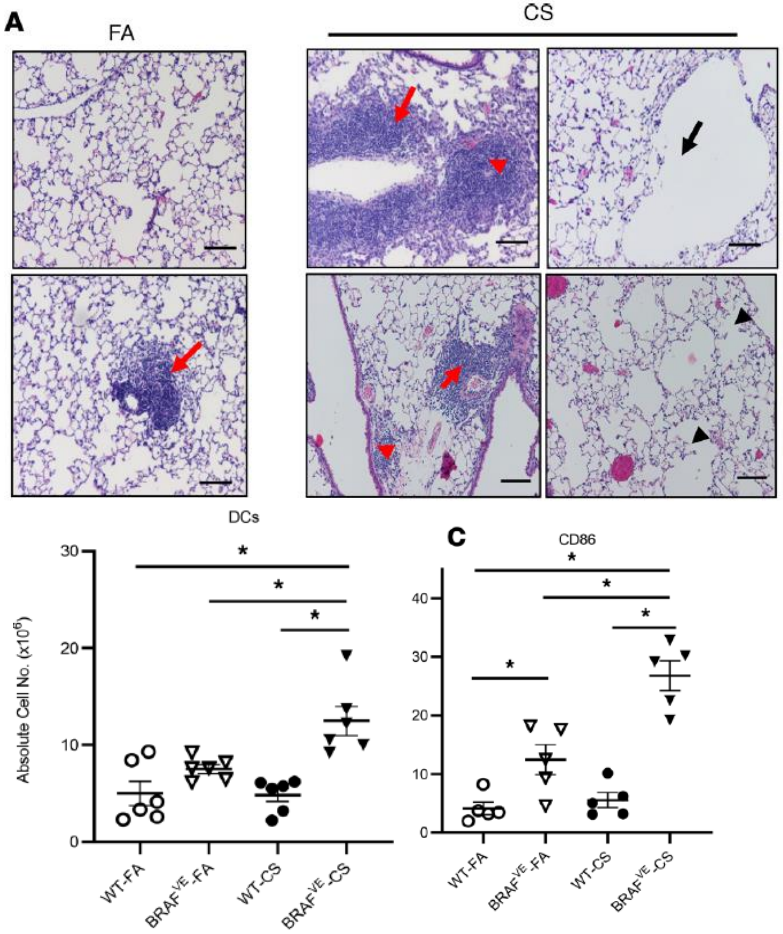

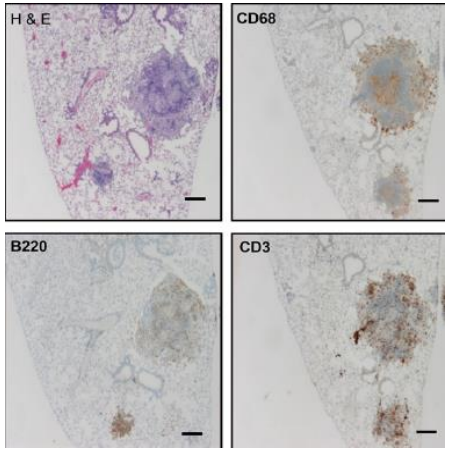

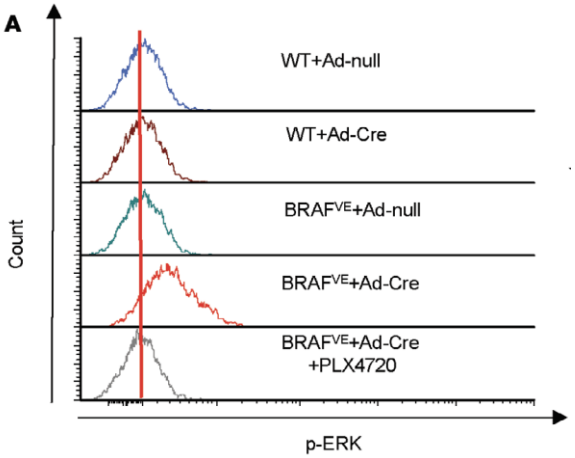

Liu et al. JCI Insight 2020

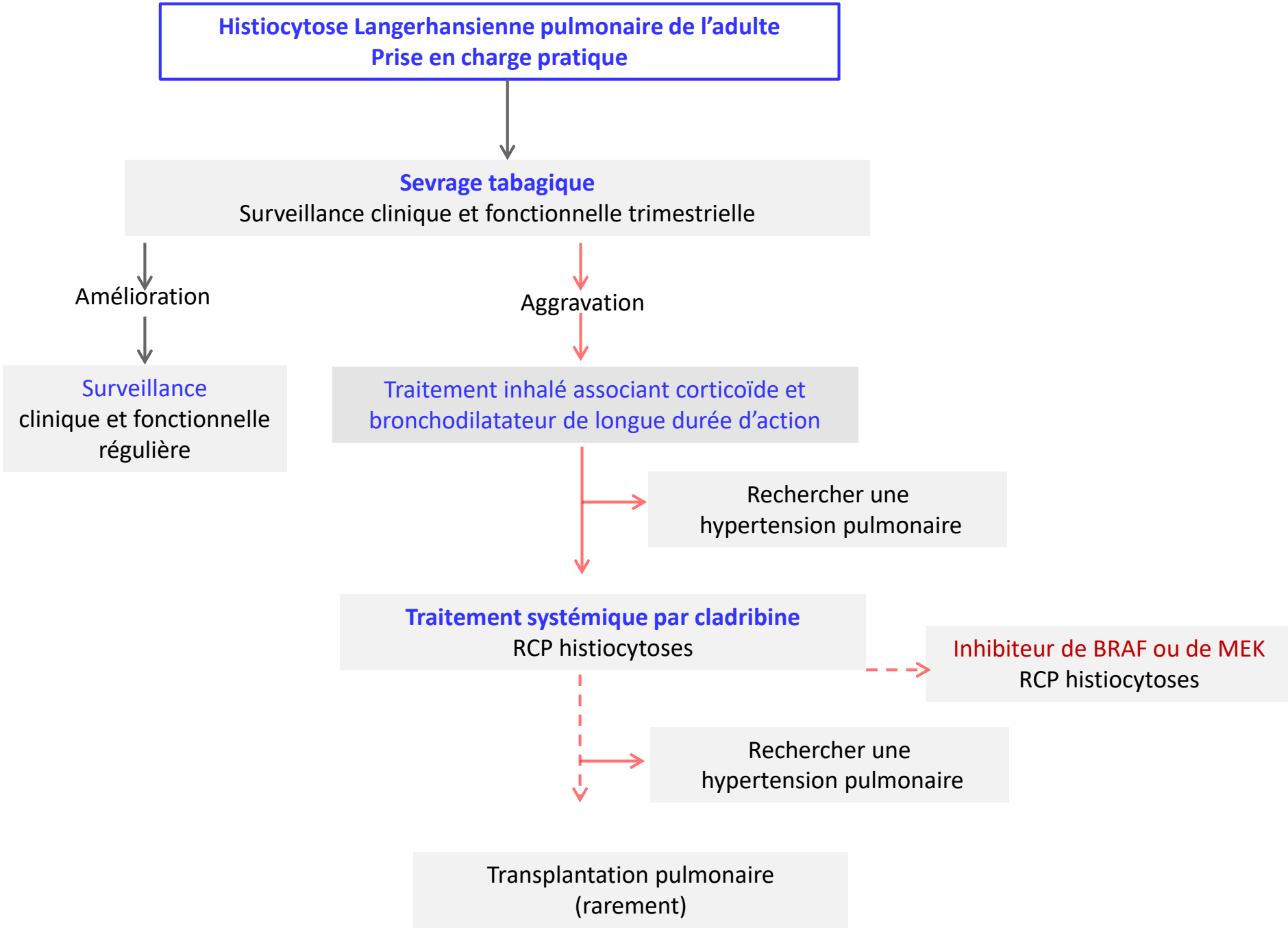
Histiocytose Langerhansienne pulmonaire de l'adulte
Prise en charge pratique
Sevrage tabagique
Surveillance clinique et fonctionnelle trimestrielle
Amélioration
Aggravation
Surveillance
clinique et fonctionnelle
régulière
Traitement inhalé associant corticoïde et
bronchodilatateur de longue durée d'action
Rechercher une
hypertension pulmonaire
Traitement systémique par cladribine
RCP histiocytoses
Inhibiteur de BRAF ou de MEK
RCP histiocytoses
Rechercher une
hypertension pulmonaire
Transplantation pulmonaire
(rarement)

Lung Cysts, Spontaneous Pneumothorax, and Genetic Associations in 89 Families with Birt-Hogg-Dubé Syndrome *Toro et al AJRCCM 2007*

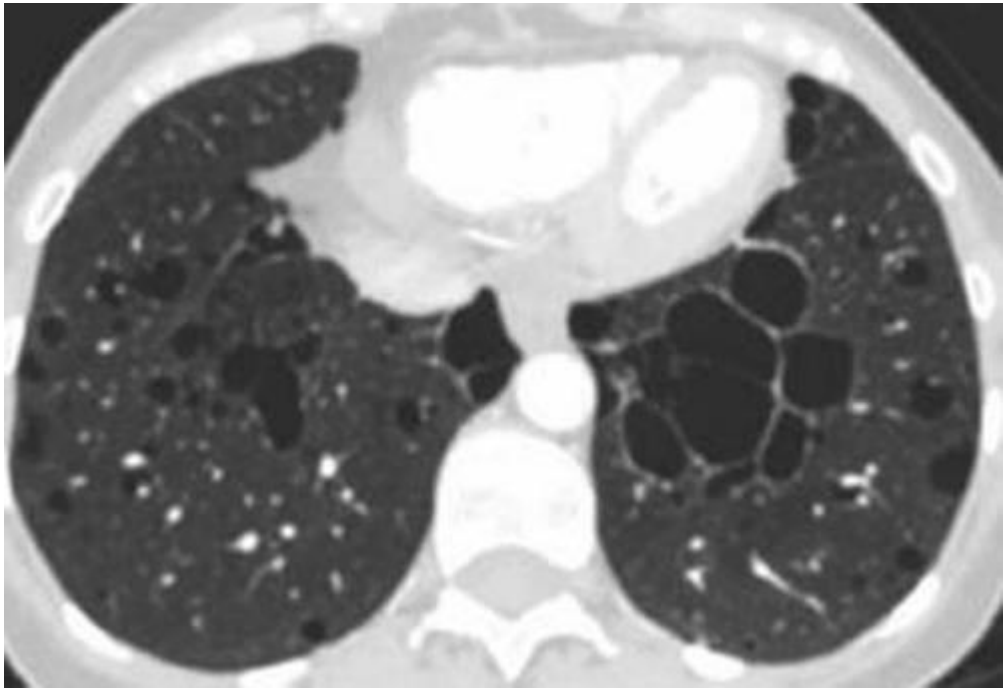

- génodermatose
- autosomique dominante
- lésions cutanées (fibrofolliculomes)
- tumeurs rénales (autres)
- kystes pulmonaires, pneumothorax
- mutation du gène de la folliculine

Enquête familiale++

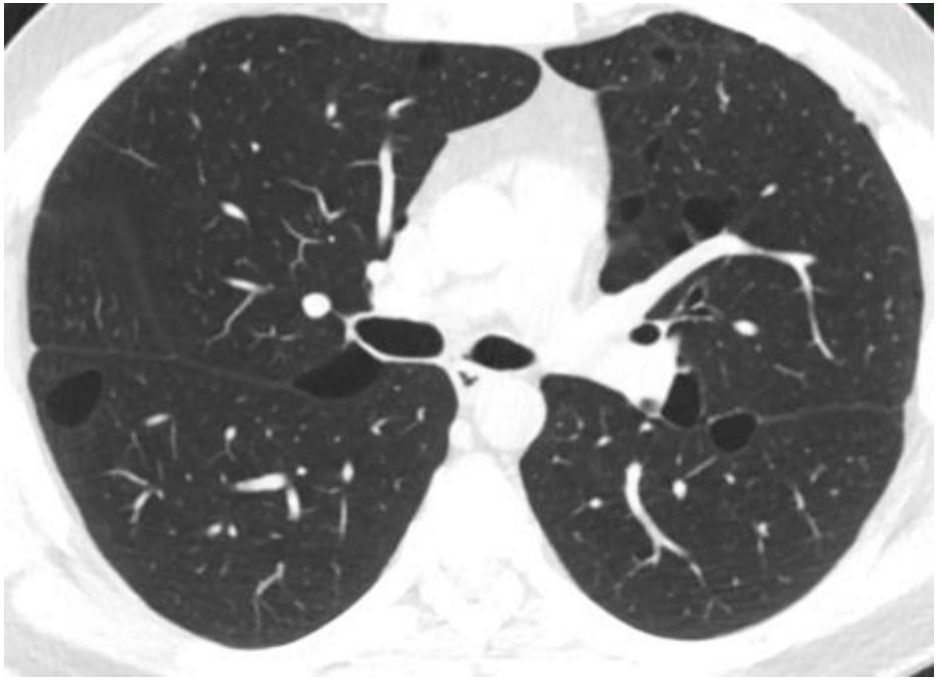

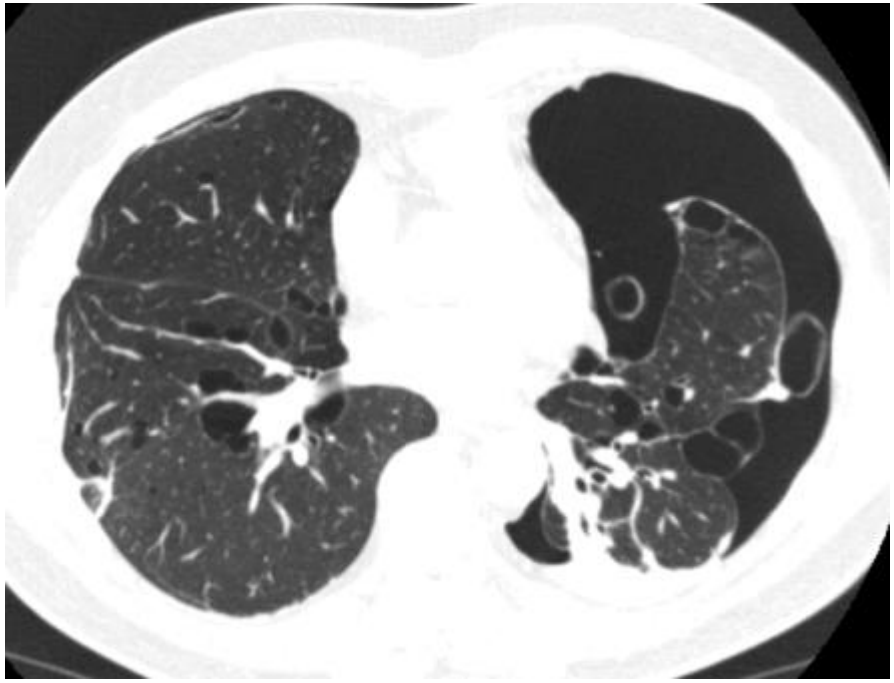

Pulmonary Cystic Disorder Related to Light Chain Deposition Disease

Colombat et al. AJRCCM 2006

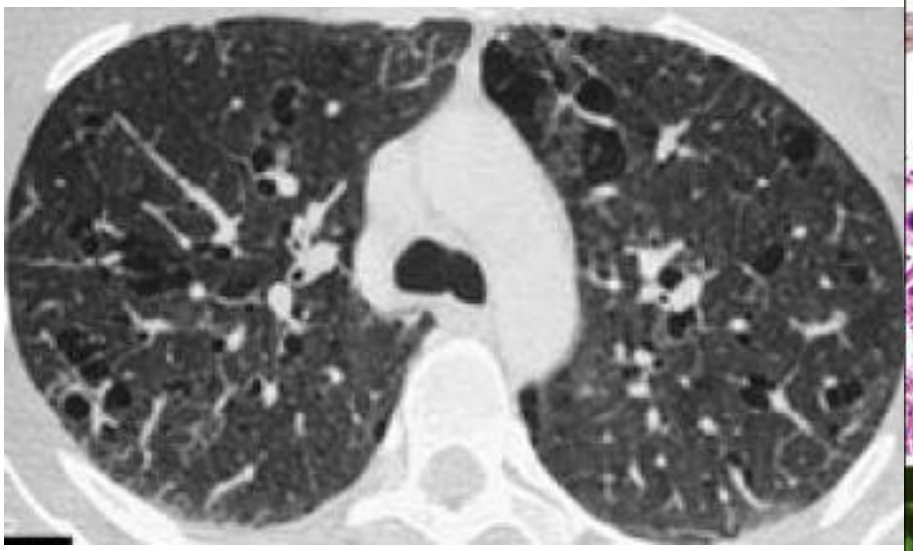

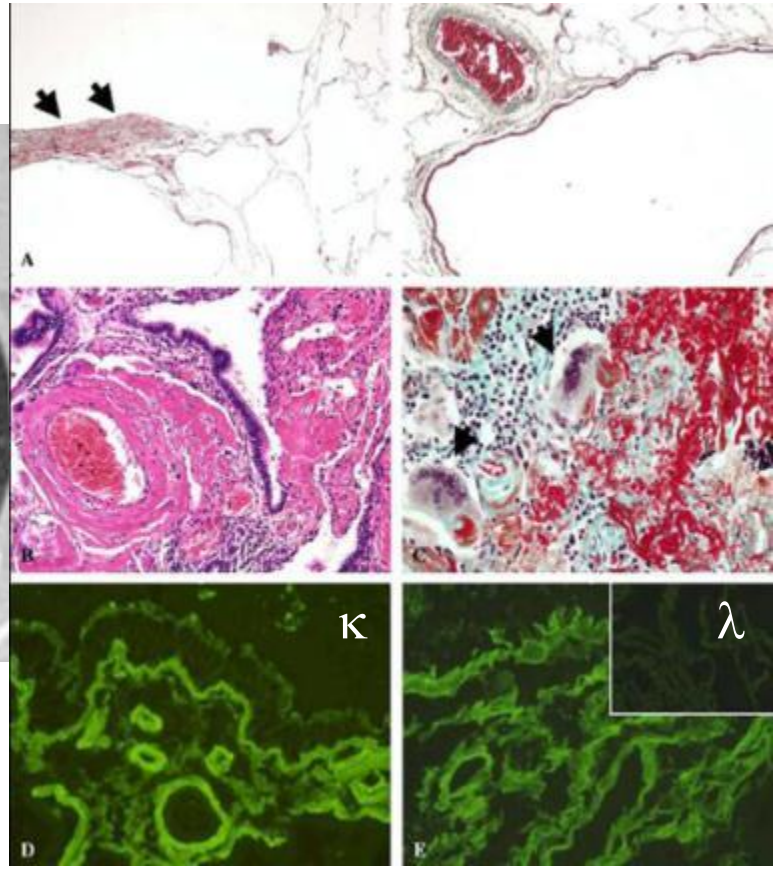

Primary cystic lung light chain deposition disease: a clinicopathologic entity derived from unmutated B cells with a stereotyped IGHV4-34/IGKV1 receptor

Colombat et al. Blood 2008

Sjögren + LIP kystique pure

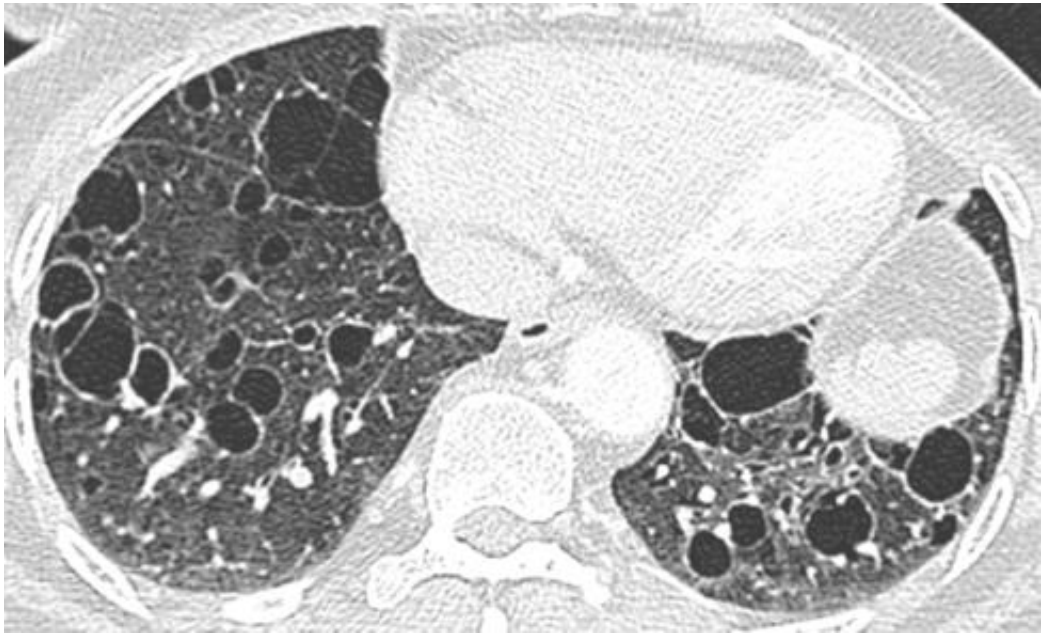

Pathologie Pulmonaire Kystique Diffuse

Approche diagnostique en pratique (1)

- Sexe
- Age
- Tabagisme
- Famille
  - STB
  - BHD
- Signes généraux: attention aux infections (PCJ)
- Signes radiologiques thoraciques associés
  - nodules, cavités (verre dépoli, épaississements septaux…)
  - pleurésie, atteinte costale
- Imagerie antérieure et séquence évolutive
  - nodules → cavités précédant les kystes
  - inverse?

Pathologie Pulmonaire Kystique Diffuse
Approche diagnostique en pratique (2)

- Anomalies extra-thoraciques
  - Rein
    - ✓ LAM++/STB
    - ✓ BHD
  - Lymphangioléiomyomes, ggs abdominaux
    - ✓ LAM/STB
  - Peau
    - ✓ STB
    - ✓ HL
    - ✓ BHD
    - ✓ Rarement sarcome, NF…
  - Os
    - ✓ HL++
    - ✓ (tumeurs malignes)
  - Hypophyse
    - ✓ Diabète insipide: HL

TDM/IRM abdomen pelvis

- Pathologie associée connue++

Pathologie Pulmonaire Kystique Diffuse
Approche diagnostique en pratique (3)

- Biologie
  - Lymphocytes sanguins
  - EPP; immunofixation; (dosage chaînes légères)
  - VEGF-D
  - (α1 AT)

- Fibroscopie bronchique
  - Biopsie de lésion
  - B. transbronchiques (risque PNO)
  - Si LBA
    - ✓ alvéolite macrophagique (tabac) ou non

- Génétique
  - Folliculine
  - (Mutations TCS2/TCS1)

Pathologie Pulmonaire Kystique Diffuse
Biopsie pulmonaire chirurgicale

- Absence d'argument indirect pour diagnostic
- Risque, degré d'altération de la fonction respiratoire
- Conséquences sur la prise en charge
- Quand réalisée:
  - Etude exhaustive du prélèvement
  - Coloration spéciales
    - Rouge congo si dépôts
    - (PAS-Grocott)
  - Immunohistochimie
    - HMB-45 (actine, cathepsine K, ER, ..)
    - CD1a, CD207,mutations MAPK
    - Chaînes légères κ/λ
  - Fragment dans glutaraldéhyde (µe)
  - Congélation++

Pour en savoir plus

- *Kusmirek & Meyer. High-Resolution Computed Tomography of Cystic Lung Disease. Seminars Respir Crit Medicine 2022*
- *De Margerie-Mellon C & Tazi A. Pneumopathies kystiques : approche diagnostique en tomodensitométrie. Journal d'imagerie diagnostique et interventionnelle 2021*
- *Raoof et al. Cystic lung diseases. Algorithmic approach. Chest 2016*
- *Gupta et al. Diffuse cystic lung disease Part 1 & 2. AJRCCM 2015*
- *McCormack et al. Lymphangioleiomyomatosis: pathogenesis, clinical features, diagnosis and management. Lancet Respir Med 2021*
- *Benattia et al. Long-term Outcomes of Adult Pulmonary Langerhans Cell Histiocytosis: A Prospective Cohort. Eur Respir J 2022*
- *Vassallo R, Harari S, Tazi A. Current understanding and management of pulmonary Langerhans cell histiocytosis. Thorax 2017*