EMBOLIE PULMONAIRE ET HYPERTENSION PULMONAIRE POSTEMBOLIQUE

GUILLAUME CHASSAGNON

Imagerie cardio-thoracique - Hôpital Cochin

Thèmes abordes

1. Quand prescrire un angioscanner thoracique
2. Quelles précautions/ contre indications
3. Sémiologie de l’embolie aigue
4. Thrombo embolie chronique et CPCPE
5. Pièges

Université de Paris

Quand prescrire un angioscanner ?

- Après avoir **examiné** le patient, évalué sa **probabilité clinique**, dosé les **D-dimères** (hors probabilité clinique forte) et avoir **exclu les contre-indications**
- Radiographie du thorax: intérêt pour les diagnostics alternatifs
- **Si patient orthopnéique: reconsidérer**

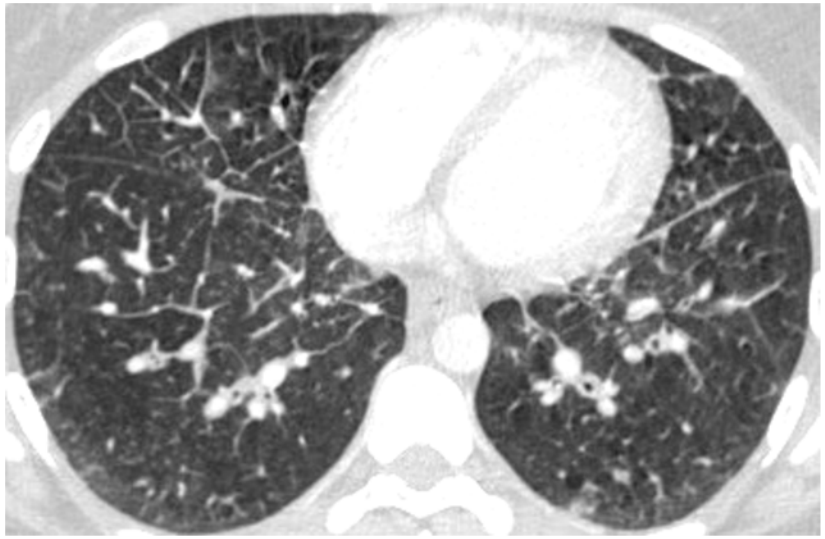

Université de Paris

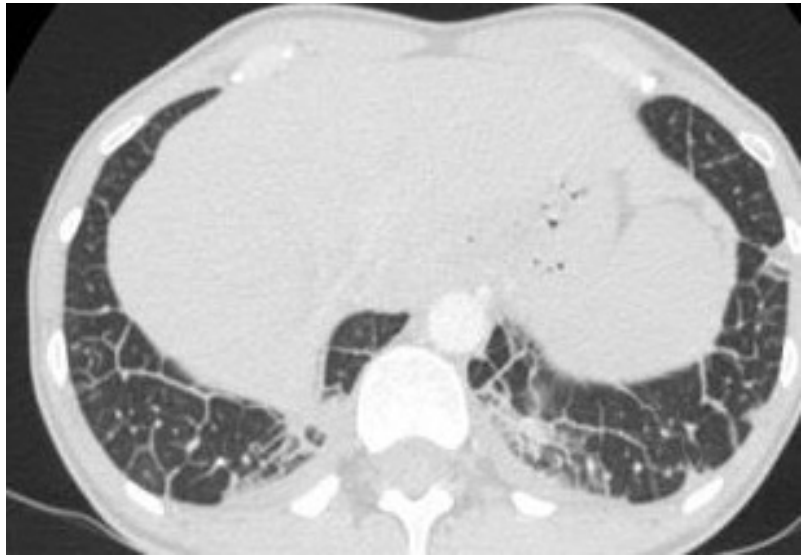

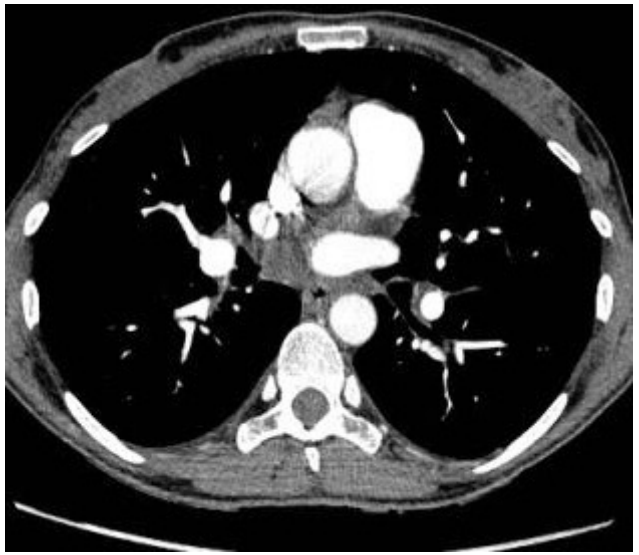

Université de Paris

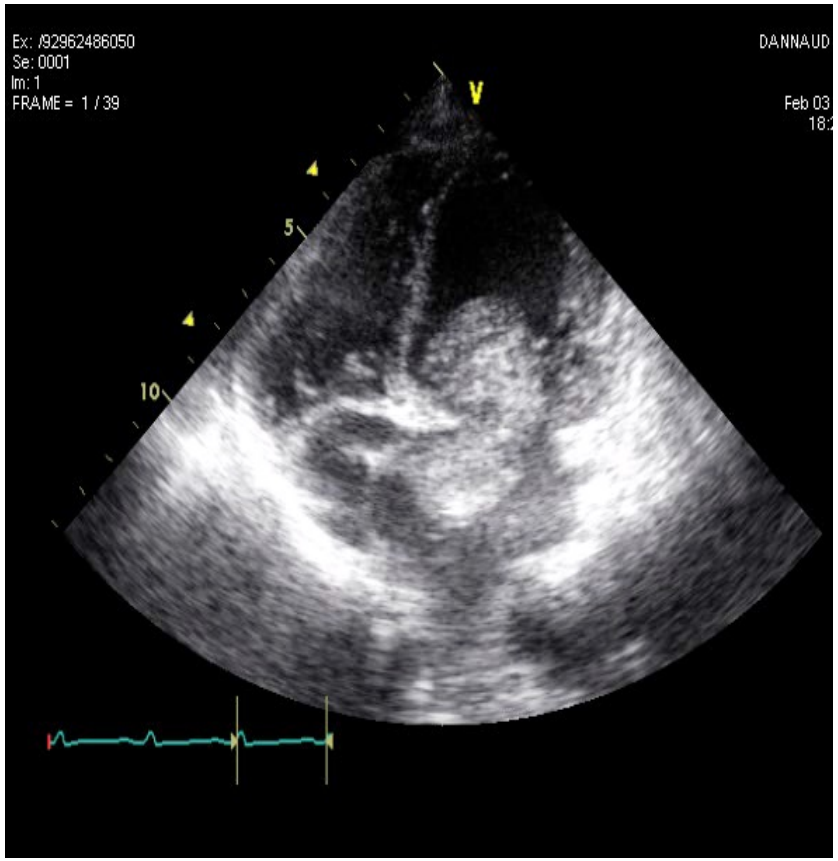

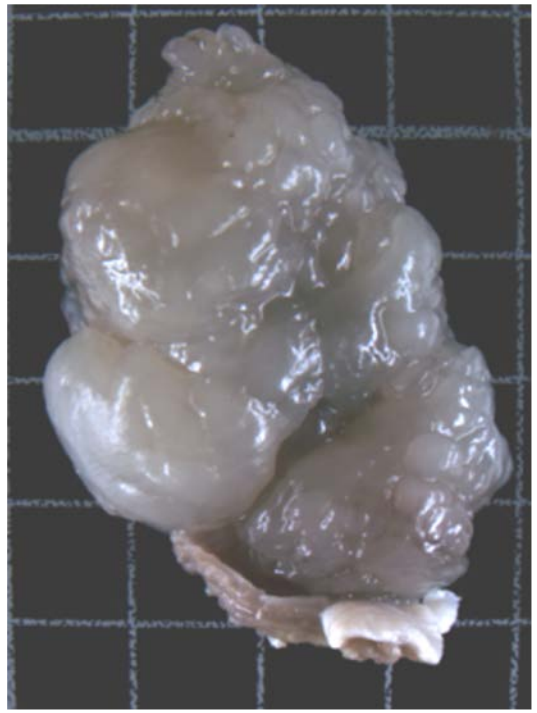

Université de Paris

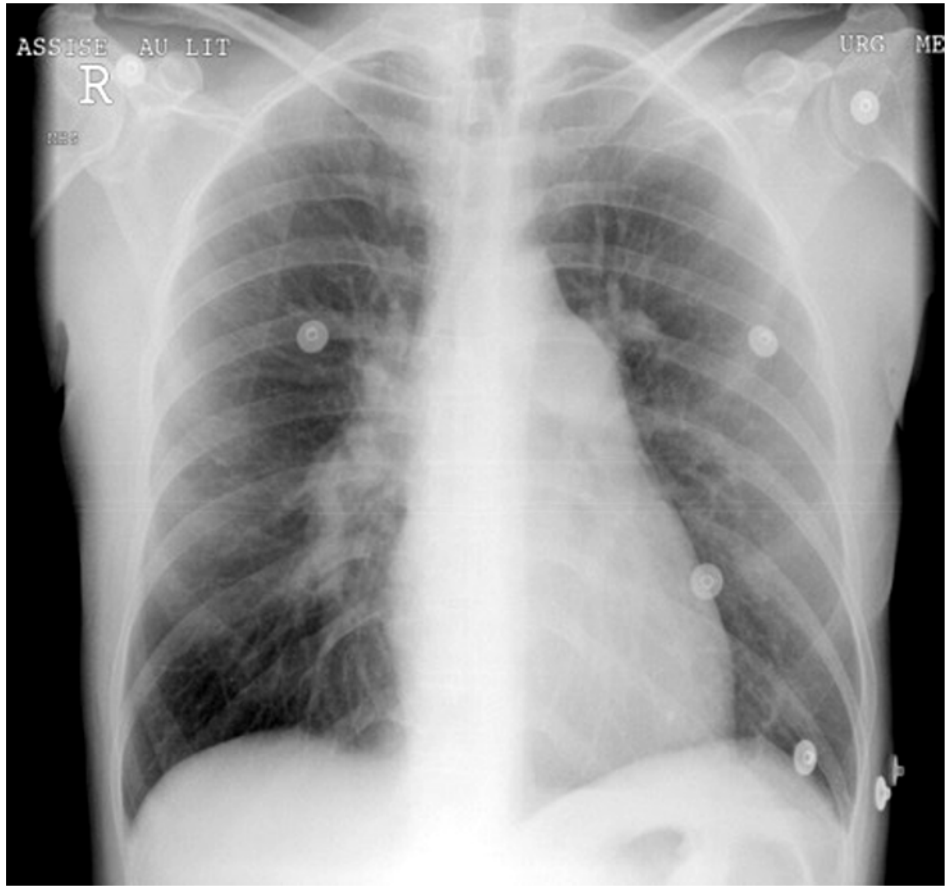

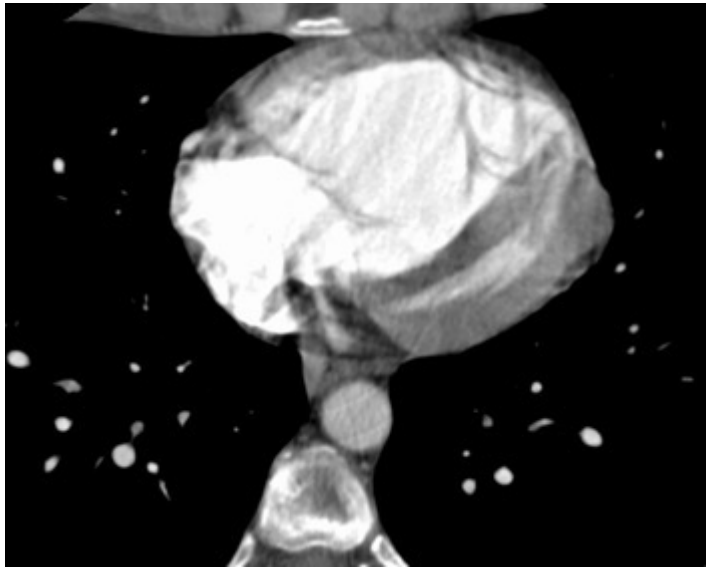

Université de Paris

Quelles précautions / contre indications

- **Allergie aux produits de contraste iodé authentique**
  - À différencier de la mauvaise tolérance
- **Insuffisance rénale**
  - Contre indication relative
- **Hyperthyroidie non contrôlée**

- **Chez la femme enceinte: l'angioscanner n'est pas contre indiqué**
  - Irradiation fœtale ≤ scinti (Winer-Muram- Radiology 2002)
  - Pas de dysthyroidie néonatale (Bourjeily- Radiology 2010)

Université de Paris

Radiology

American Thoracic Society Documents: An Official American Thoracic Society/Society of Thoracic Radiology Clinical Practice Guideline—Evaluation of Suspected Pulmonary Embolism in Pregnancy[1]

Ann N. Leung
Todd M. Bull
Roman Jaeschke
Charles J. Lockwood
Phillip M. Boiselle
Lynne M. Hurwitz

Background: Pulmonary embolism (PE) is a leading cause of maternal mortality in the developed world. Along with appropriate prophylaxis and therapy, prevention of death from PE in pregnancy requires a high index of clinical suspicion followed by a timely and accurate diagnostic approach.

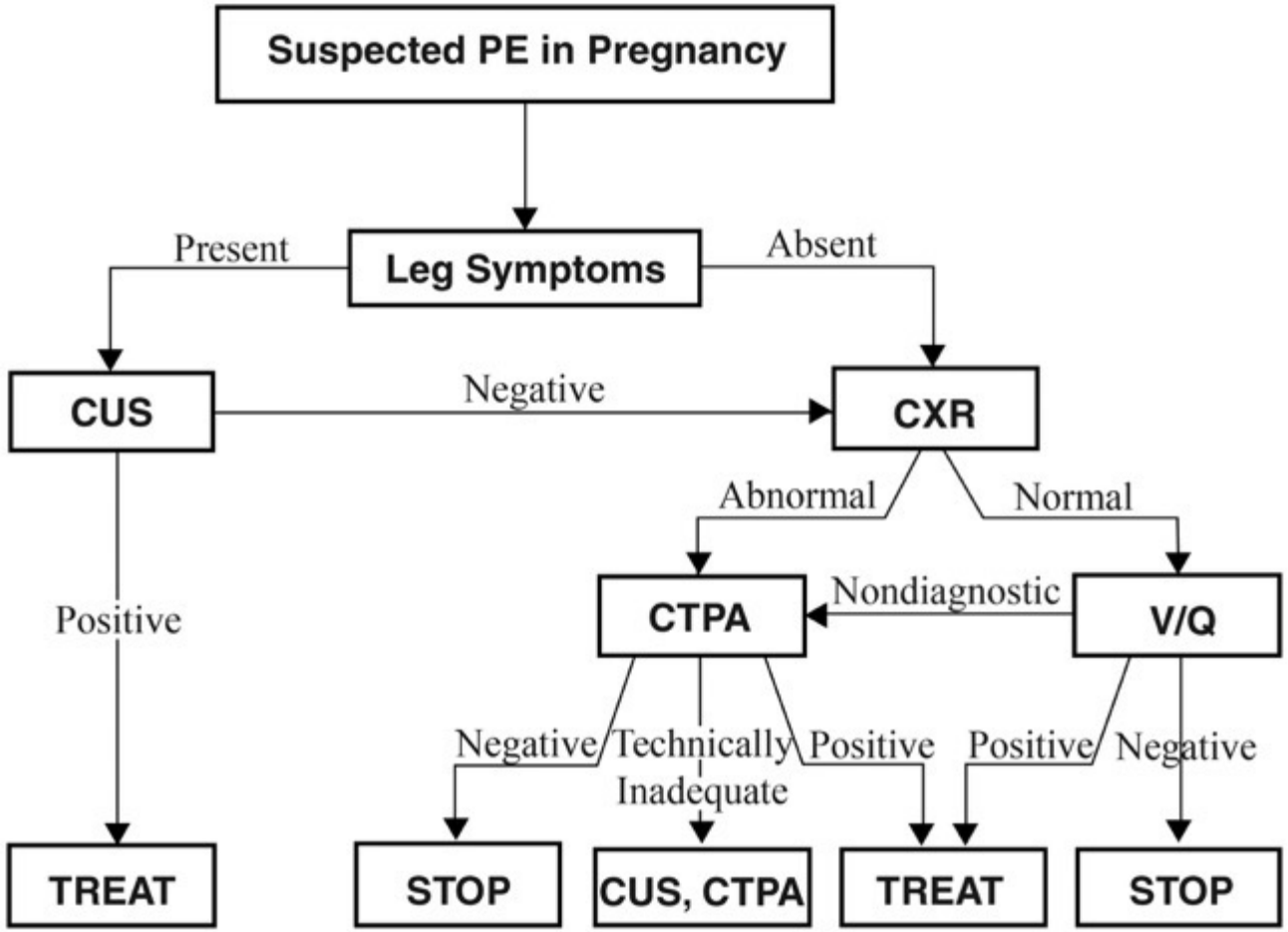

Université de Paris

Sémiologie de l’embolie aigue

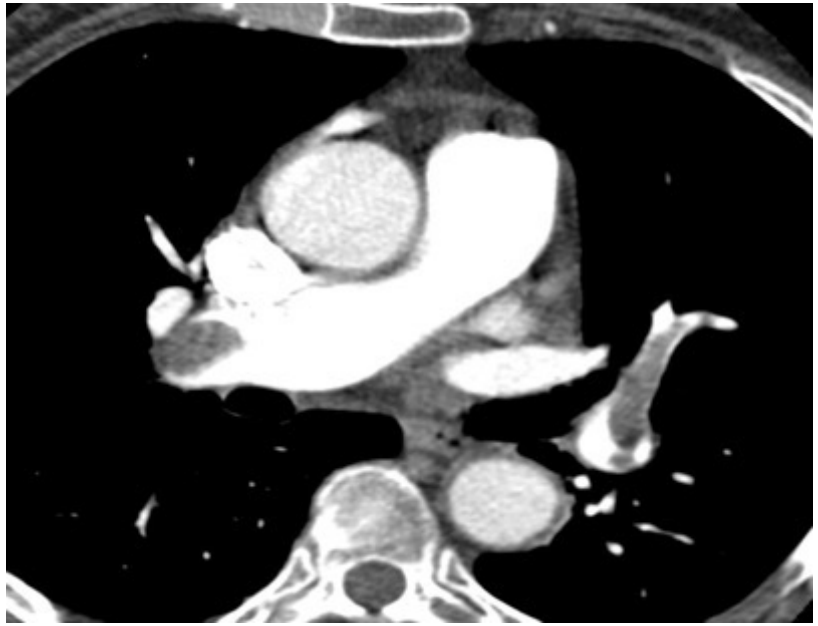

Lobaire

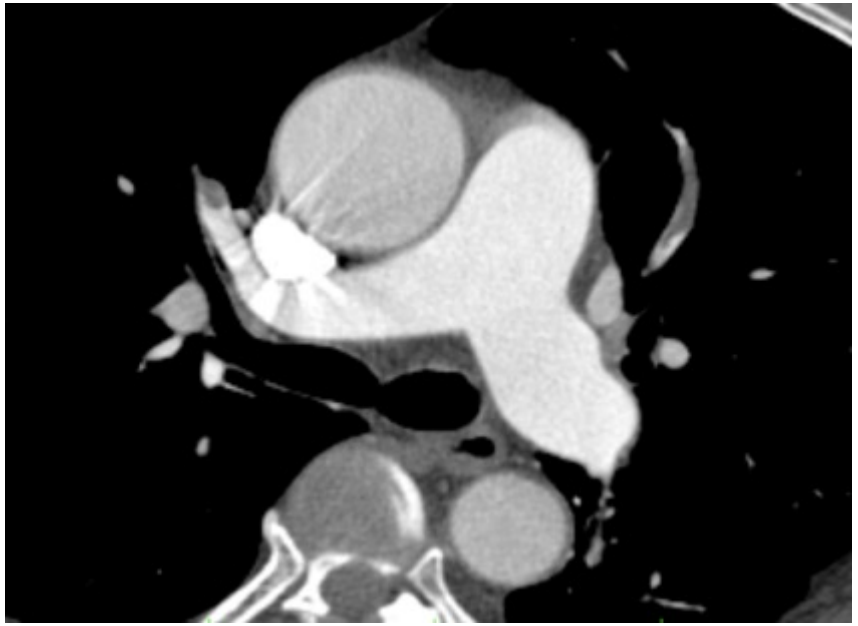

Segmentaire

Sous segmentaire

Université de Paris

Opacification sous optimale: risque de faux négatif

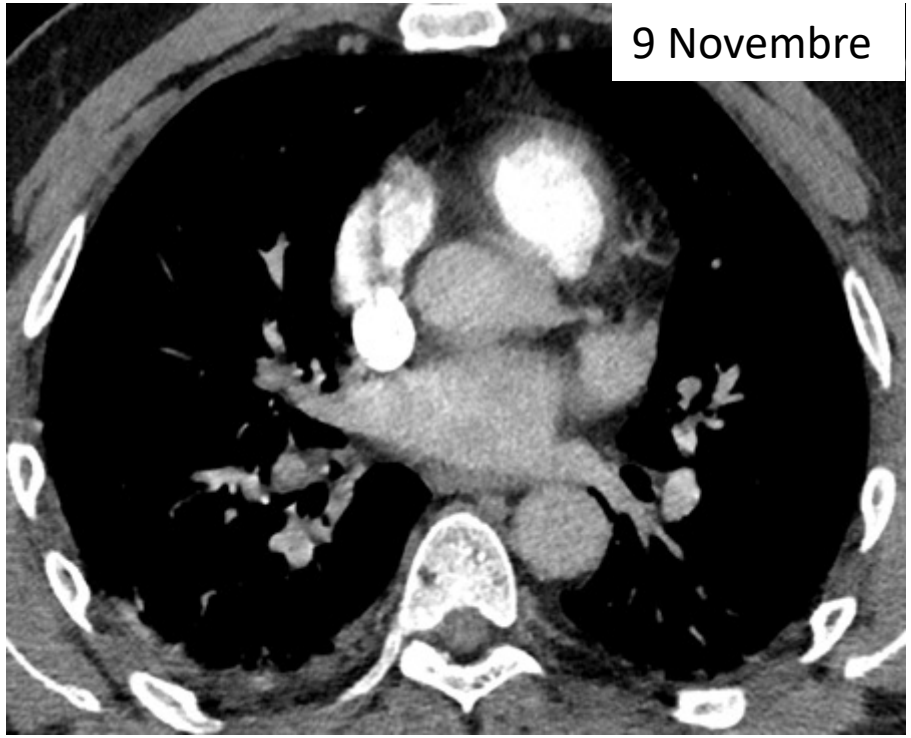

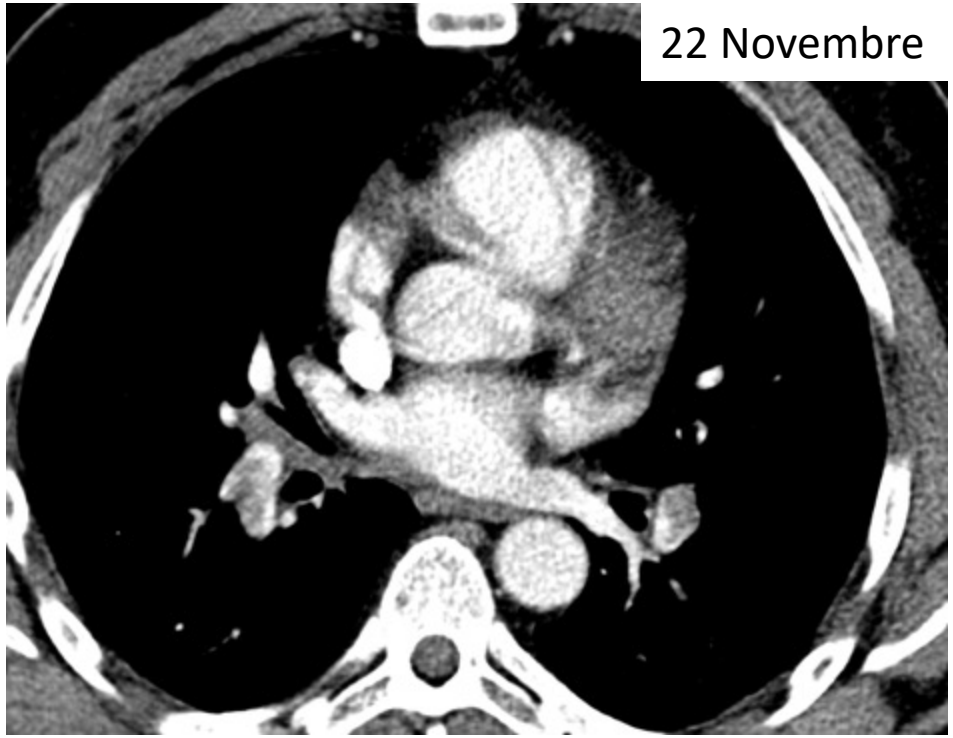

Université de Paris

Opacification sous optimale: risque de faux positif

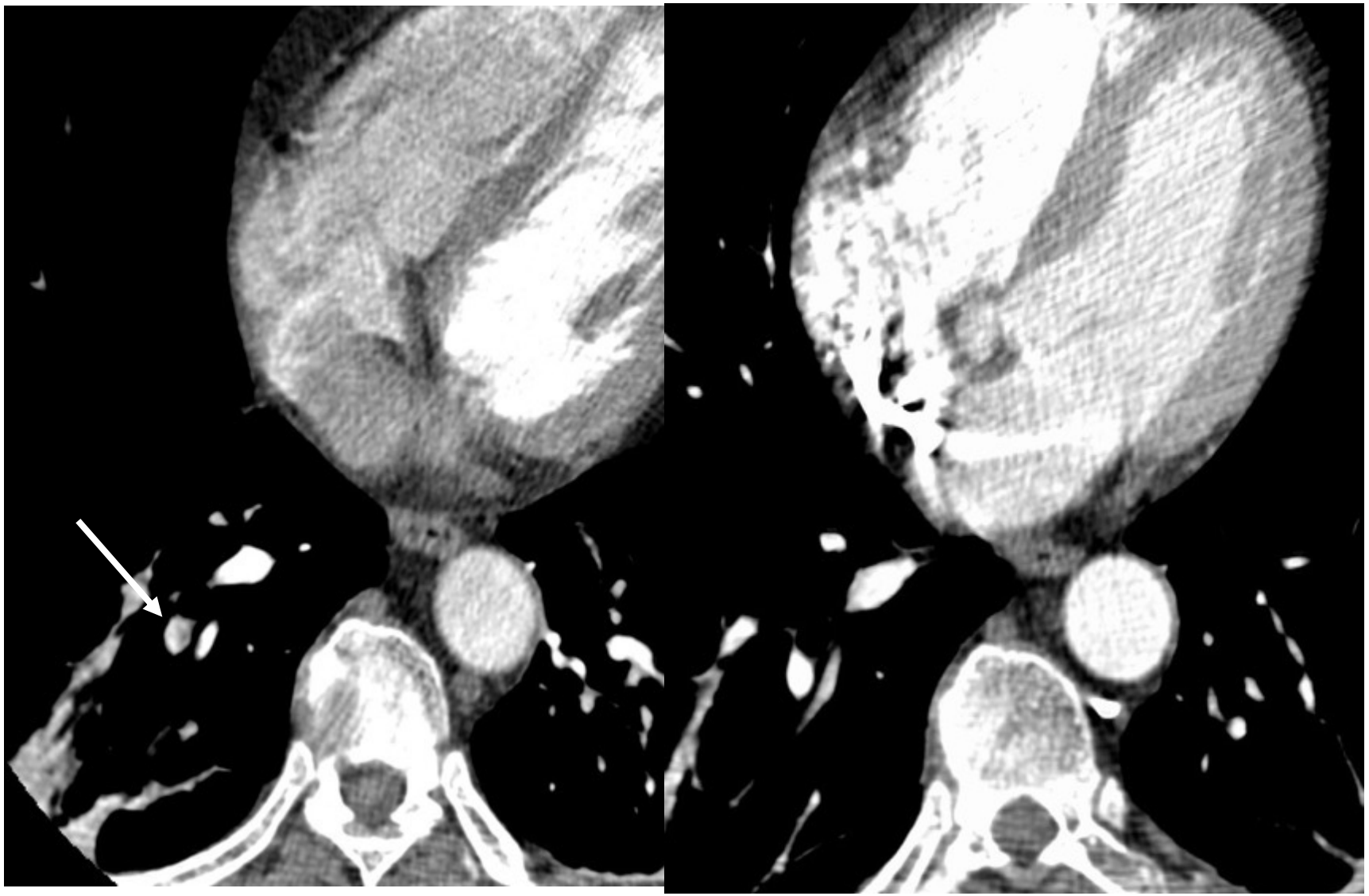

Université de Paris

Opacification insuffisante en distalité : risque de faux négatif

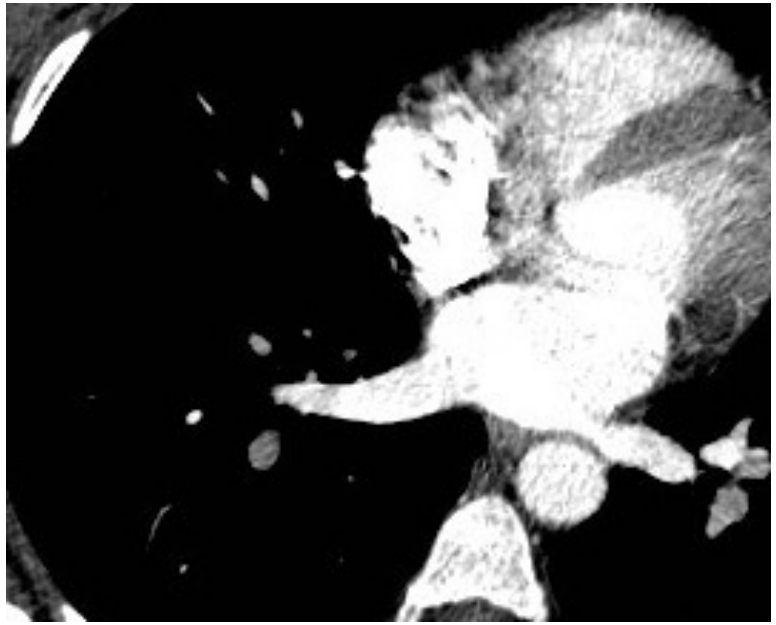

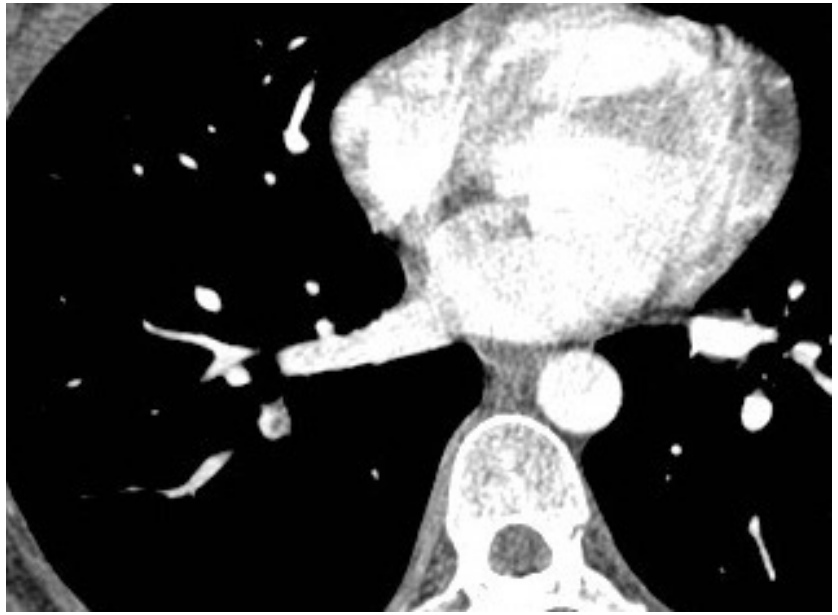

Université de Paris

SI OCCLUSION TRES DISTALE: IMAGE D'INFARCTUS ISOLEE
= Condensation périphérique sous pleurale, triangulaire, à base d'implantation pleurale, sans bronchogramme aérique

Revel, Radiology Septembre 2007 : clartés aériques centrales Odd ratio 23

Université de Paris

Savoir reconnaitre ces images :

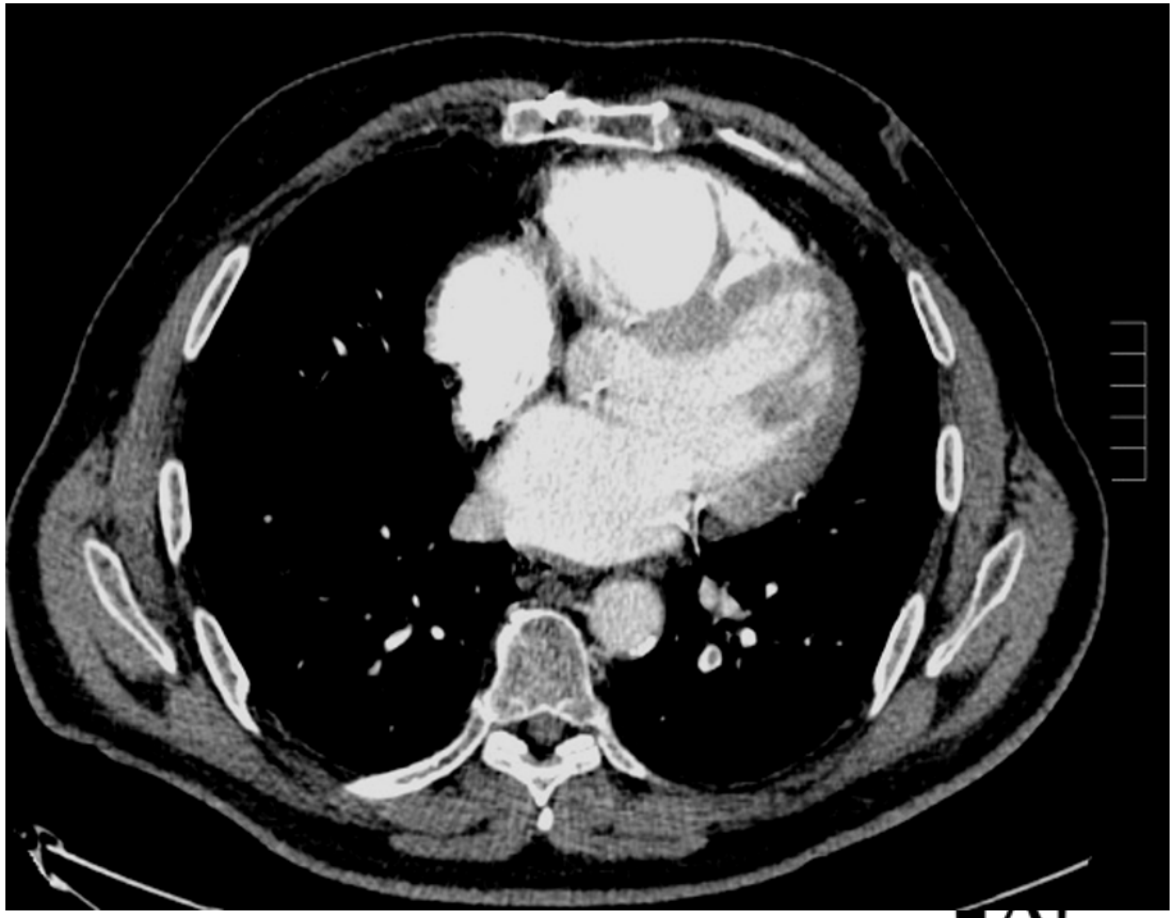

Université de Paris

Point clé infarctus

- **Injecter si image d'infarctus sur un examen sans injection**
- **Si infarctus isolé**, évaluation veineuse exhaustive: **phlébo scanner /doppler veineux membre sup**

OPACIFICATIONS SOUS OPTIMALES: effet délétère de l'apnée inspiratoire ou Valsalva

INSPIRATION

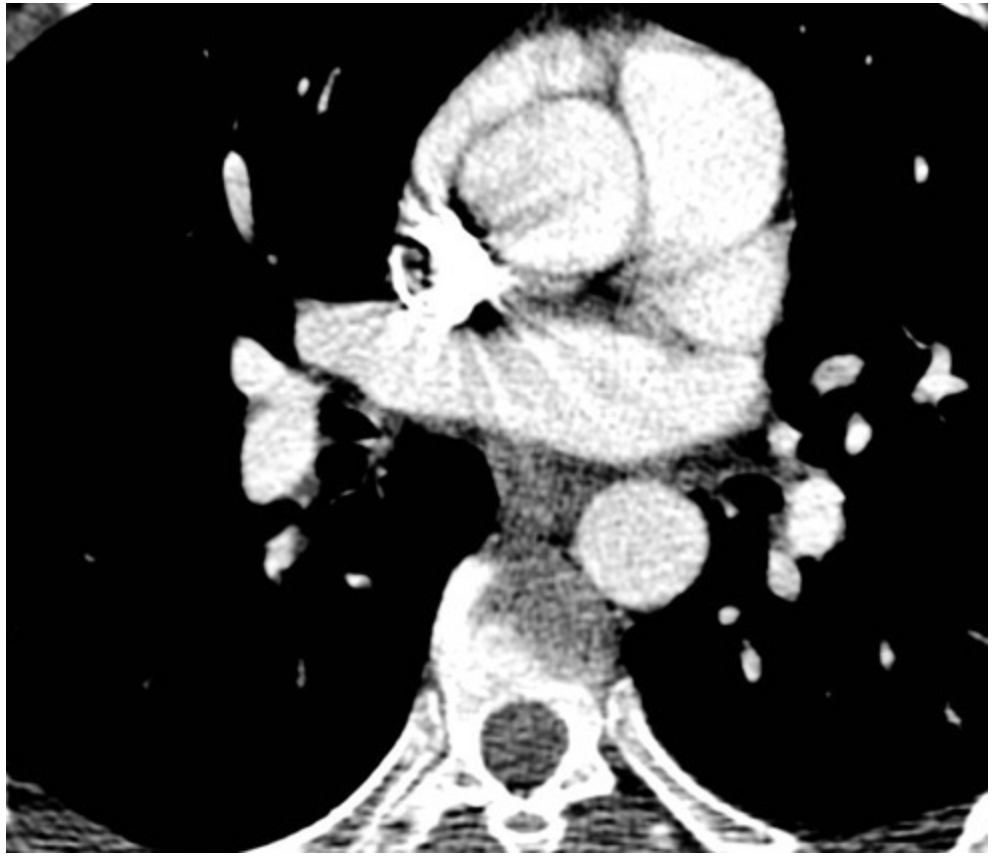

APNEE SIMPLE

Université de Paris

@inspiration: Interruption transitoire du flux sanguin dans la veine cave supérieure, retour veineux cave inférieur prédominant

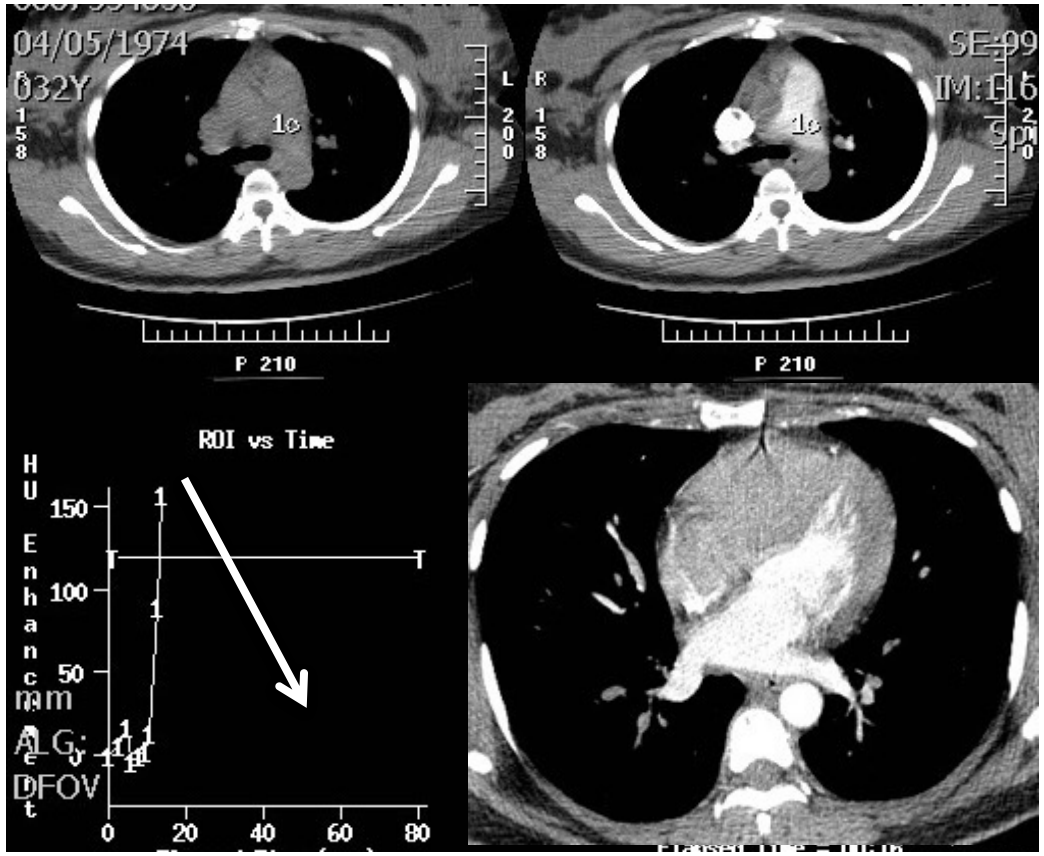

Inspiration

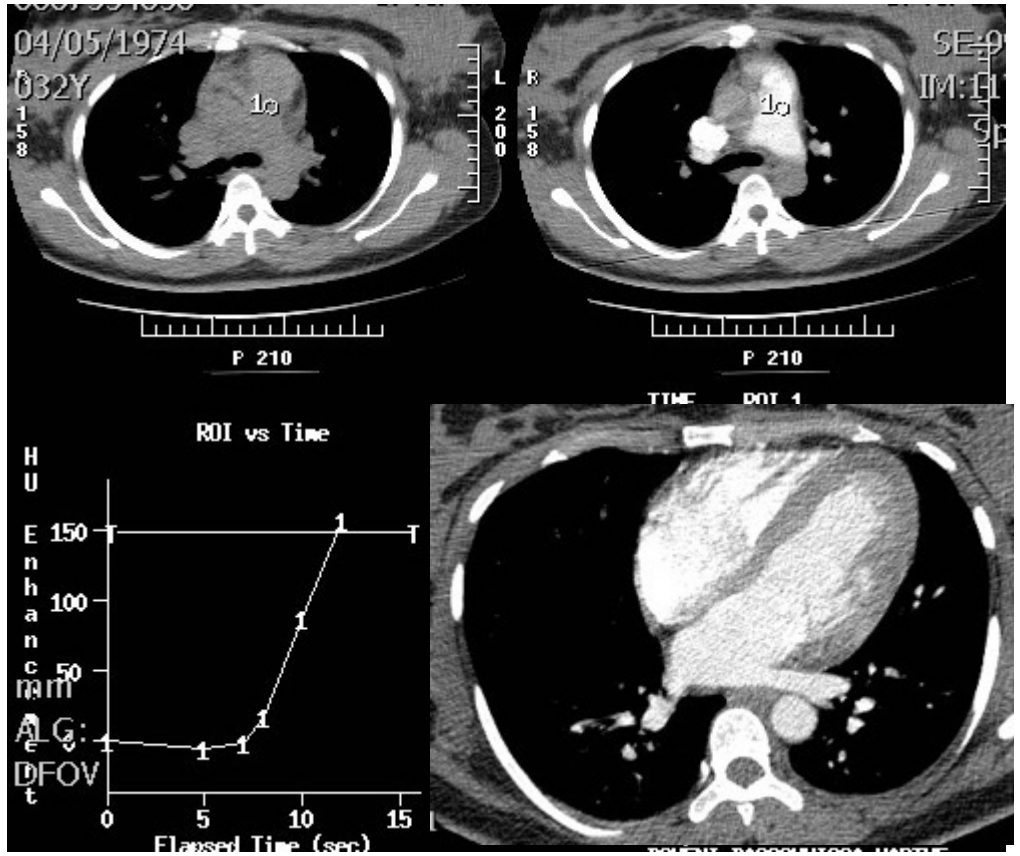

Apnée simple

Université de Paris

Effet inspiration particulièrement délétère en fin de grossesse/post partum

Augmentation du volume sanguin sous diaphragmatique

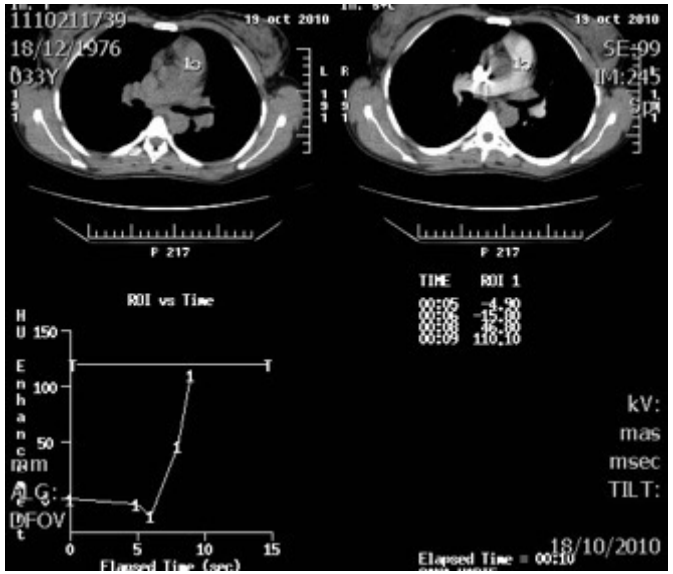

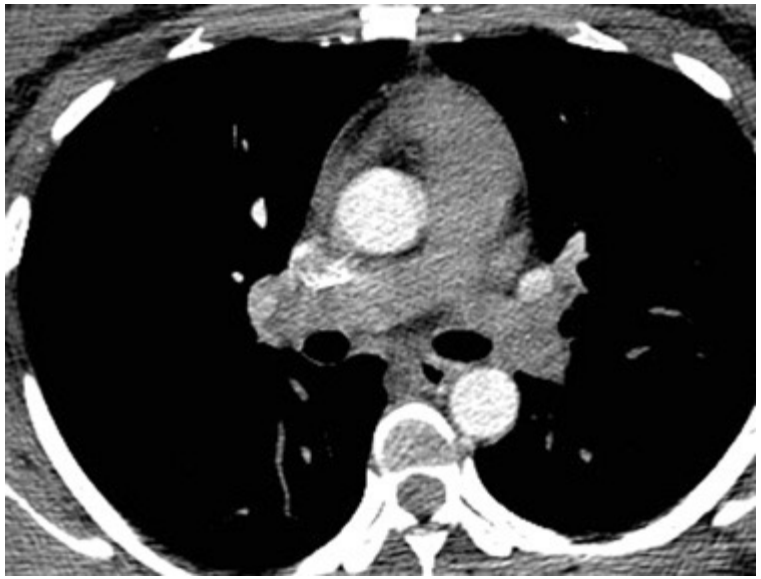

Université de Paris

Intérêt du phléboscanner en post partum

Journal of Thrombosis and Haemostasis, **6**: 1478–1481 DOI: 10.1111/j.1538-7836.2008.03078.x

ORIGINAL ARTICLE

Contribution of indirect computed tomographic venography to the diagnosis of postpartum venous thromboembolism

M. P. REVEL,* O. SANCHEZ,† S. DECHOUX,* S. COUCHON,* G. FRIJA,* J. CAZEJUST,* G. CHATELLIER‡ and G. MEYER†

*Radiology Department, Hopital Europeen Georges Pompidou, APHP, Faculte de Medicine, Universite Paris Descartes, Paris; †Division of Respiratory and Intensive Care Medicine, Hopital Europeen Georges Pompidou, APHP, Faculte de Medicine, Universite Paris Descartes, Paris; and ‡Clinical Research Department, Hopital Europeen Georges Pompidou, APHP, Faculte de Medicine, Universite Paris Descartes, Paris, France

Université de Paris

Thromboembolie chronique, CPCPE

Caillot marginés

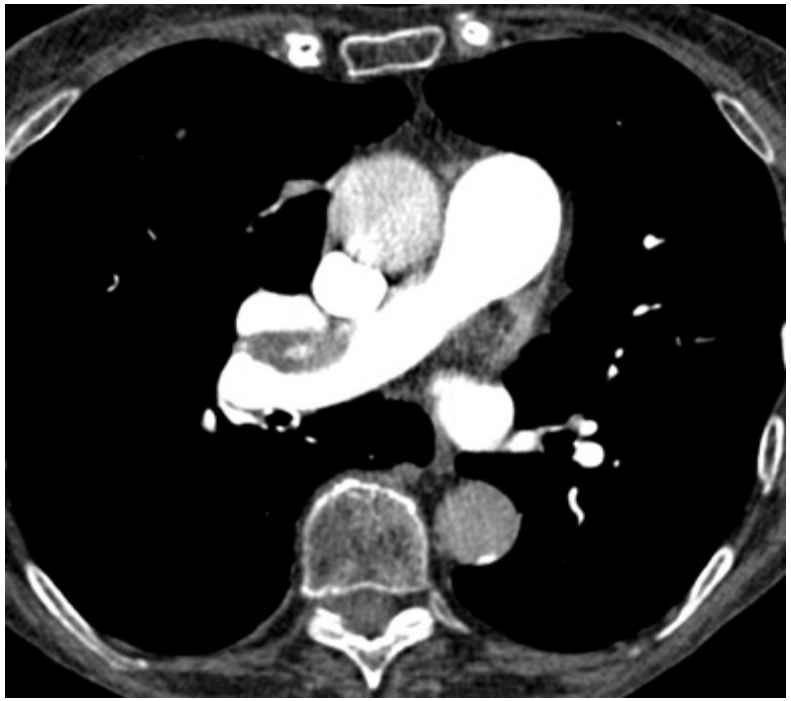

Université de Paris

- **Triade artérielle**
  - **HTAP:** tronc pulmonaire > 30 mm
  - **Hypervascularisation systémique**
    - Bronchique et non bronchique
  - **Images d'embolie chronique:**
    - Webs ou bands
    - Thrombi marginés
    - Rétraction/sténoses

- **Signes parenchymateux**
  - **Perfusion mosaique**
  - **Pseudo DDB**

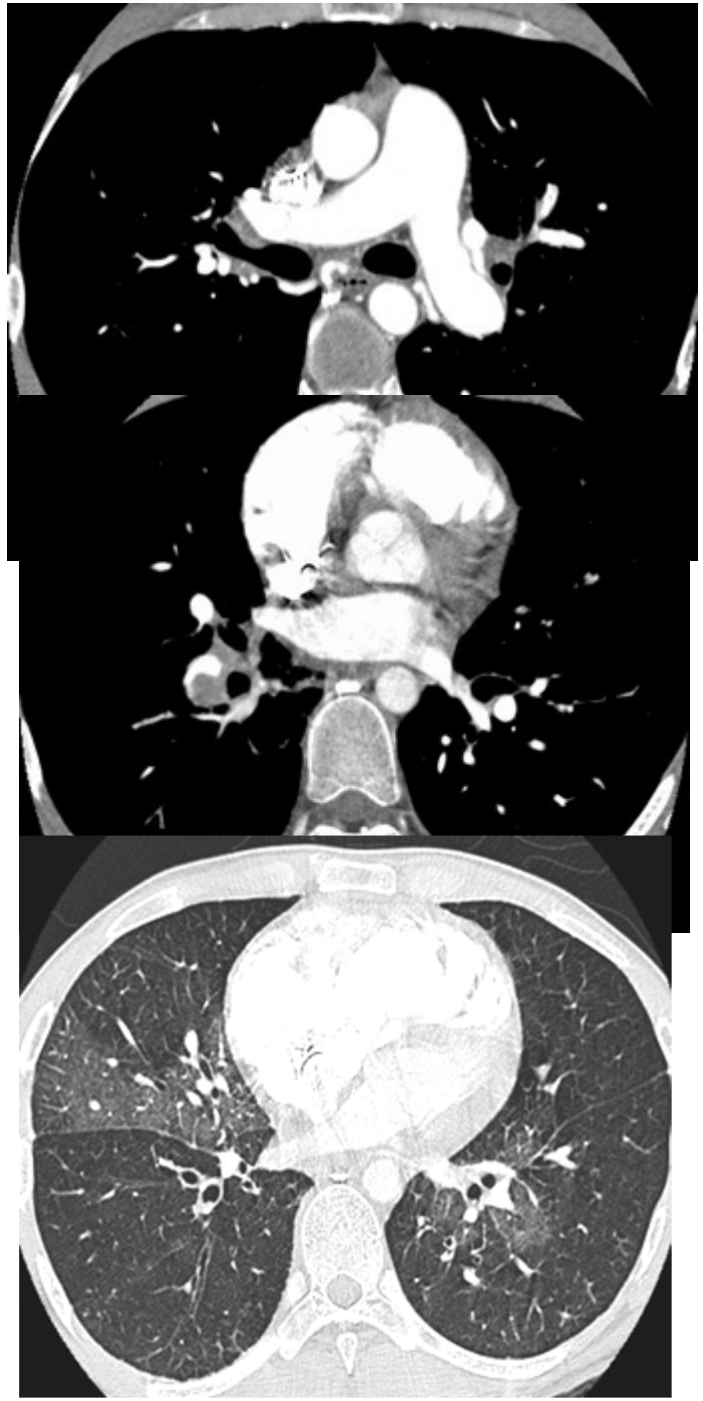

OCCLUSION CHRONIQUE

Artères de petite taille,
non opacifiées

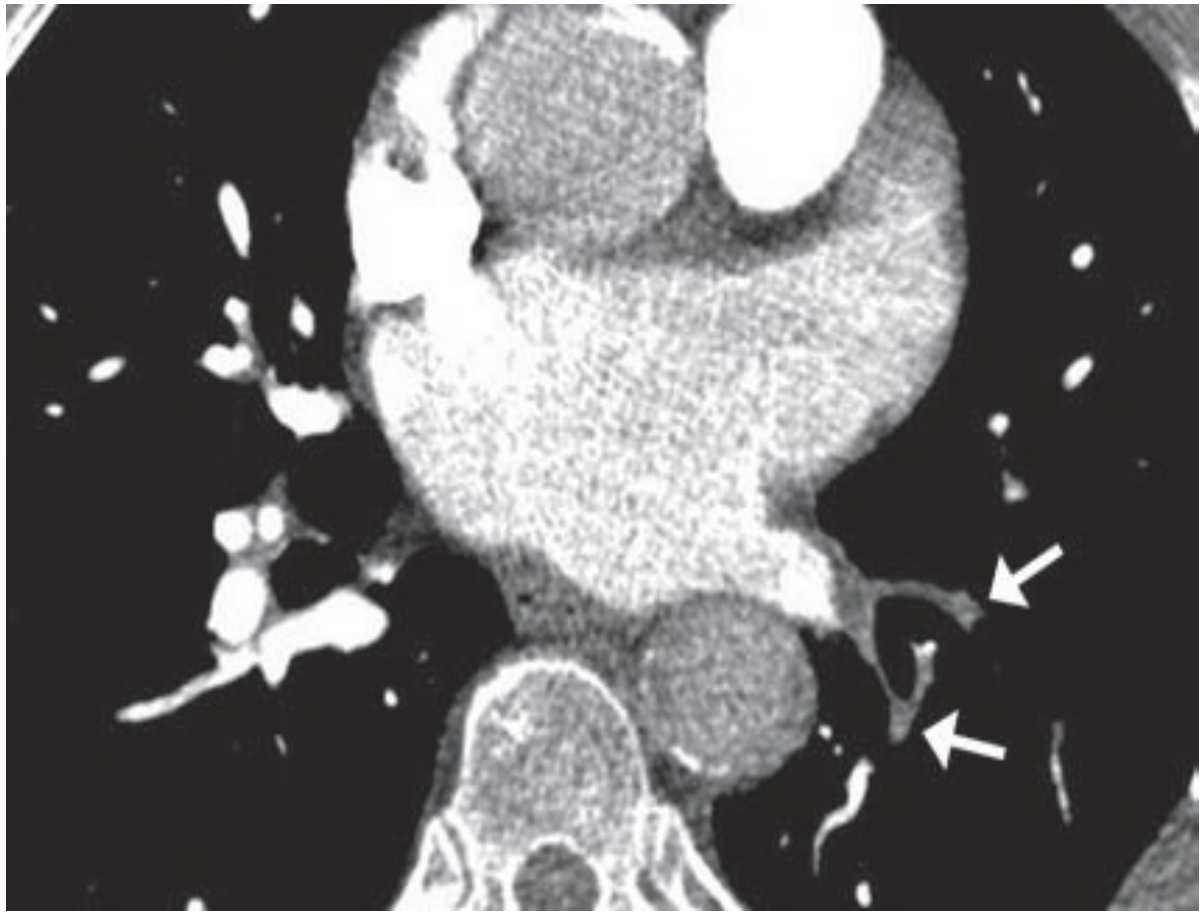

Thrombi marginés

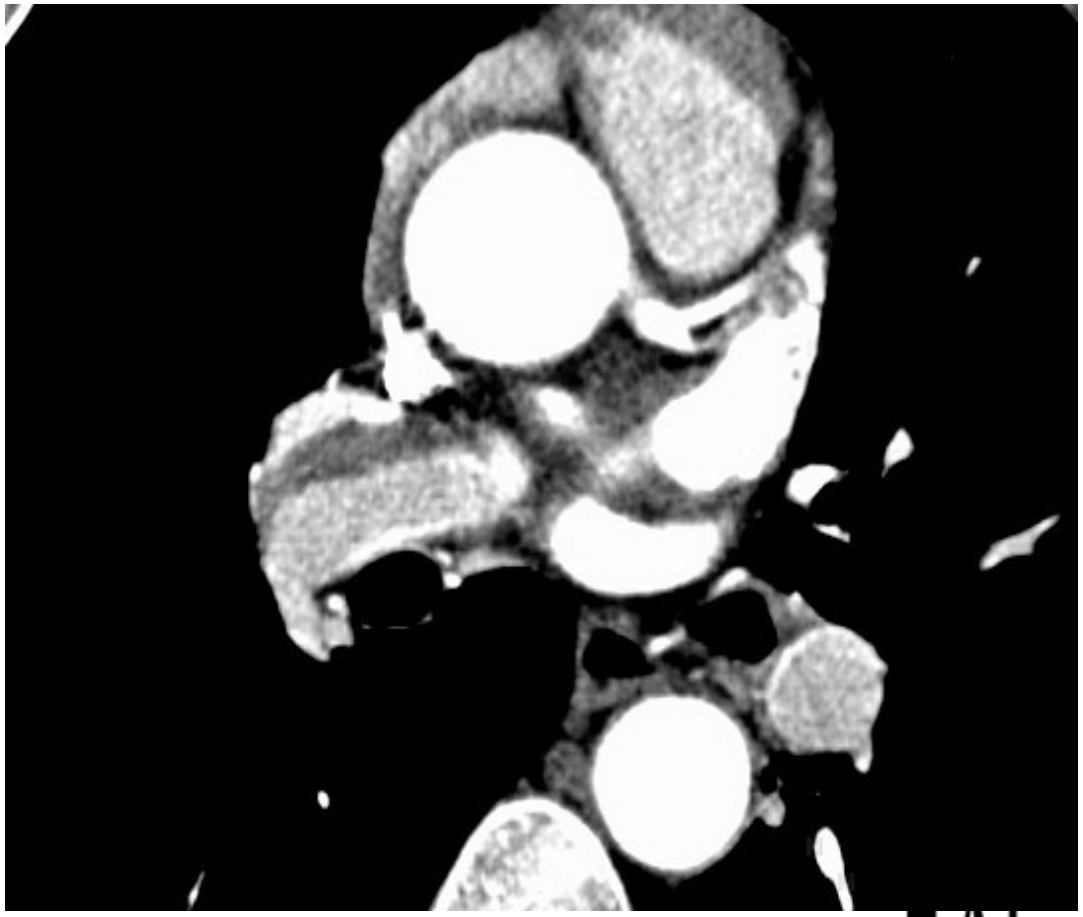

Université de Paris

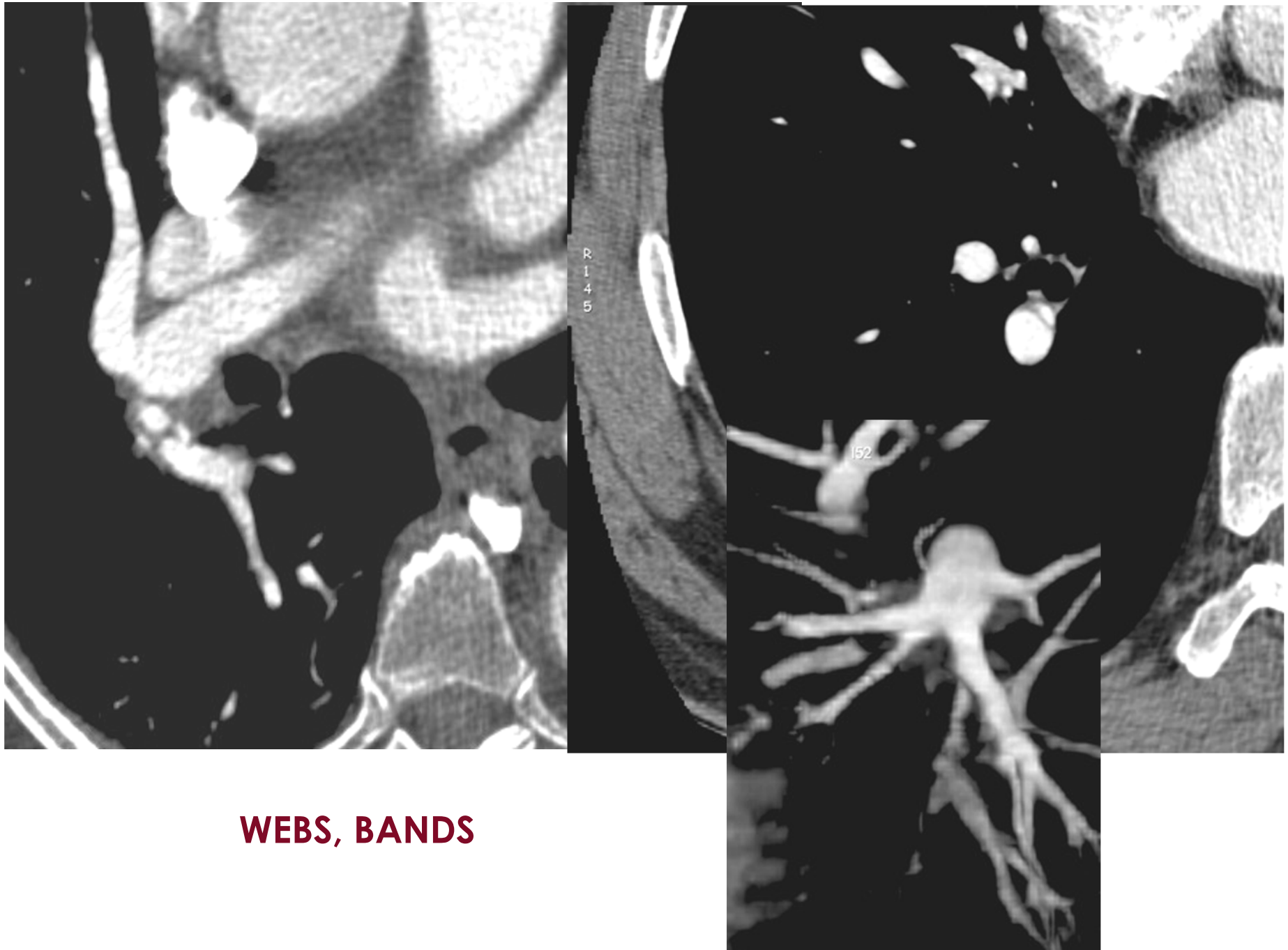

WEBS, BANDS

Université de Paris

Hypertrophie des artères bronchiques

Université de Paris

Meilleur signe de CPCPE: hypertrophie ventriculaire droite

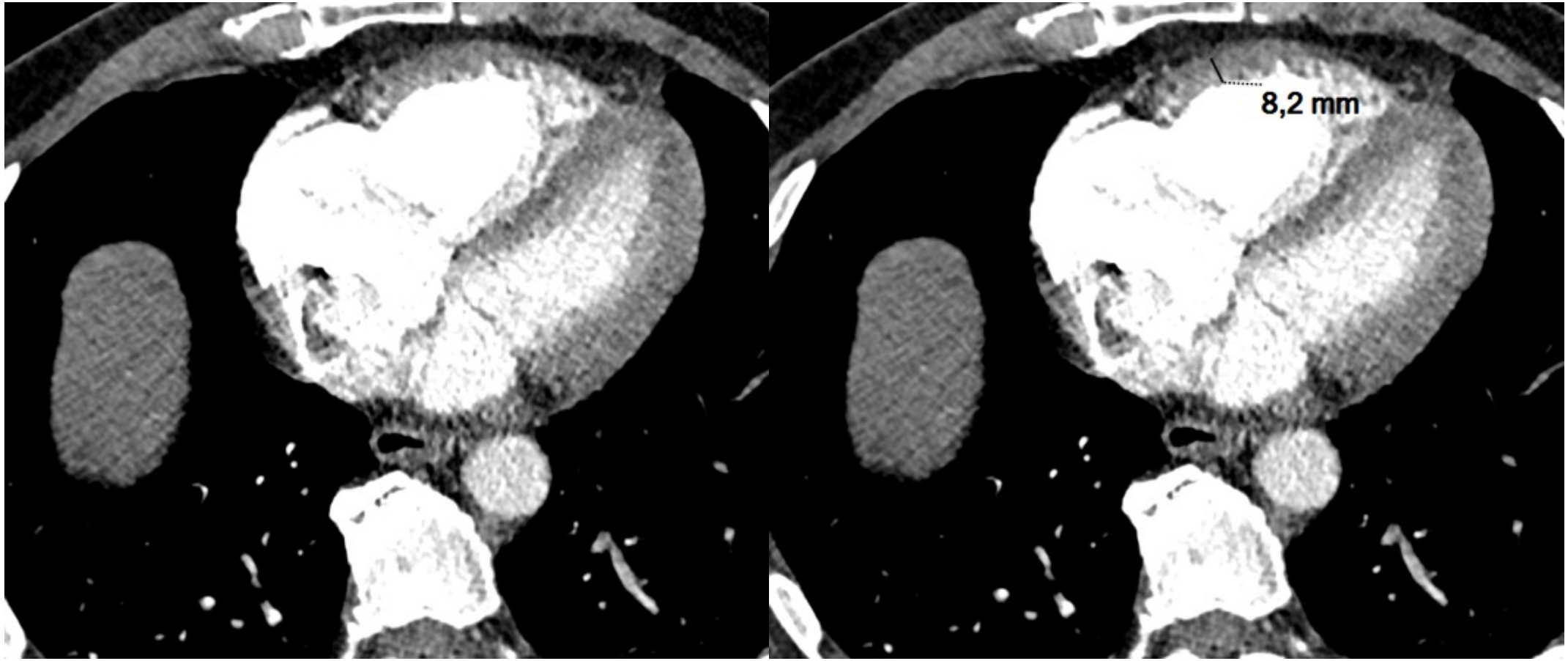

Université de Paris

Pièges

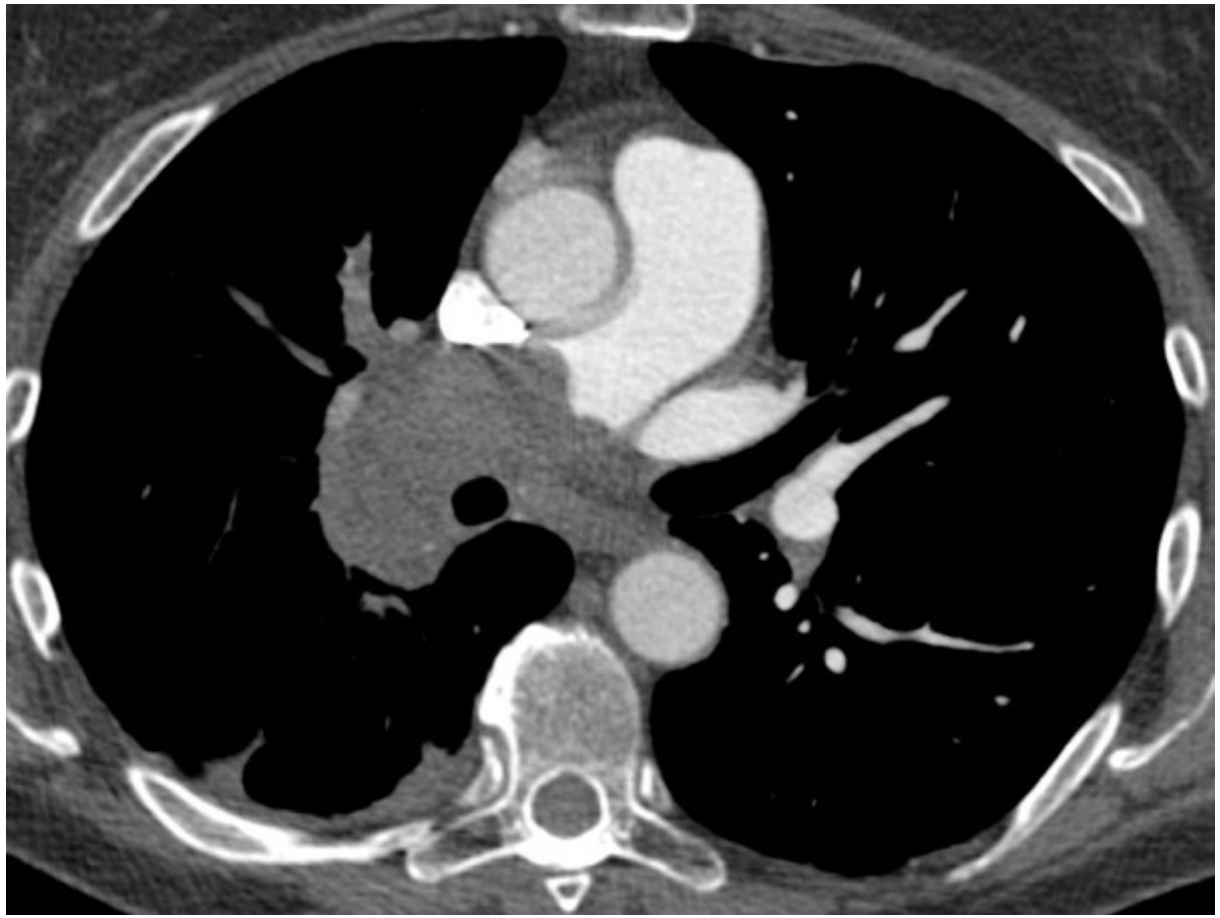

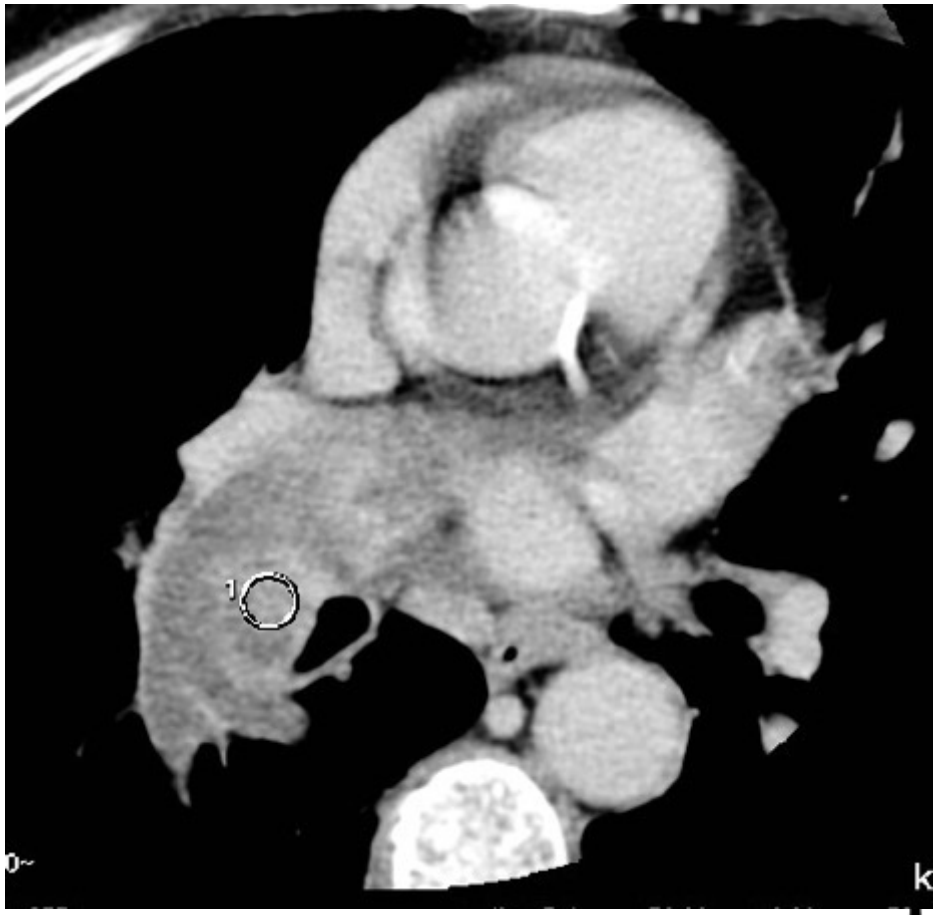

Université de Paris

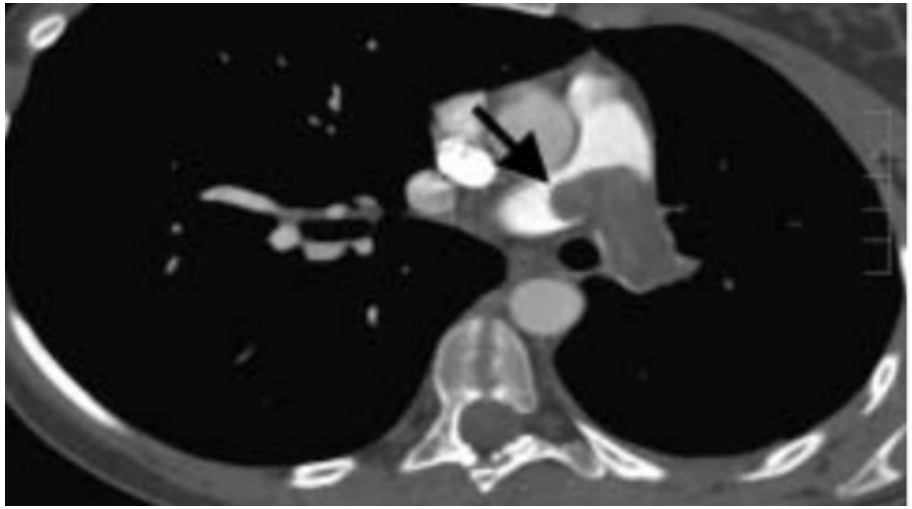

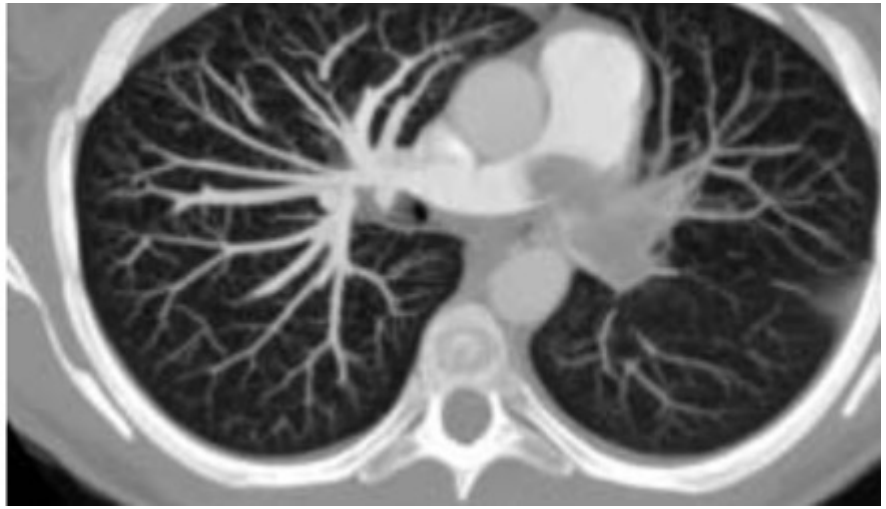

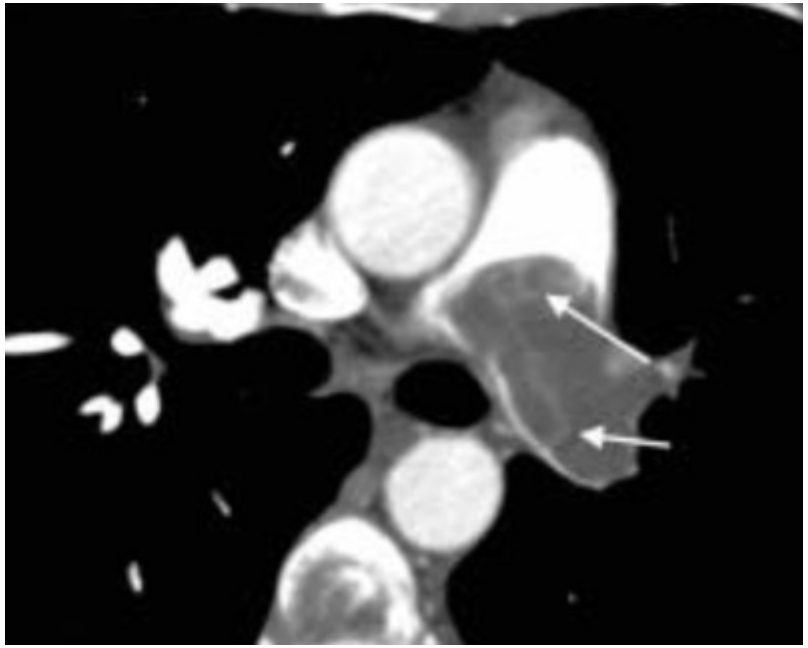

- **Le tronc pulmonaire est atteint dans 80% des cas**
- Rehaussement du pseudo thrombus
- HYPERMETABOLISME PET

Université de Paris

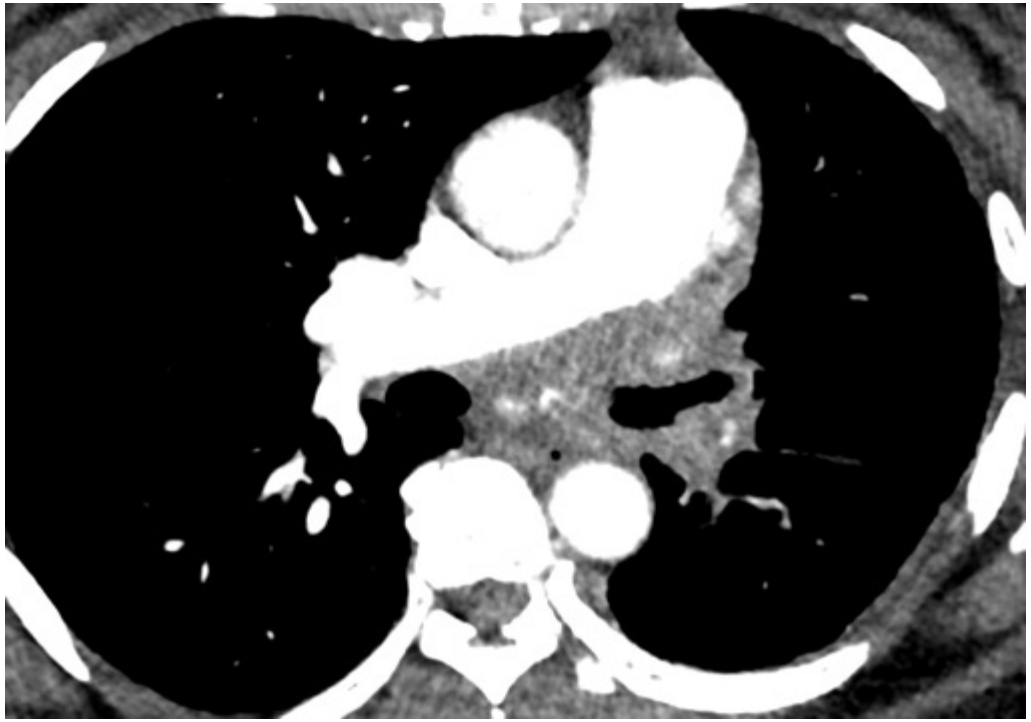

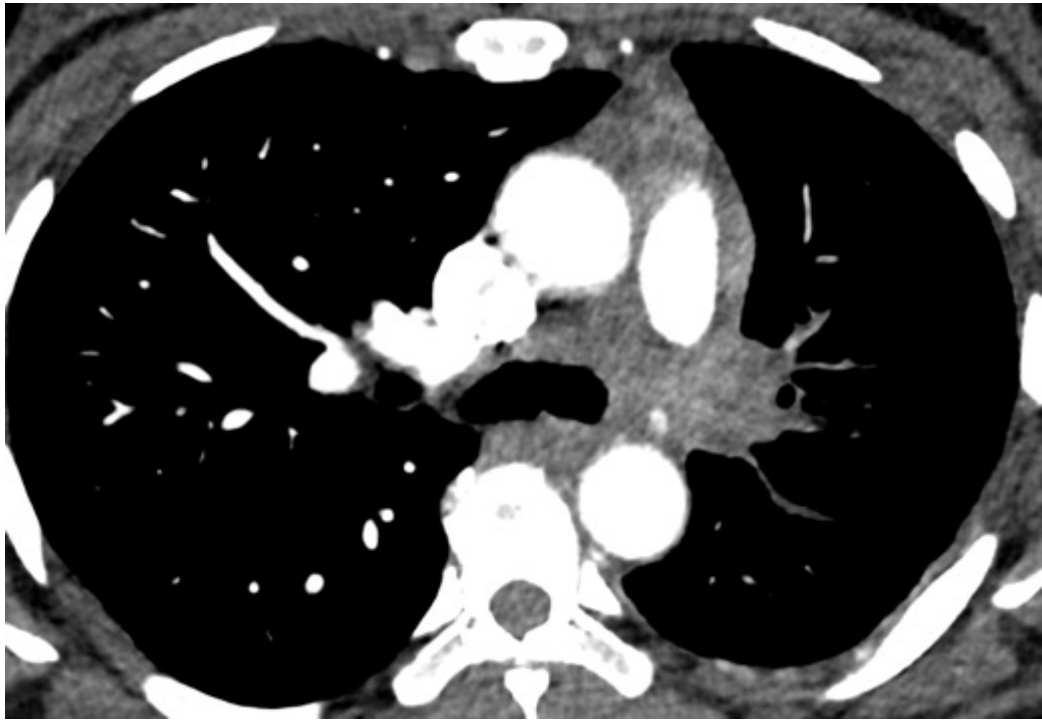

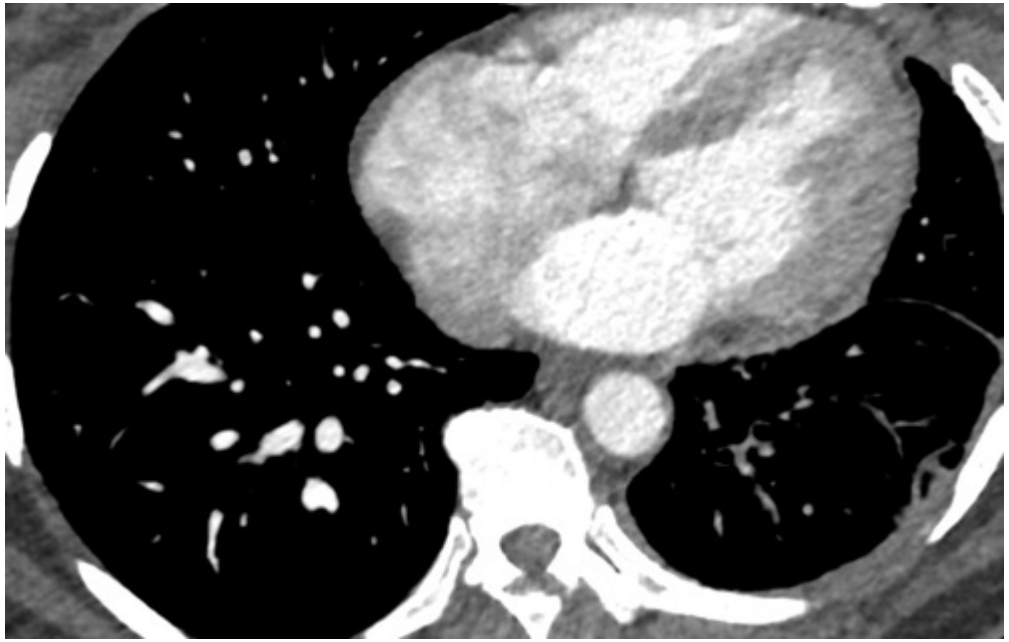

Embolies tumorales

Patient de 59 ans, antécédent de cancer du rein. Hémoptysies

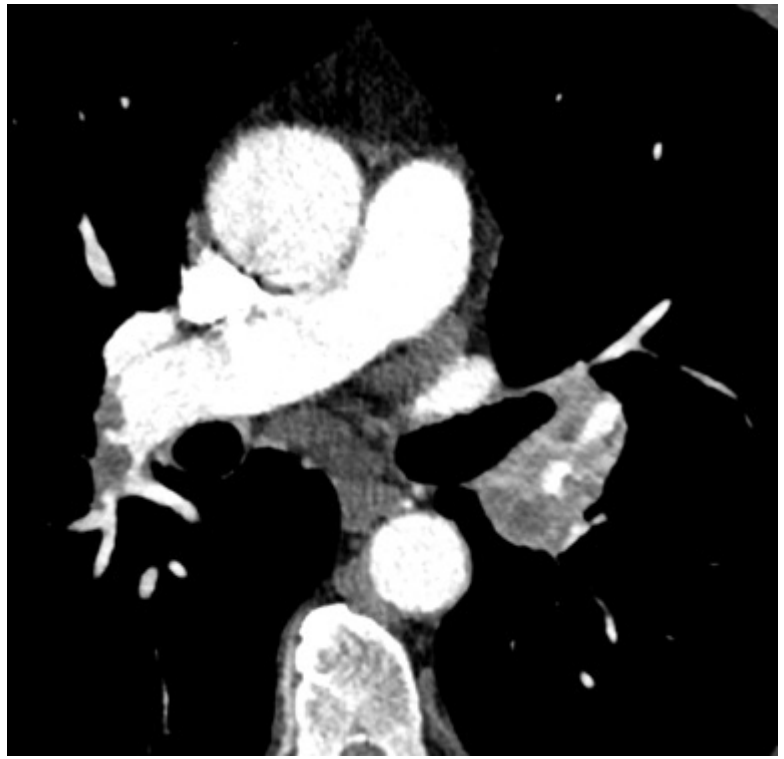

Université de Paris

H 78 ans, DDB connue, hémoptysie peu abondante

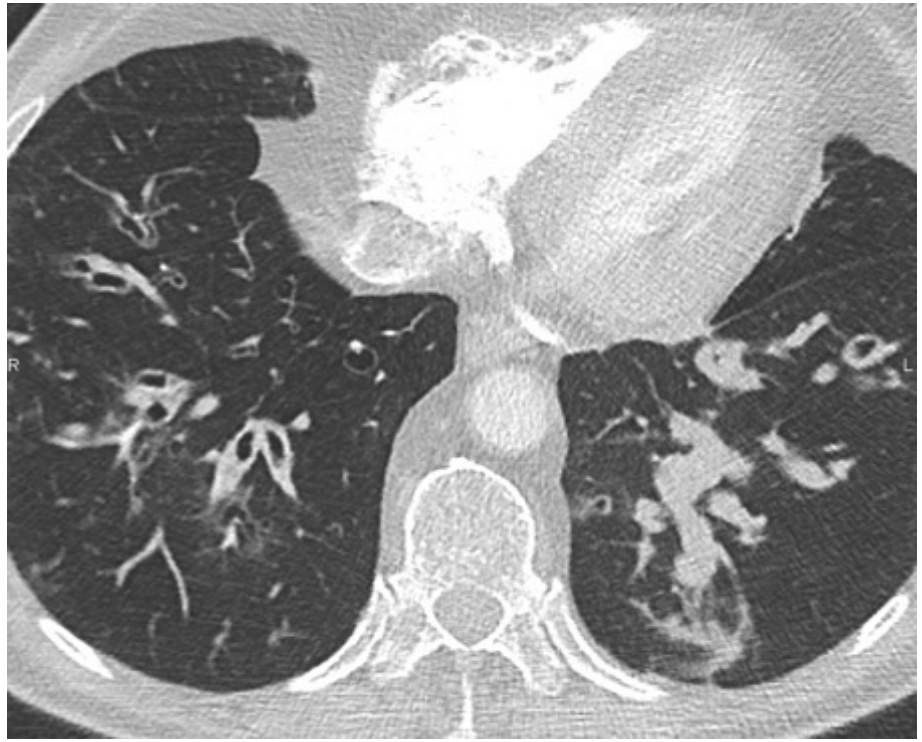

Diagnostic ?

Université de Paris

H 78 ans, DDB connue, hémoptysie peu abondante

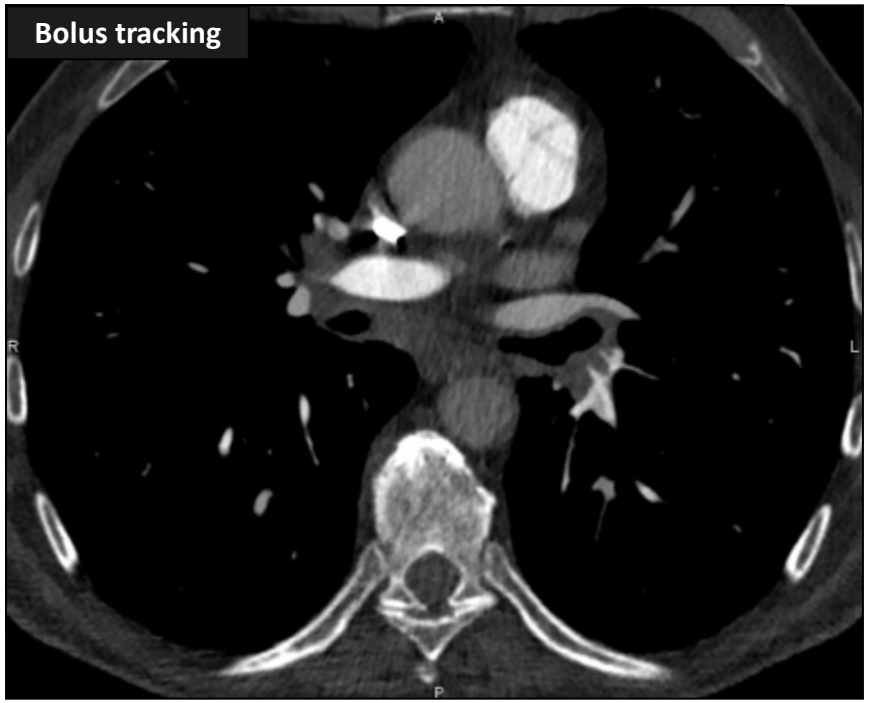

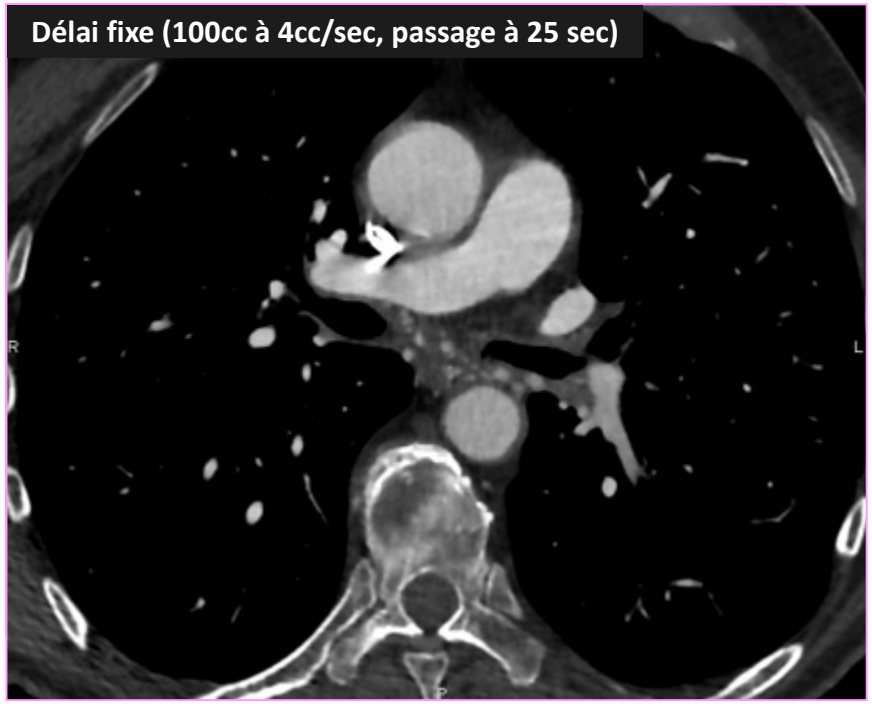

Fausse EP par shunt systémico-pulmonaire à contre-courant

Université de Paris

EP DISTALES: Attention à la surdescription

- Le diagnostic doit être **formel**
- Lacune visible sur **au moins 3 coupes successives**, **bonne opacification artérielle pulmonaire**
- **Prudence si territoire pulmonaire pathologique** (DDB: opacification à contre courant par des artères bronchiques; fibrose: vasoconstriction artérielle)

Université de Paris

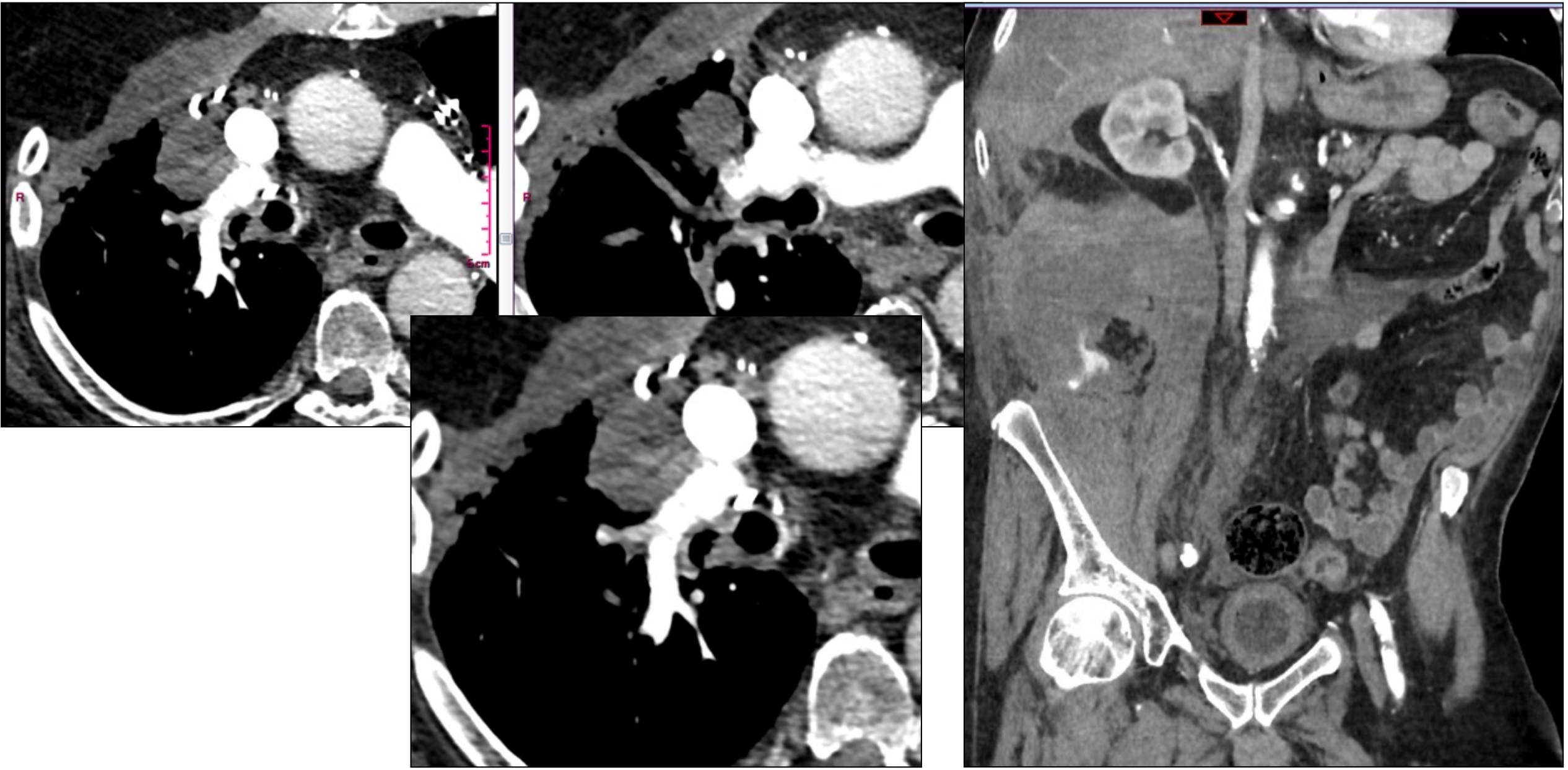
R
5cm
R

QUIZZ

Université de Paris

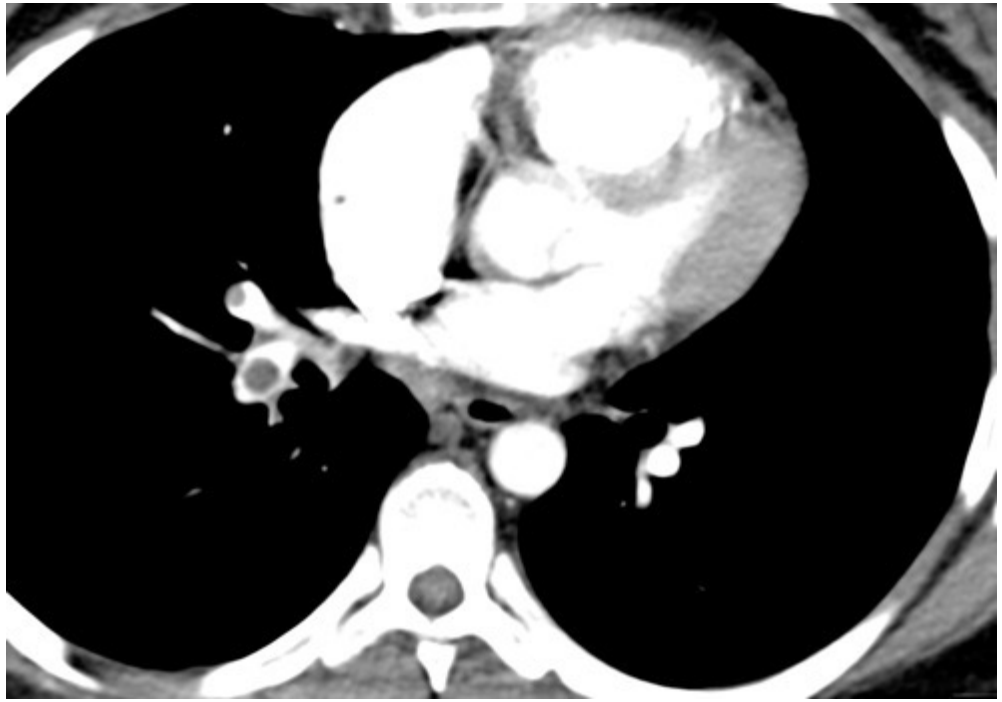

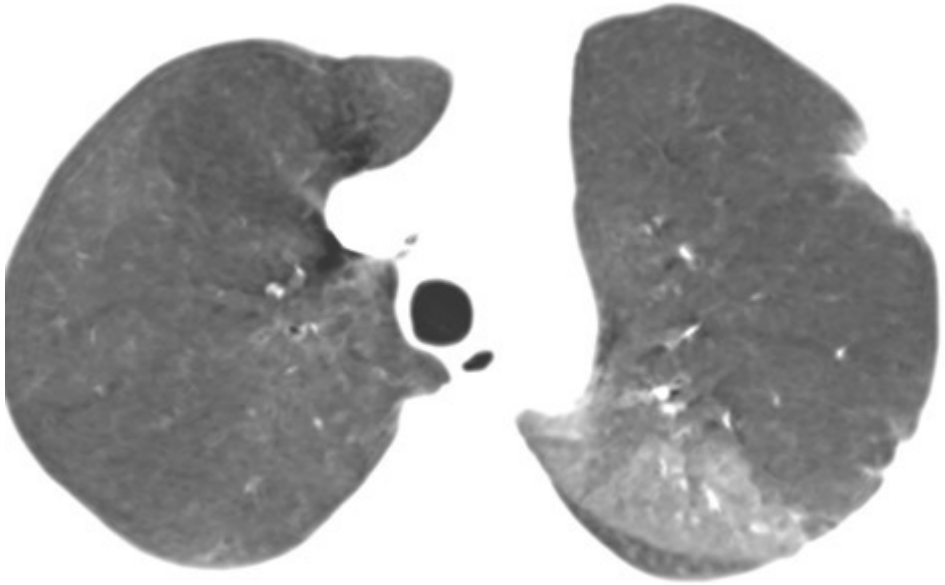

Université de Paris

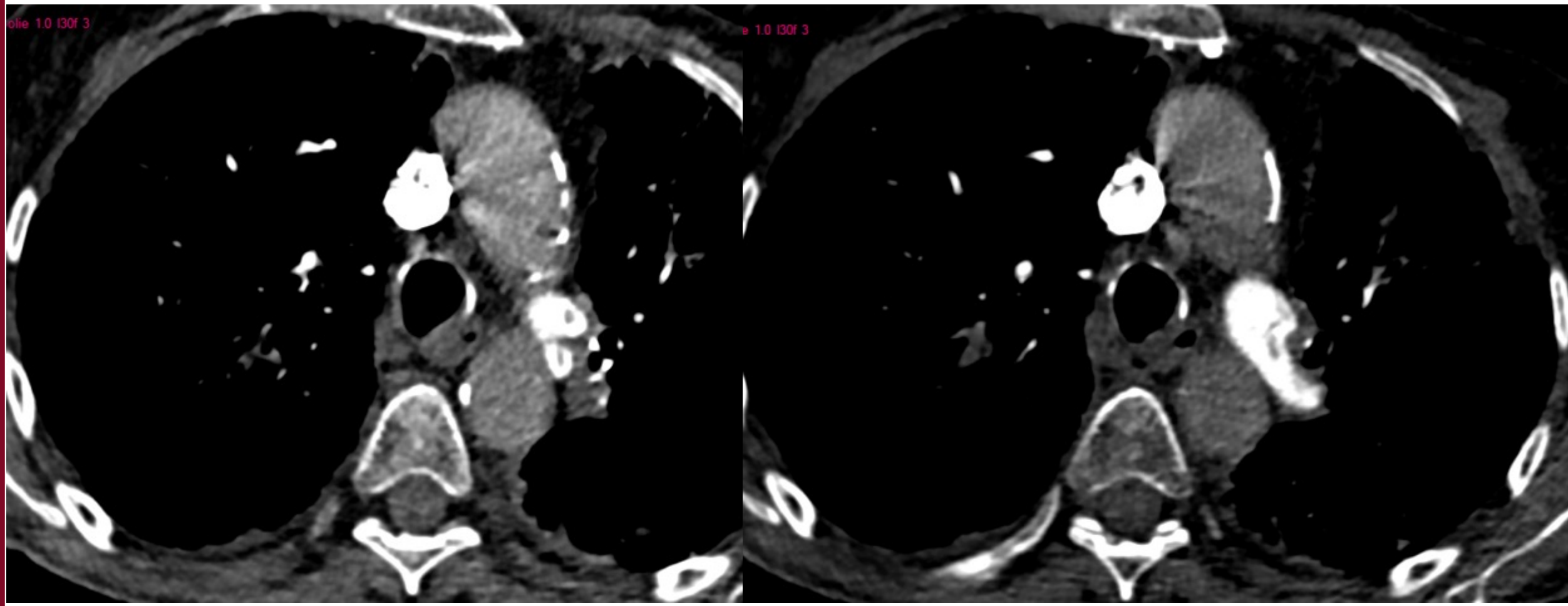

Université de Paris

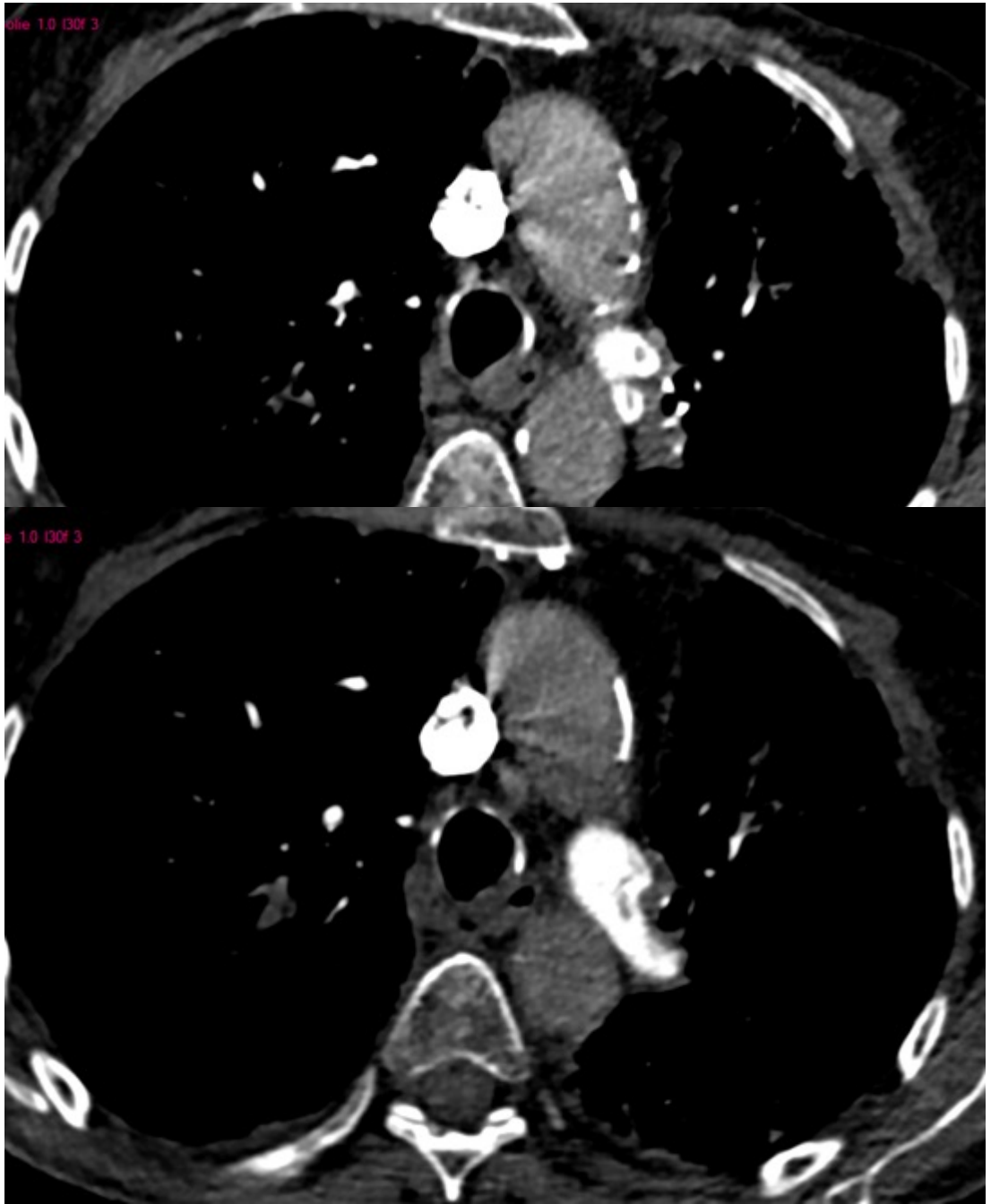
olie 1.0 I30f 3
1.0 I30f 3

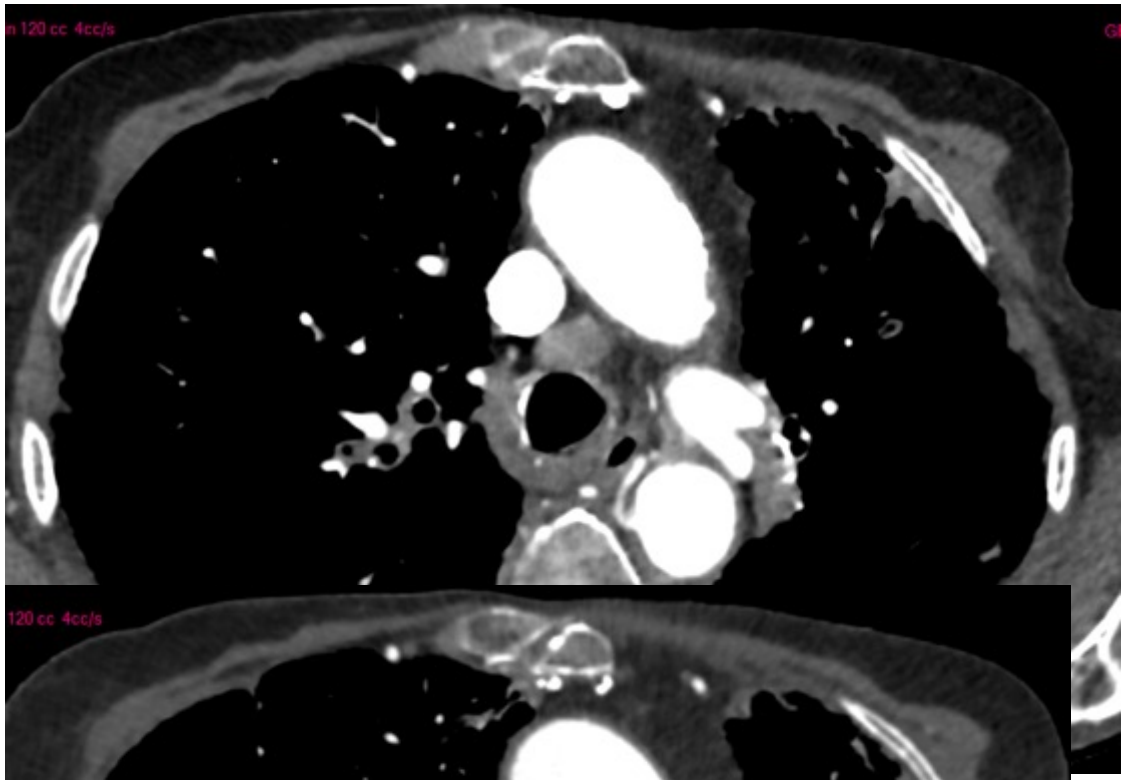
n 120 cc 4cc/s

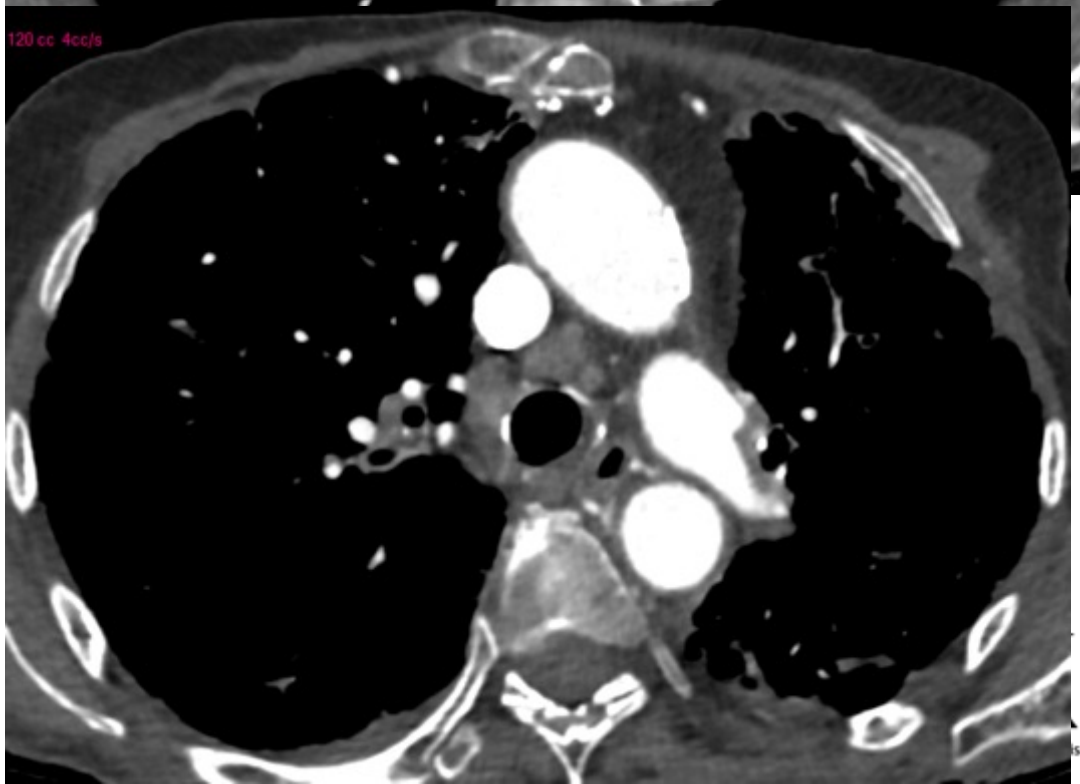
120 cc 4cc/s

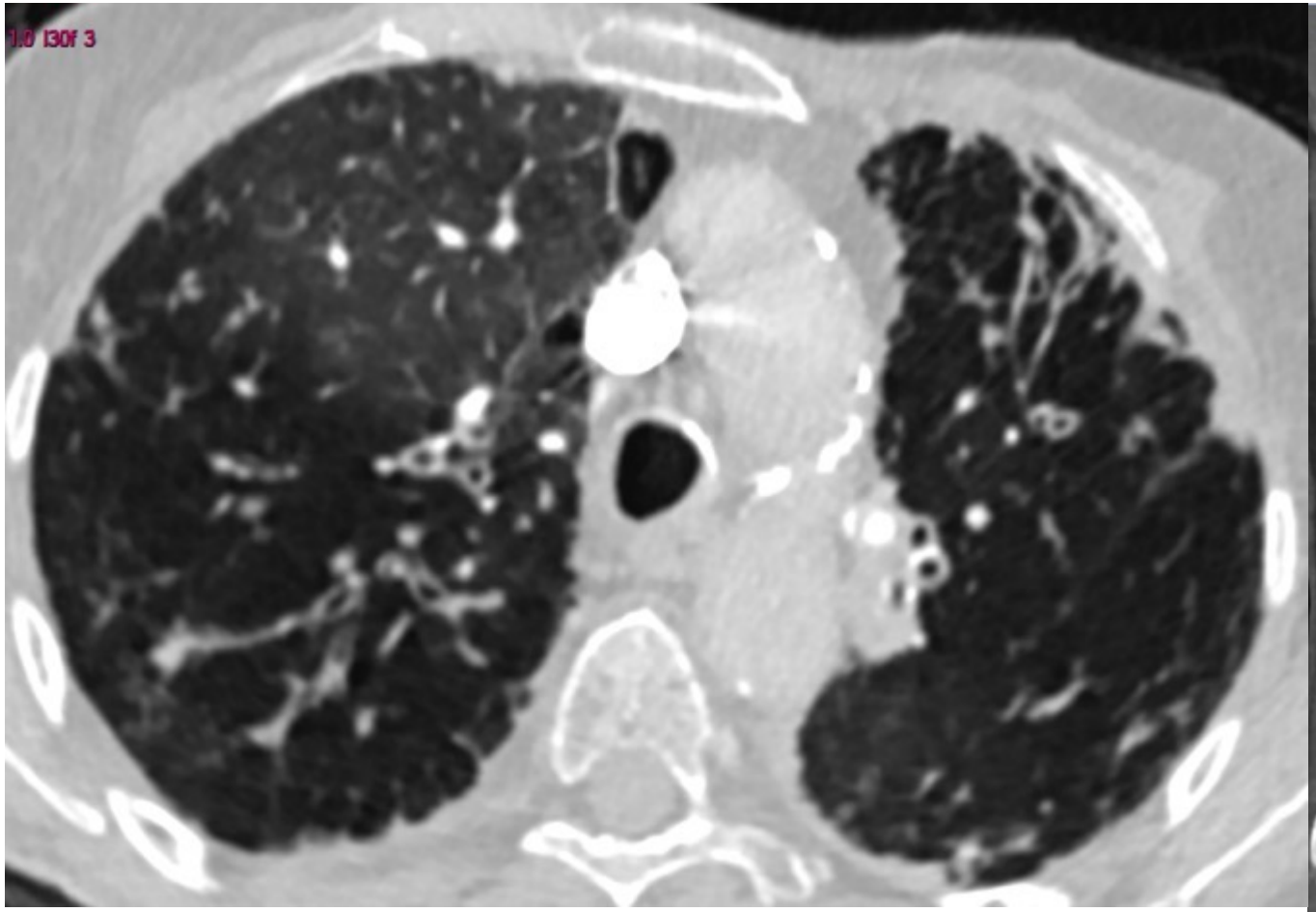

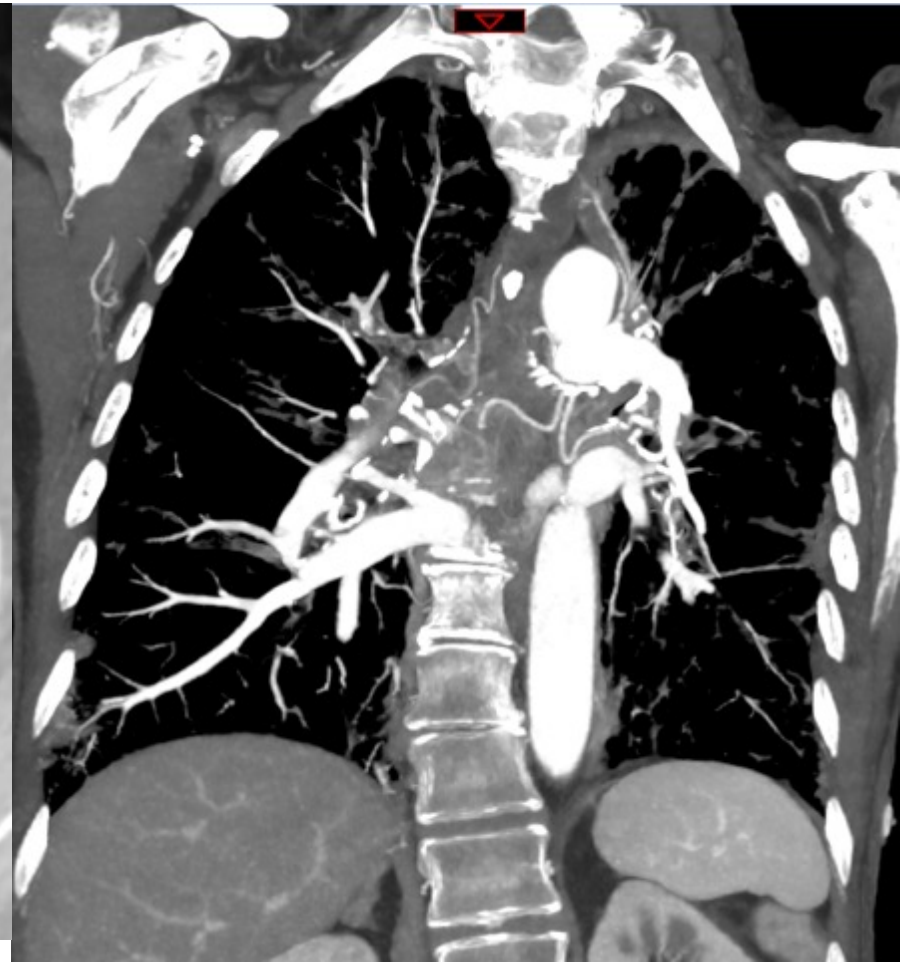

Université de Paris

Hôpital Cochin
Port-Royal
AP-HP

Université de Paris

MERCI !