Diagnostic de l'hypertension pulmonaire

Florence PARENT / Olivier SITBON

Centre de Référence de l'Hypertension Pulmonaire Sévère
Hôpital Universitaire de Bicêtre – INSERM U999
Université Paris-Sud – Le Kremlin-Bicêtre – France

UNIVERSITÉ PARIS SUD

Instituts thématiques Inserm
Institut national de la santé et de la recherche médicale

LabEx LERMIT
Laboratoire d'Excellence en Recherche sur le Médicament et l'Innovation Thérapeutique

TORINO
DHU Thorax Innovation

Hôpitaux universitaires Paris-Sud
Antoine-Béclère Bicêtre Paul-Brousse

Introduction

- Purpose of diagnostic work-up
  - Confirm the diagnosis
  - Identify the cause
  - Establish disease severity and prognosis of patients
- Diagnostic testing often extensive
- Sequence of diagnostic testing influenced by history (e.g. indication of pulmonary angiogram)

Main issues in PH diagnosis

- Misclassification
- Misleading investigations
- Late referral to expert centers
- Patients under- / over-treated

- Need for an accurate diagnosis in all cases

European Heart Journal (2016) **37**, 67–119
doi:10.1093/eurheartj/ehv317

ESC/ERS GUIDELINES
Eur Respir J 2015; 46: 903–975

2015 ESC/ERS Guidelines for the diagnosis and treatment of pulmonary hypertension

The Joint Task Force for the Diagnosis and Treatment of Pulmonary Hypertension of the European Society of Cardiology (ESC) and the European Respiratory Society (ERS)

Endorsed by: Association for European Paediatric and Congenital Cardiology (AEPC), International Society for Heart and Lung Transplantation (ISHLT)

Authors/Task Force Members: Nazzareno Galiè* (ESC Chairperson) (Italy), Marc Humbert*[a] (ERS Chairperson) (France), Jean-Luc Vachiery[c] (Belgium), Simon Gibbs (UK), Irene Lang (Austria), Adam Torbicki (Poland), Gérald Simonneau[a] (France), Andrew Peacock[a] (UK), Anton Vonk Noordegraaf[a] (The Netherlands), Maurice Beghetti[b] (Switzerland), Ardeschir Ghofrani[a] (Germany), Miguel Angel Gomez Sanchez (Spain), Georg Hansmann[b] (Germany), Walter Klepetko[c] (Austria), Patrizio Lancellotti (Belgium), Marco Matucci[d] (Italy), Theresa McDonagh (UK), Luc A. Pierard (Belgium), Pedro T. Trindade (Switzerland), Maurizio Zompatori[e] (Italy) and Marius Hoeper[a] (Germany)

Hemodynamic definition of pulmonary hypertension (RHC measurements)

Definition	Characteristics[a]
PH	PAPm ≥25 mmHg
Pre-capillary PH	PAPm ≥25 mmHg PAWP ≤15 mmHg
Post-capillary PH	PAPm ≥25 mmHg PAWP >15 mmHg
Isolated post-capillary PH (Ipc-PH)	DPG <7 mmHg and/or PVR ≤3 WU[c]
Combined post-capillary and pre-capillary PH (Cpc-PH)	DPG ≥7 mmHg and/or PVR >3 WU[c]

Vachiéry JL, et al. J Am Coll Cardiol 2013.
Galiè N. et al. ESC/ERS Guidelines. Eur Heart J 2016 & Eur Respir J 2015.

Définition de l'hypertension pulmonaire

HTP précapillaire

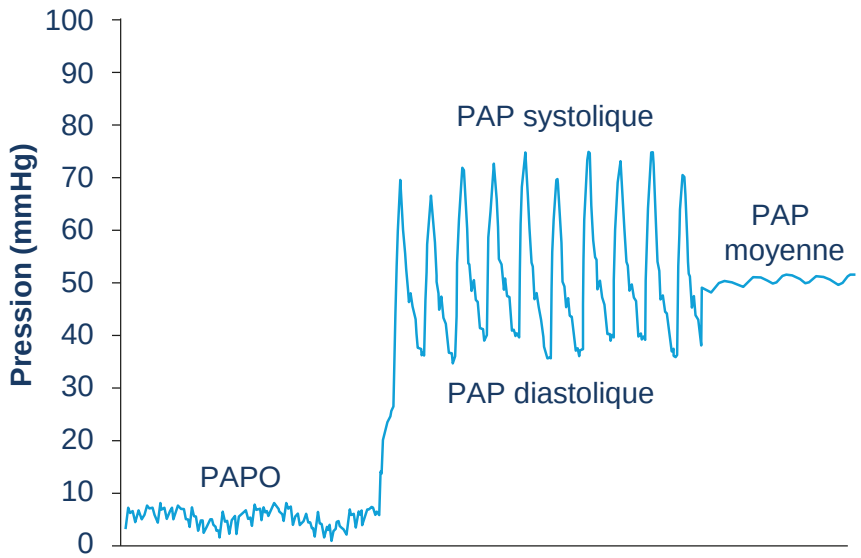

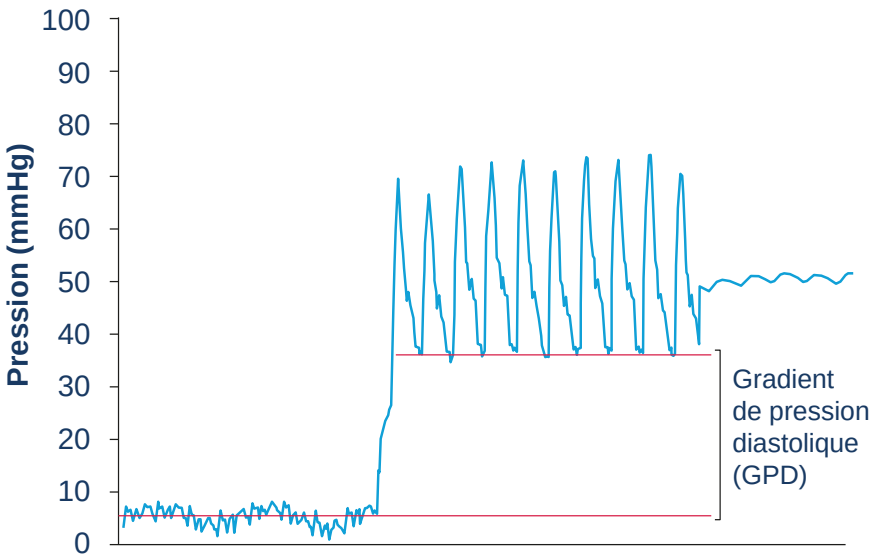

HTAP

- ✔ PAPm ≥ 25 mmHg
- ✔ PAPO ≤ 15 mmHg
- ✔ RVP > 3 UW (HTAP)

Clinical classification of pulmonary hypertension (PH)

1. Pulmonary arterial hypertension

1.1 Idiopathic
1.2 Heritable
  1.2.1 BMPR2 mutation
  1.2.2 Other mutations
1.3 Drugs and toxins induced
1.4 Associated with:
  1.4.1 Connective tissue disease
  1.4.2 Human immunodeficiency virus (HIV) infection
  1.4.3 Portal hypertension
  1.4.4 Congenital heart disease (Table 6)
  1.4.5 Schistosomiasis

1'. Pulmonary veno-occlusive disease and/or pulmonary capillary haemangiomatosis

1'.1 Idiopathic
1'.2 Heritable
  1'.2.1 EIF2AK4 mutation
  1'.2.2 Other mutations
1'.3 Drugs, toxins and radiation induced
1'.4 Associated with:
  1'.4.1 Connective tissue disease
  1'.4.2 HIV infection

1''. Persistent pulmonary hypertension of the newborn

2. Pulmonary hypertension due to left heart disease

2.1 Left ventricular systolic dysfunction
2.2 Left ventricular diastolic dysfunction
2.3 Valvular disease
2.4 Congenital/acquired left heart inflow/outflow tract obstruction and congenital cardiomyopathies
2.5 Congenital/acquired pulmonary veins stenosis

3. Pulmonary hypertension due to lung diseases and/or hypoxia

3.1 Chronic obstructive pulmonary disease
3.2 Interstitial lung disease
3.3 Other pulmonary diseases with mixed restrictive and obstructive pattern
3.4 Sleep-disordered breathing
3.5 Alveolar hypoventilation disorders
3.6 Chronic exposure to high altitude
3.7 Developmental lung diseases (Web Table III)

4. Chronic thromboembolic pulmonary hypertension and other pulmonary artery obstructions

4.1 Chronic thromboembolic pulmonary hypertension
4.2 Other pulmonary artery obstructions
  4.2.1 Angiosarcoma
  4.2.2 Other intravascular tumors
  4.2.3 Arteritis
  4.2.4 Congenital pulmonary arteries stenoses
  4.2.5 Parasites (hydatidosis)

5. Pulmonary hypertension with unclear and/or multifactorial mechanisms

5.1 Haematological disorders: chronic haemolytic anaemia, myeloproliferative disorders, splenectomy
5.2 Systemic disorders: sarcoidosis, pulmonary histiocytosis, lymphangioleiomyomatosis, neurofibromatosis
5.3 Metabolic disorders: glycogen storage disease, Gaucher disease, thyroid disorders
5.4 Others: pulmonary tumoral thrombotic microangiopathy, fibrosing mediastinitis, chronic renal failure (with/without dialysis), segmental pulmonary hypertension

Galiè N. et al. ESC/ERS Guidelines. Eur Heart J 2016 & Eur Respir J 2015.

Clinical assessment

- Reason to suspect PAH
  - Family History (BMPR-II, ALK-1, HHT?)
  - Connective tissue disease
  - Congenital heart disease
  - Portal hypertension
  - Anorexigen exposure
  - HIV infection
- To suspect non-PAH PH
  - DVT/PE history
  - Rheumatic heart disease
  - Ischaemic heart disease
  - Systemic hypertension (metabolic syndrome)
  - Snoring/ Somnolence
  - Tobacco

HTP: Signes cliniques

Signes fonctionnels d’appel

- Dyspnée d'effort, non spécifique = maître symptôme.
- Retrouvée dans plus de 90% des cas, elle est progressivement croissante, responsable d'un retentissement fonctionnel sur les activités quotidiennes et pouvant être à l'origine d'une dyspnée au moindre effort à un stade évolué de la maladie.
- Autres symptômes moins fréquents :
  - asthénie,
  - lipothymies à l’effort,
  - syncopes,
  - douleurs angineuses,
  - palpitations,
  - hémoptysies.

PAH: Non specific symptoms

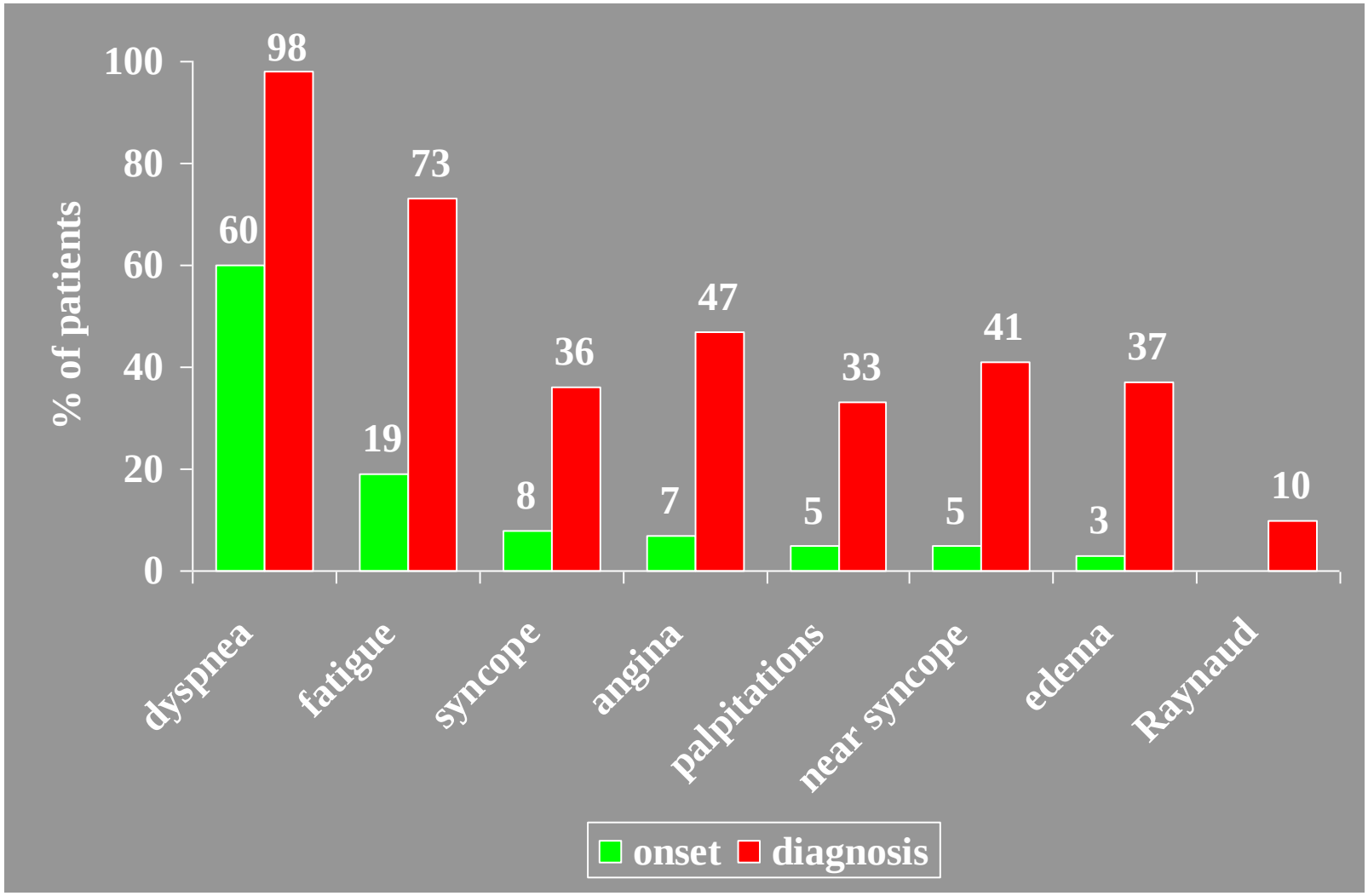

Rich S, et al. Ann Intern Med 1987.

Physical examination

- Pulmonary Hypertension
  - Abn heart auscultation
    - Loud S2
    - S3 or S4
    - Systolic murmur TR
    - Diastolic murmur PI
- Right heart dysfunction
  - jugular venous distension
  - hepatojugular reflux
  - hepatomegaly
  - ascites
  - peripheral edema (lower limbs)
- Associated disease

Systemic sclerosis (CREST)
- Calcinosis
- Raynaud's
- Oesophageal dysmotility
- Sclerodactily
- Telangiectasia

Eisenmenger's
- Cyanosis
- Clubbing

Cirrhosis

Etc…

Measurement of pulmonary artery pressure

Doppler echocardiography

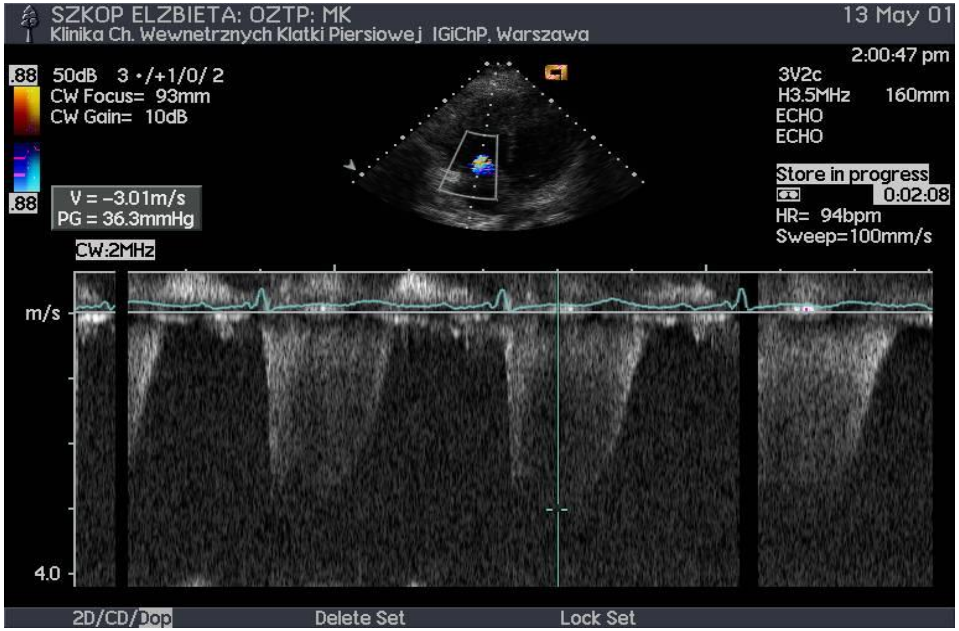

Right Heart Cath.

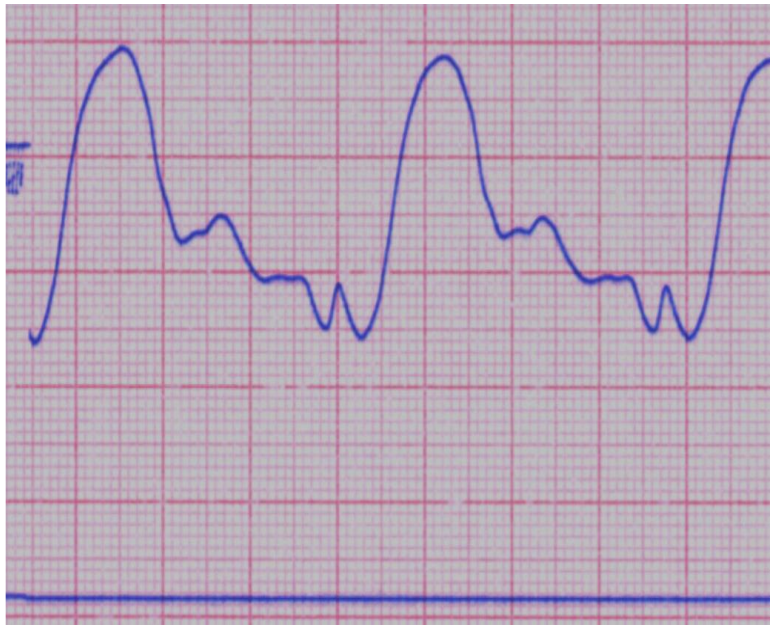

Estimation from TRJV

Systolic PAP =

(TRJV max)^2+ RAP(estimated)

Gold Standard Tool

Echocardiographie: estimation de la PAPs

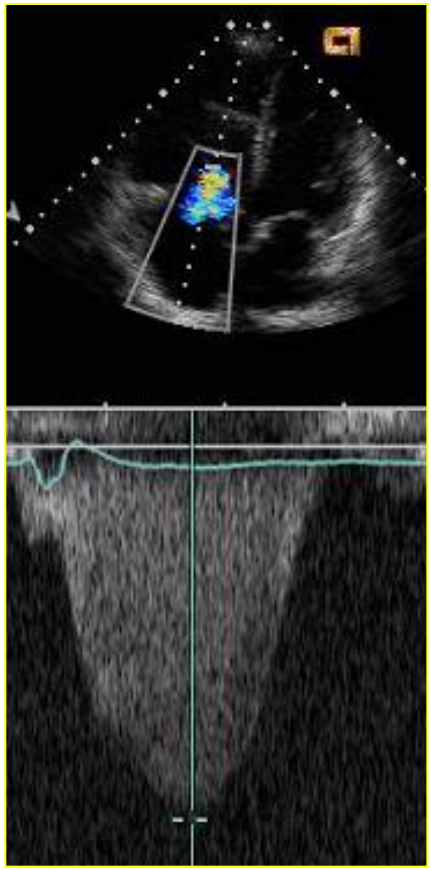

PVDs = PAPs = Gradient IT + POD

Selon l'équation de Bernoulli ($\Delta P = 4 \times V^2$)

Grad IT = $4 \times V_{IT}^2$

Echocardiographie: estimation de la POD

Inferior vena cava diameter	Change with respiration	Estimated right atrial pressure mmHg
Small <1.5 cm	Collapse	0
Normal 1.5–2.5 cm	Decrease by >50%	5
Normal	Decrease by <50%	10
Dilated >2.5 cm	Decrease by <50%	15
Dilated with dilated hepatic veins	No change	20

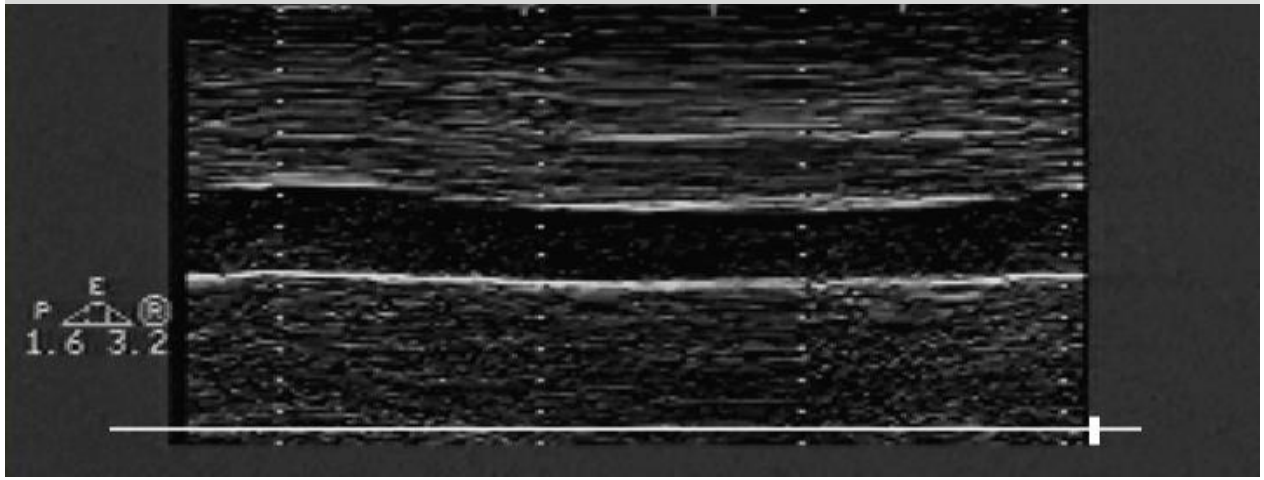

Adapted from Howard LS et al. ERR 2012

Place de l'échographie cardiaque dans le diagnostic de l'HTP chez un patient symptomatique

- Doit toujours être réalisée quand une HTP est suspectée (examen de première intention) (I-C)
- Se référer aux recommandations de *l'European Association of Cardiovascular Imaging*[1,2]
- Évaluation de la probabilité d'une HTP chez un patient symptomatique

1. *Rudski LG et al. J Am Soc Echocardiogr 2010;23:685-713.*
2. *Lang RM et al. Eur Heart J Cardiovasc Imaging 2015;16:233-71.*

Place de l'échographie cardiaque dans le diagnostic de l'HTP chez un patient symptomatique

V_{IT}
(≤ 2,8 ; 2,9 – 3,4 ; > 3,4 m/s)

↓

Présence d'autres signes échographiques d'HTP
(ventricules, artère pulmonaire, veine cave inférieure et oreillette droite)

↓

Probabilité d'HTP
faible, intermédiaire, élevée

Présence ou absence de facteurs de risque d'HTAP ou d'HTP-TEC

↓

Décision de cathétérisme cardiaque droit

1. *Rudski LG et al. J Am Soc Echocardiogr 2010;23:685-713.*
2. *Lang RM et al. Eur Heart J Cardiovasc Imaging 2015;16:233-71.*

Place de l'échographie cardiaque dans le diagnostic de l'HTP chez un patient symptomatique

Table 8A Echocardiographic probability of pulmonary hypertension in symptomatic patients with a suspicion of pulmonary hypertension

Peak tricuspid regurgitation velocity (m/s)	Presence of other echo 'PH signs'[a]	Echocardiographic probability of pulmonary hypertension
≤2.8 or not measurable	No	Low
≤2.8 or not measurable	Yes	Intermediate
2.9–3.4	No	
2.9–3.4	Yes	High
>3.4	Not required	

Table 8B Echocardiographic signs suggesting pulmonary hypertension used to assess the probability of pulmonary hypertension in addition to tricuspid regurgitation velocity measurement in *Table 8A*

A: The ventricles[a]	B: Pulmonary artery[a]	C: Inferior vena cava and right atrium[a]
Right ventricle/ left ventricle basal diameter ratio >1.0	Right ventricular outflow Doppler acceleration time <105 msec and/or midsystolic notching	Inferior cava diameter >21 mm with decreased inspiratory collapse (<50 % with a sniff or <20 % with quiet inspiration)
Flattening of the interventricular septum (left ventricular eccentricity index >1.1 in systole and/or diastole)	Early diastolic pulmonary regurgitation velocity >2.2 m/sec	Right atrial area (end-systole) >18 cm^2
	PA diameter >25 mm.	

Galiè N. et al. ESC/ERS Guidelines. Eur Heart J 2016 & Eur Respir J 2015.

Pulmonary hypertension – Echo *vs* RHC

In dedicated studies and central lab…

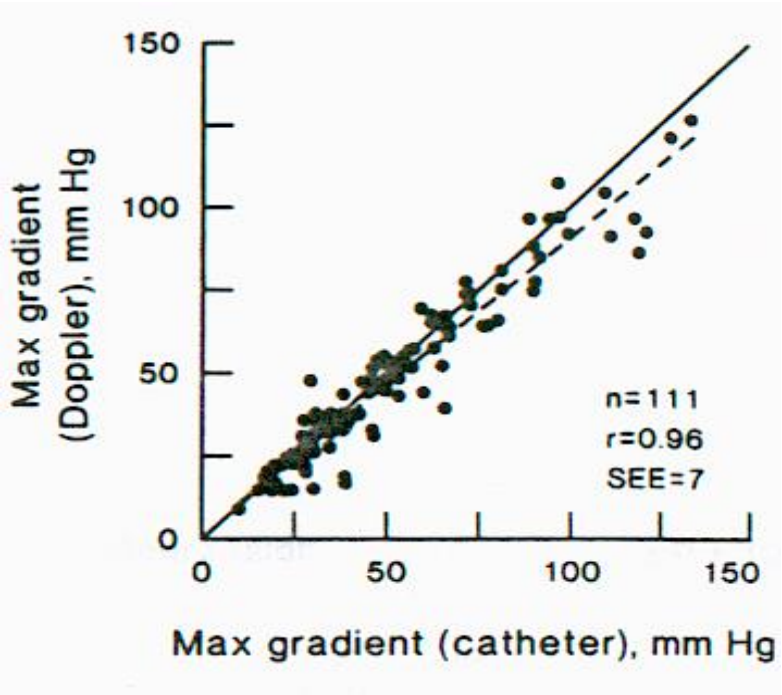

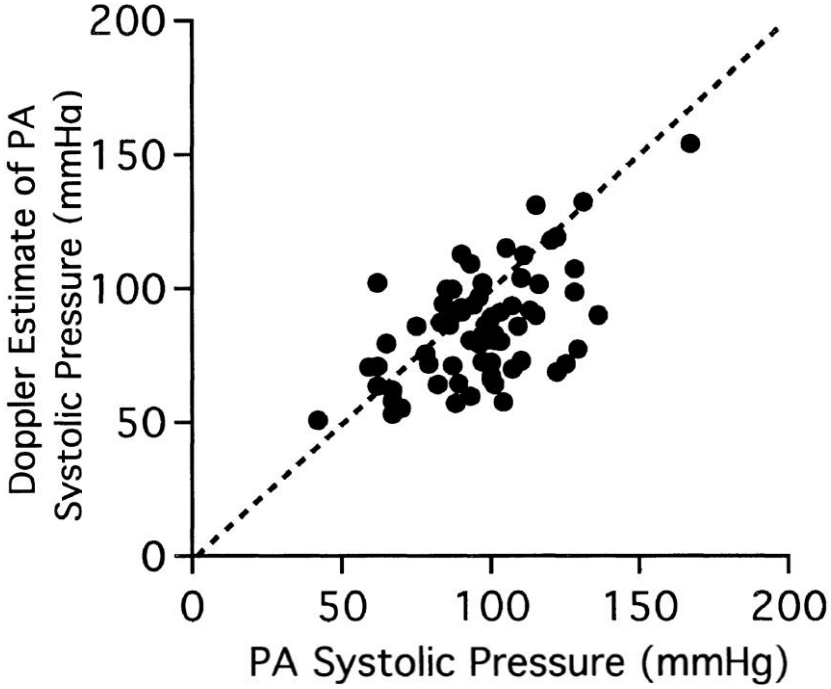

Currie et al J Am Coll Cardiol 1985.

Hinderliter, A. L. et al. Circulation 1997;95:1479-86.

Pulmonary hypertension – Echo *vs* RHC

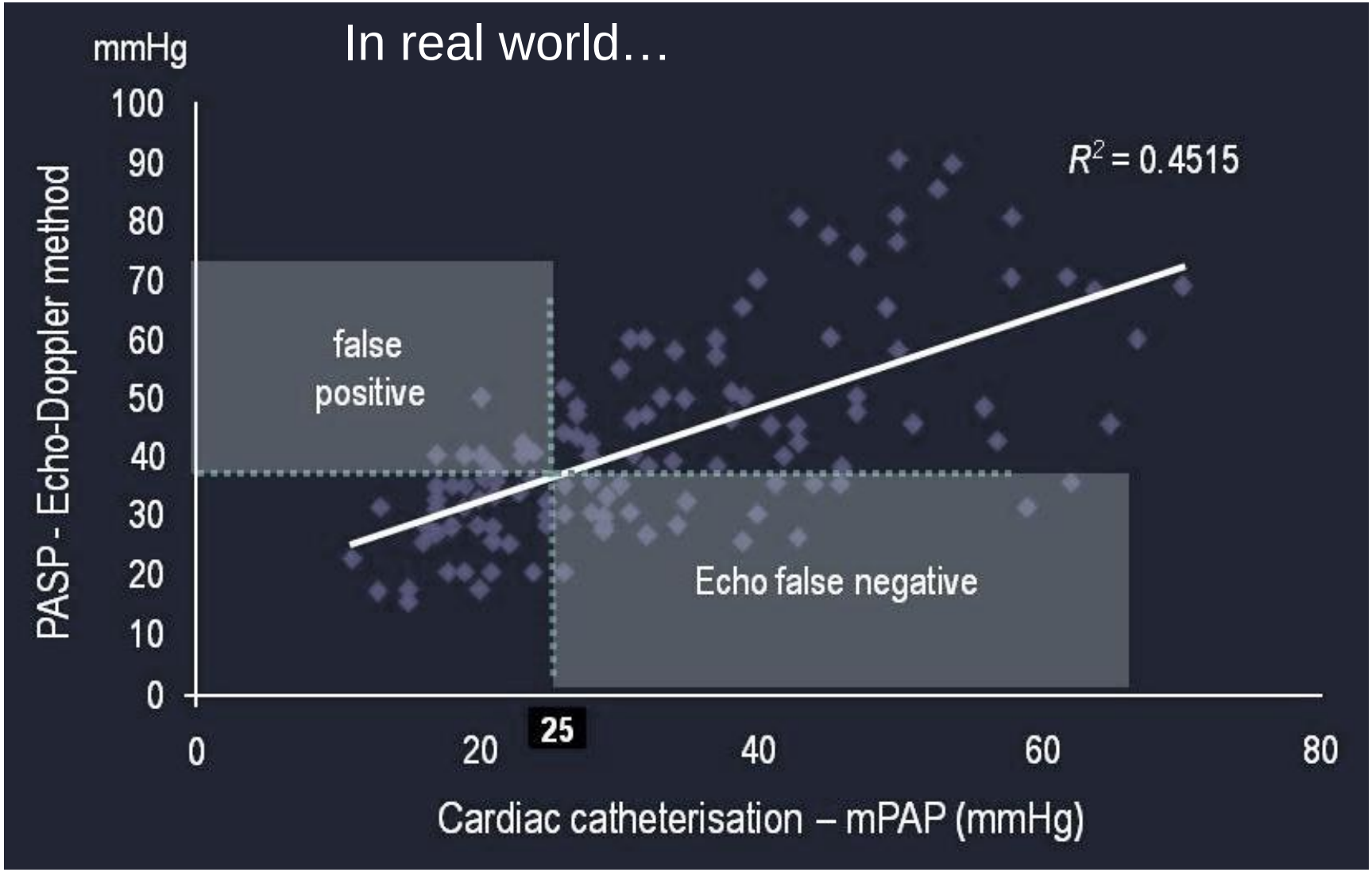

Mukerjee D, *et al. Rheumatology* 2004;43:461-6.

Pulmonary hypertension – Echo *vs* RHC

Accuracy of Doppler Echocardiography in the Hemodynamic Assessment of Pulmonary Hypertension

Micah R. Fisher[1]*, Paul R. Forfia[2†], Elzbieta Chamera[2], Traci Housten-Harris[1], Hunter C. Champion[2], Reda E. Girgis[1], Mary C. Corretti[2], and Paul M. Hassoun[1]

[1]Division of Pulmonary and Critical Care Medicine; [2]Division of Cardiology, Department of Medicine, Johns Hopkins University, Baltimore, Maryland

Am J Respir Crit Care Med Vol 179. pp 615–621, 2009

Conclusions: Doppler echocardiography may frequently be inaccurate in estimating pulmonary artery pressure and cardiac output in patients being evaluated for PH.

THE INACCURACY OF DOPPLER ECHOCARDIOGRAPHIC ESTIMATES OF PULMONARY ARTERY PRESSURES IN PATIENTS WITH PULMONARY HYPERTENSION: *IMPLICATIONS FOR CLINICAL PRACTICE*

Jonathan D. Rich, Sanjiv J. Shah, Rajiv Swamy, Anna Kamp and Stuart Rich

CHEST 2011; 139(5):988–993

Conclusions: DE estimates of PASP are inaccurate in patients with PH and should not be relied upon to make the diagnosis of PH or follow the efficacy of therapy.

Inaccuracy of echocardiographic estimates of PAP in PH

Pulmonary Artery systolic Pressure

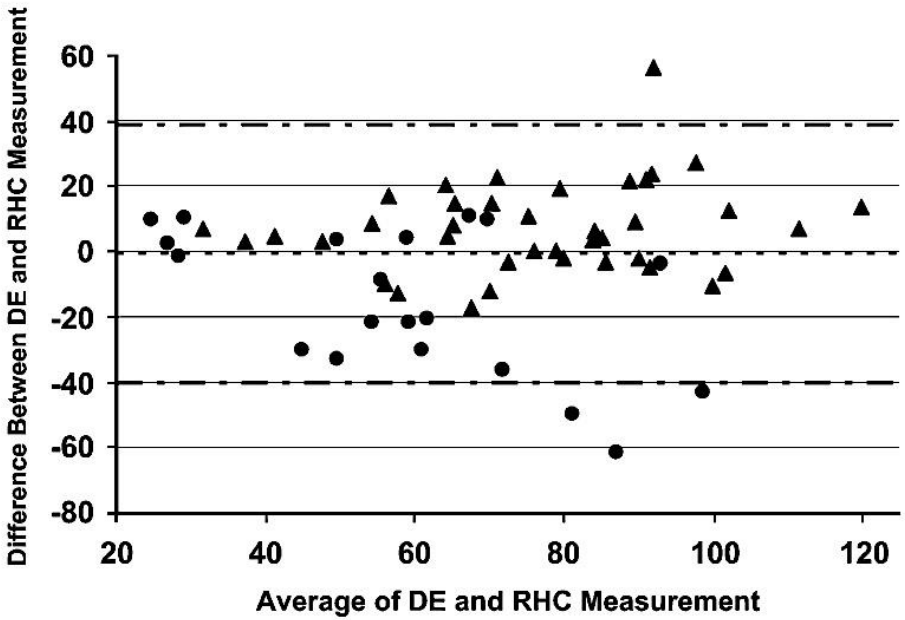

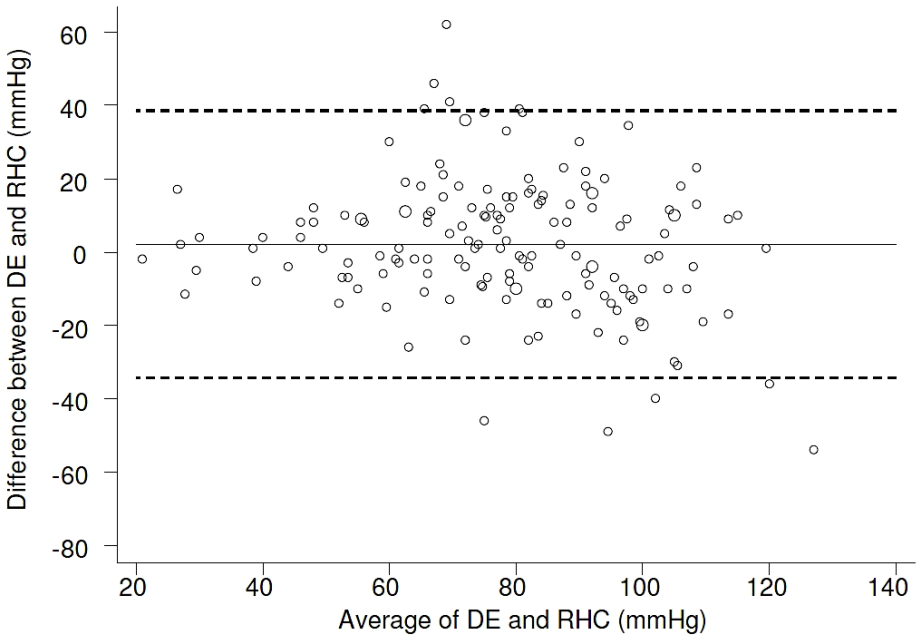

Bland-Altman plot of Doppler echocardiographic and RHC measurements of PAsP[1,2]

1. Fisher MR, *et al*. *Am J Respir Crit Care Med* 2009;179:615–21.
2. Rich JD, et al. *Chest*. 2011;139:988-93.

Inaccuracy of echocardiographic estimates of RAP in PH

Right Atrial Pressure

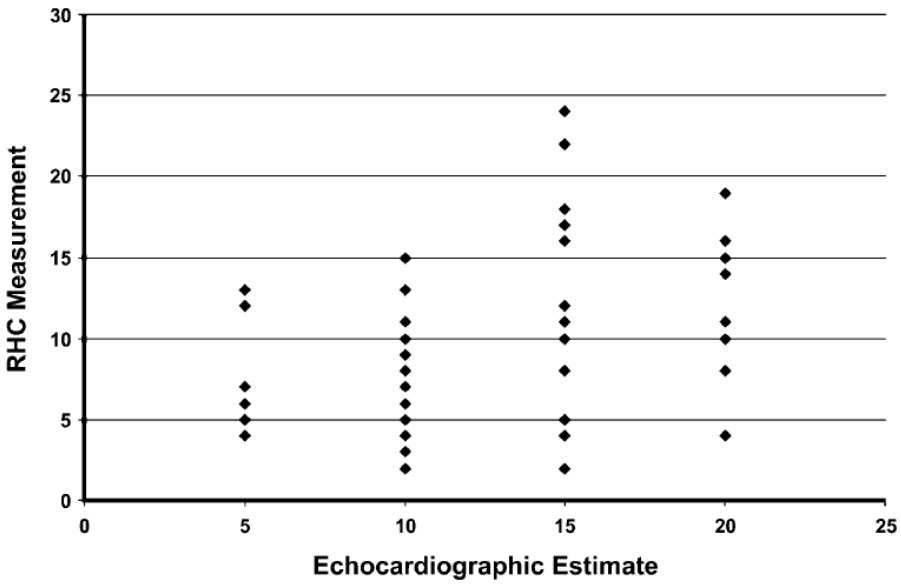

Comparison of RAP as estimated by Doppler echocardiography and RHC[1]

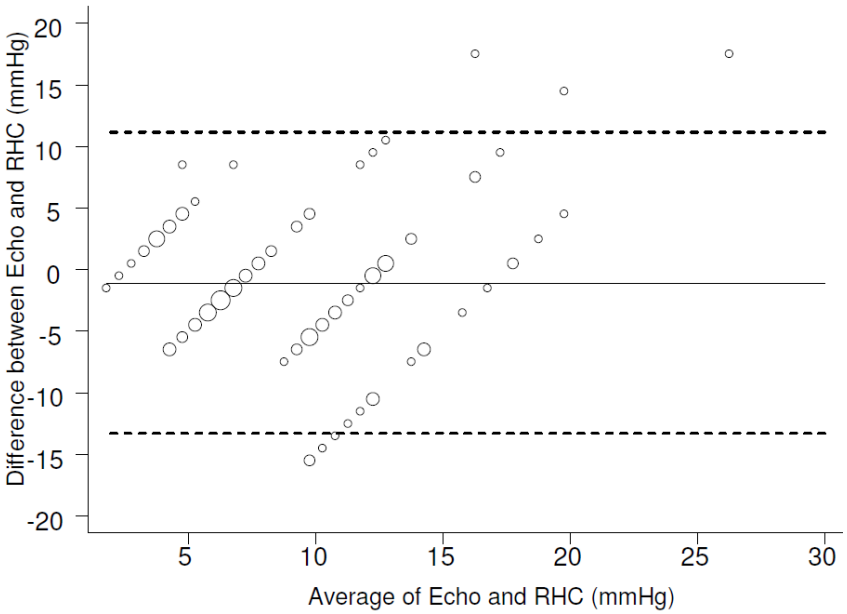

Bland Altman plot of RAP determined at RHC compared to RAP estimated by echo[2]

1. Fisher MR, *et al*. *Am J Respir Crit Care Med* 2009;179:615–21.
2. Rich JD, et al. *Chest*. 2011;139:988-93.

Inaccuracy of echocardiographic estimates of CO in PH

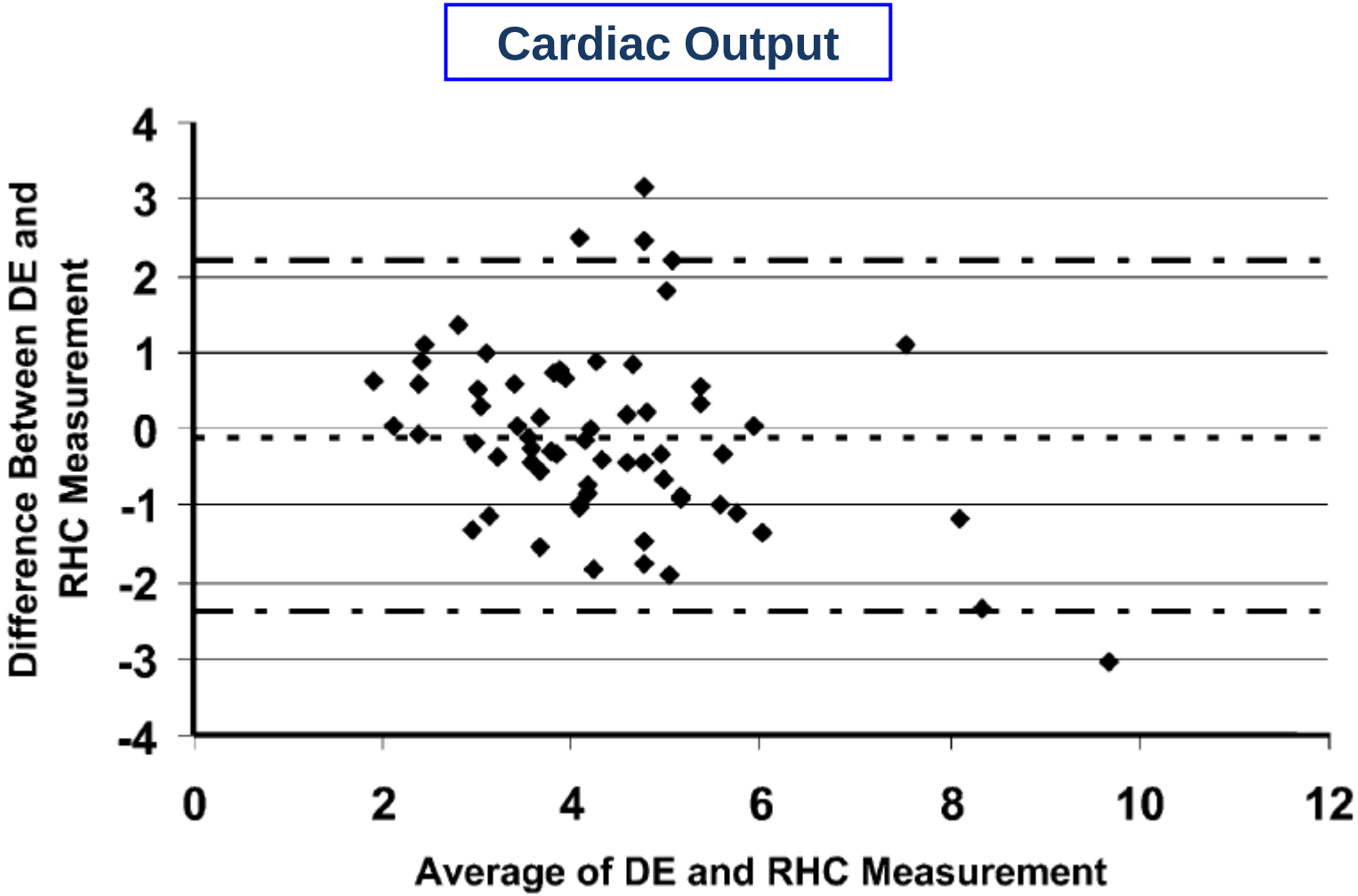

Fisher MR, *et al*. *Am J Respir Crit Care Med* 2009;179:615–21.

Screening PH with Echo (TRJ velocity)

Study	Patients sceened (n)	Criteria used for PH suspicion	Patients with PH suspicion (n)	PH confirmed by RHC (n)	False + Echo
ItinerAIR SSc[1]	570	TRJ ≥ 3 m/s, or ≥ 2.5 m/s and dyspnea	33	21/33 (18 precapillary; 3 postcapillary)	36%
ItinerAIR HIV[2]	247	TRJ ≥ 2.5 m/s	18	6/18 (5 precapillary; 1 postcapillary)	67%
ETENDARD[3]	385	TRJ ≥ 2.5 m/s	96	24/96 (6 precapillary; 13 postcapillary; 5 hyperkinetic state)	75%

1. Hachulla E, *et al*. Arthritis Rheum. 2005.
2. Sitbon O, *et al*. Am J Respir Crit Care Med 2008. 3. Parent F, *et al*. N Engl J Med 2011.

L’échocardiographie…

est un bon outil:

- De dépistage de l’hypertension pulmonaire
- De suivi de la fonction ventriculaire droite

est un **outil médiocre** de mesure de la PAPs

est **insuffisante** pour le diagnostic d’hypertension pulmonaire

Place de l'échographie cardiaque dans le diagnostic de l'HTP chez un patient symptomatique

Table 9 Diagnostic management suggested according to echocardiographic probability of pulmonary hypertension in patients with symptoms compatible with pulmonary hypertension, with or without risk factors for pulmonary arterial hypertension or chronic thromboembolic pulmonary hypertension

Echocardiographic probability of PH	Without risk factors or associated condition for PAH or CTEPH[d]	Class[a]	Level[b]	With risk factors or associated conditions for PAH or CTEPH[c]	Class[a]	Level[b]	Ref[c]
Low	Alternative diagnosis should be considered	IIa	C	Echo follow-up should be considered	IIa	C	
Intermediate	Alternative diagnosis, echo follow-up, should be considered	IIa	C	Further assessment of PH including RHC should be considered[e]	IIa	B	45, 46
	Further investigation of PH may be considered[e]	IIb					
High	Further investigation of PH (including RHC[e]) is recommended	I	C	Further investigation of PH[e] including RHC is recommended	I	C	

→ **RHC is the gold standard for PH diagnosis**

Galiè N. et al. ESC/ERS Guidelines. Eur Heart J 2016 & Eur Respir J 2015.

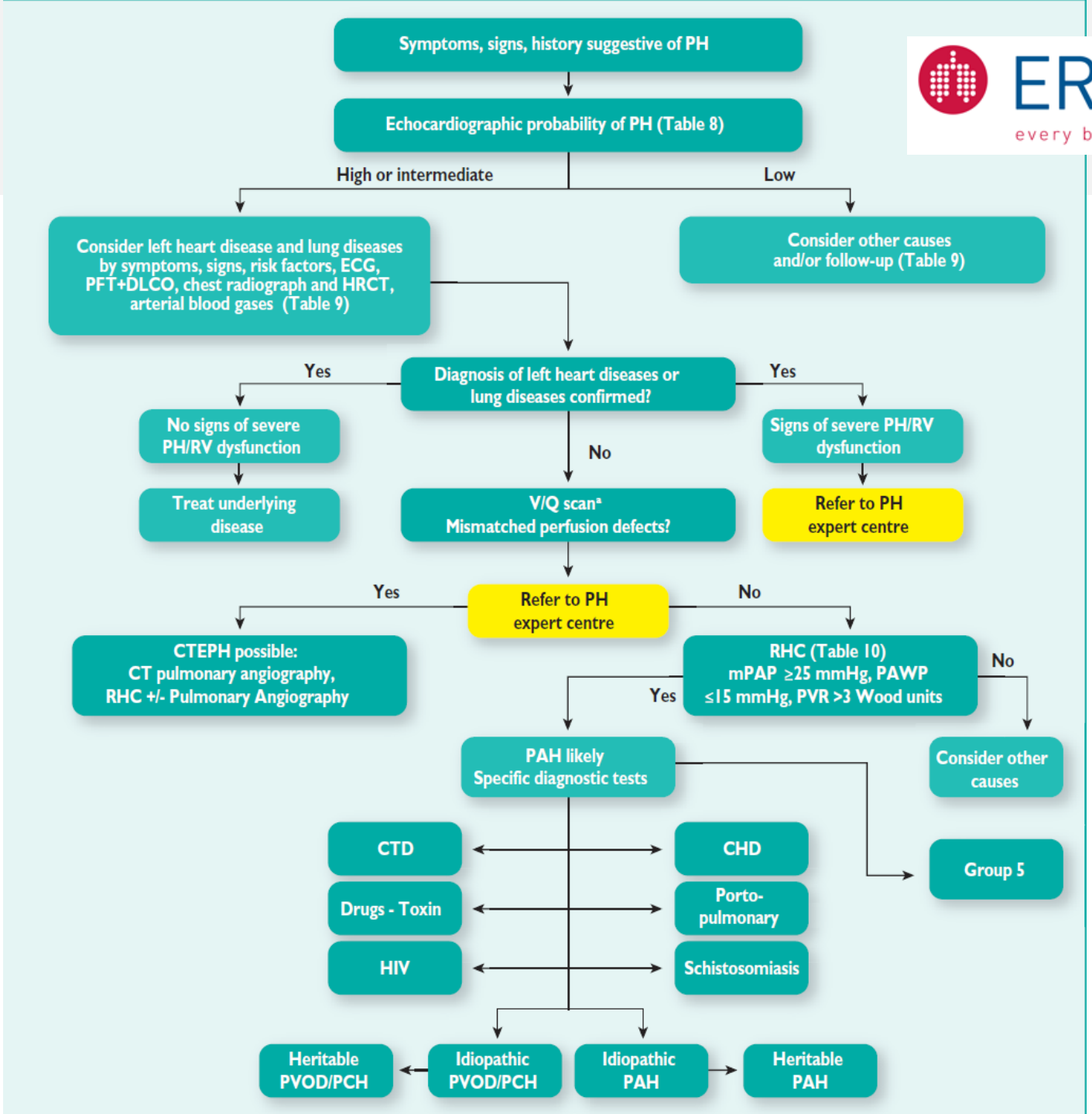

PFT = pulm fonction tests
CTD = connective tissue disease
CHD = congenital heart diseases
PVOD = pulmonary veno-occlusive disease
PCH = pulmonary capillary hemangiomathosis

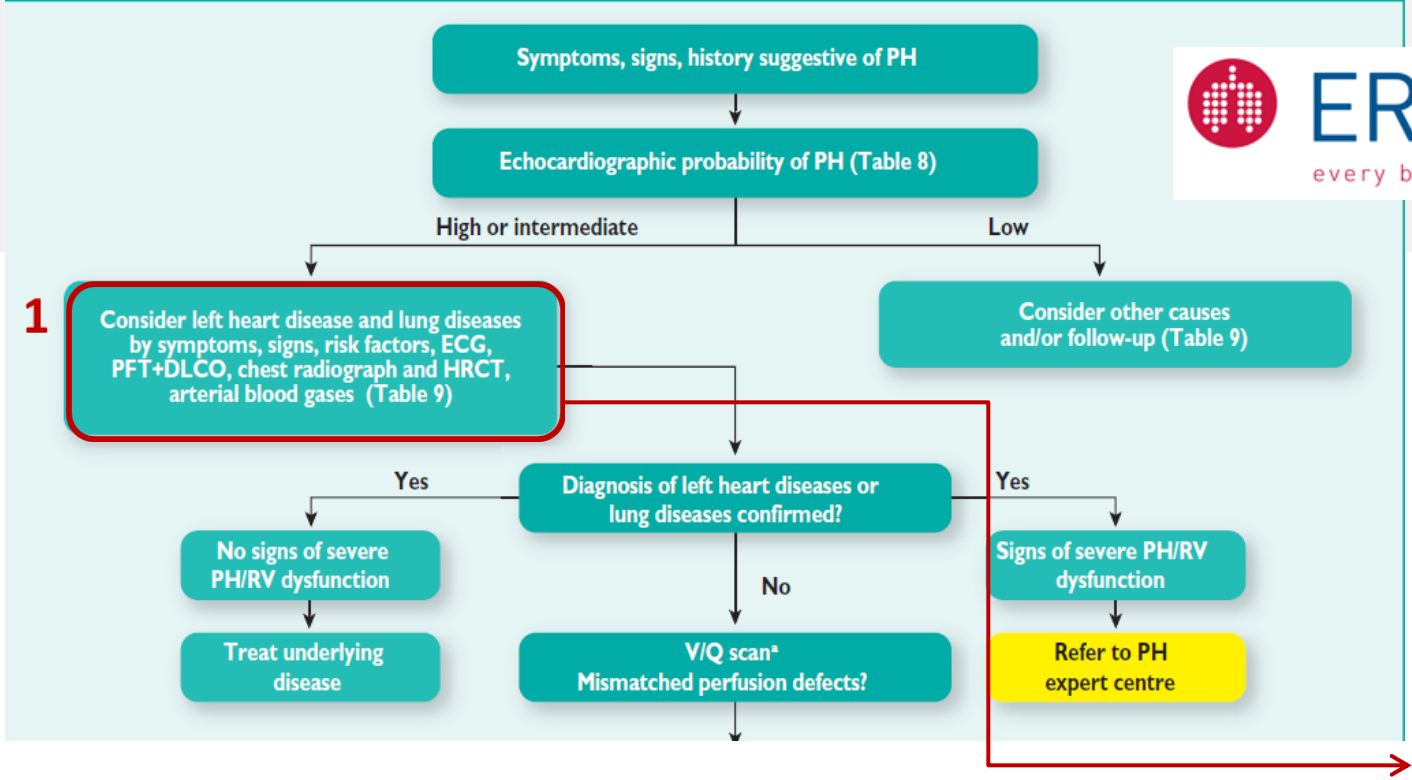

- Clinique
- ECG, Rx thorax
- EFR + DLCO + GDS
- Angioscanner thoracique
- ± Scintigraphie

PFT = pulm fonction tests
CTD = connective tissue disease
CHD = congenital heart diseases
PVOD = pulmonary veno-occlusive disease
PCH = pulmonary capillary hemangiomathosis

Chest Radiography

Pulmonary artery enlargement

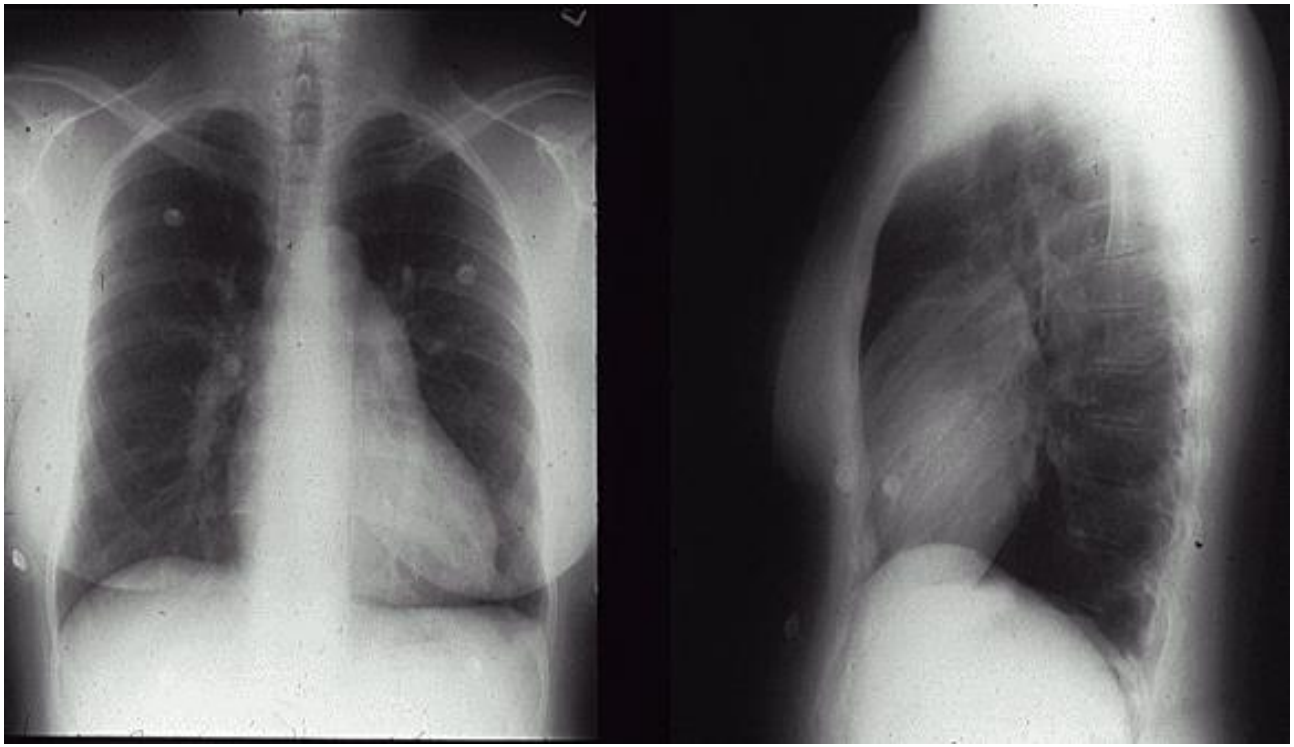

Peripheral

Hypovascularity

(Pruning)

Cardiomegaly

RV Enlargement
(↓ retrosternal space)

ECG

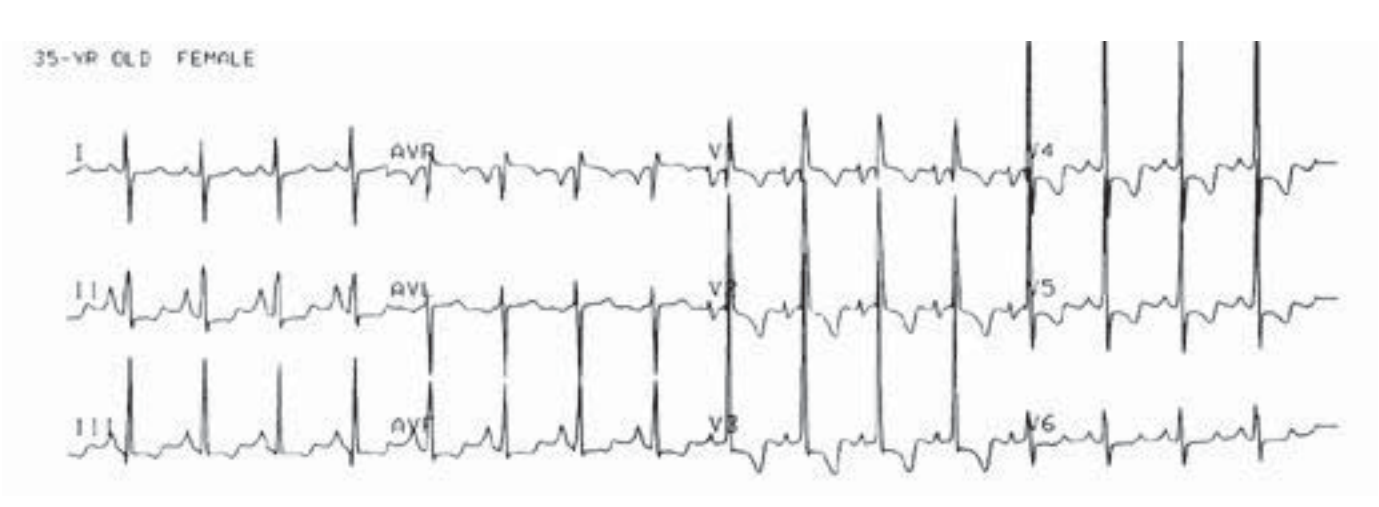

RV hypertrophy (87%)
Right axis deviation (79%)
QRS-axis > 90°
RA enlargement
P-wave > 2.5 mm .

Right bundle branch block
RSR'
RV strain
ST-T changes V1-4
Specific but not sensitive for PAH

Rich, Ann Intern Med 1987; 107: 216

EFR et GDS

- EFR (volumes et débits expiratoires) normales dans HTAP
  - Parfois obstruction distale
  - Distension dynamique (EF-X)
- DLCO modérément abaissée (> 50%)
  - Evoquer MVO (ou ILD) si DLCO < 50%
- GDS
  - Hypoxémie modérée (PaO2 70 mmHg)
  - Hypocapnie (facteur pronostique)
  - Si hypoxémie profonde, évoquer MVO ou cardiopathie congénitale avec shunt D-G (Sd d'Eisenmenger)
  - GDS en 100% pour rechercher shunt D-G
- TM6' et EF-X

Scanner thoracique

- Indispensable devant toute HT pulmonaire
  - Non pas pour dépister une HTP thrombo-embolique chronique +++ (rôle de la scintigraphie pulmonaire +++)
  - Rechercher pathologie pulmonaire sous-jacente (PID, emphysème…)
  - Rechercher des signes de MVO: hypertrophie des lignes septales, opacités nodulaires floues centrolobulaires, adénopathies médiastinales, épanchements pleuraux

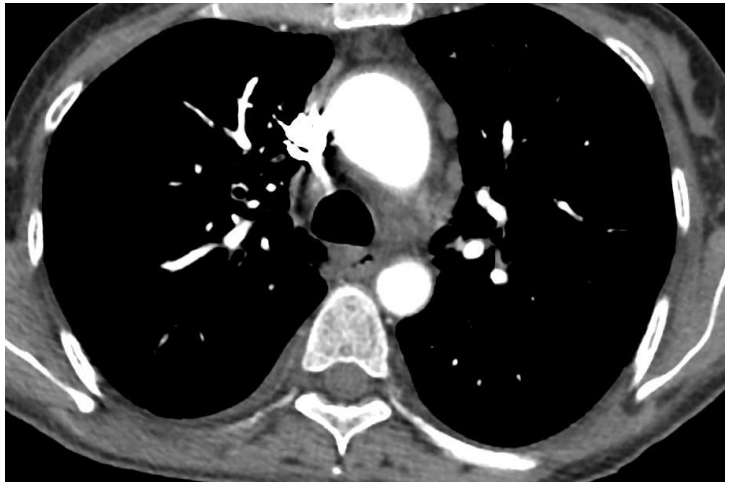

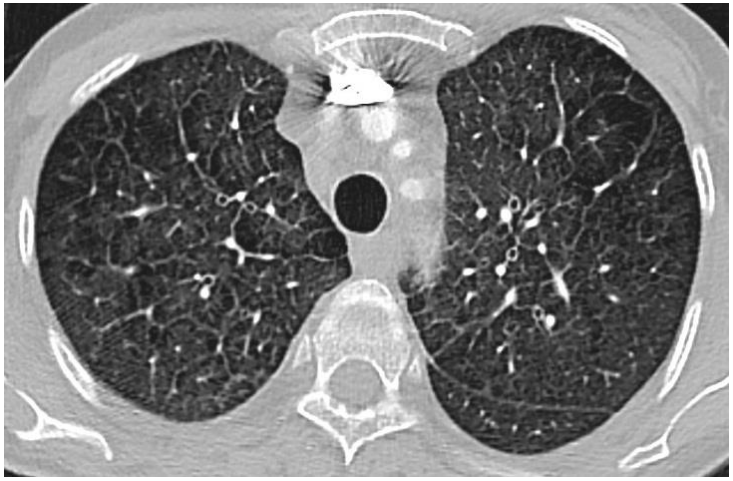

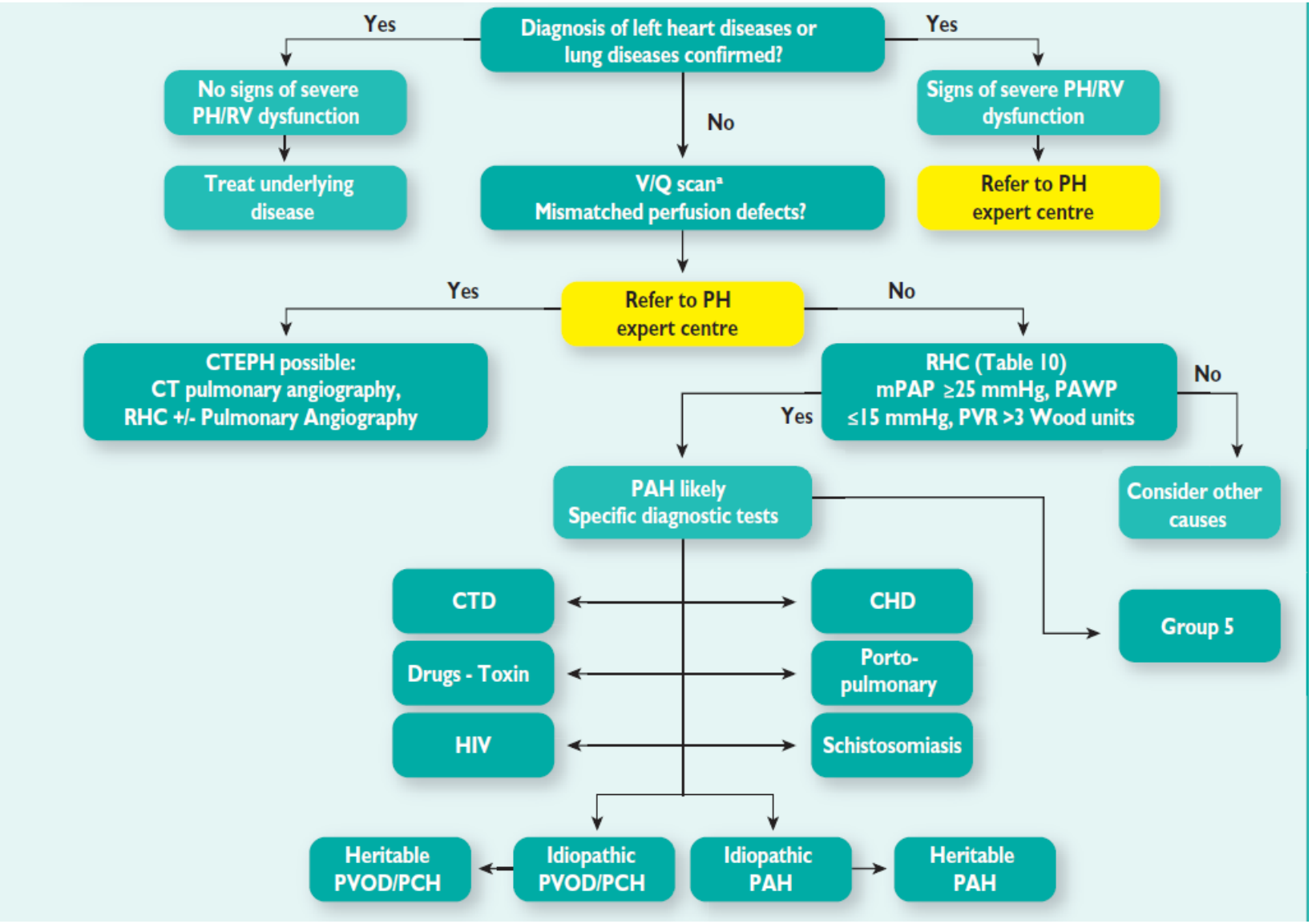
Diagnosis of left heart diseases or lung diseases confirmed?
Yes
No signs of severe PH/RV dysfunction
Treat underlying disease
Yes
Signs of severe PH/RV dysfunction
Refer to PH expert centre
No
V/Q scan[a] Mismatched perfusion defects?
Yes
CTEPH possible: CT pulmonary angiography, RHC +/- Pulmonary Angiography
Refer to PH expert centre
No
RHC (Table 10) mPAP ≥25 mmHg, PAWP ≤15 mmHg, PVR >3 Wood units
Yes
No
PAH likely Specific diagnostic tests
Consider other causes
CTD
CHD
Drugs - Toxin
Porto-pulmonary
HIV
Schistosomiasis
Group 5
Heritable PVOD/PCH
Idiopathic PVOD/PCH
Idiopathic PAH
Heritable PAH

Ventilation/Perfusion Lung Scan

- Key tool for detection of chronic thromboembolic disease

- V/Q scintigraphy[1]
  - Sensitivity: 96-99%
  - Specificity: 90-95%
  - Negative predictive value: 98,5%

- CT scan[1]
  - Sensitivity: 51%
  - Specificity: 99%
  - Negative predictive value: 80%

- V/Q scintigraphy does not anatomically localize the extent of disease

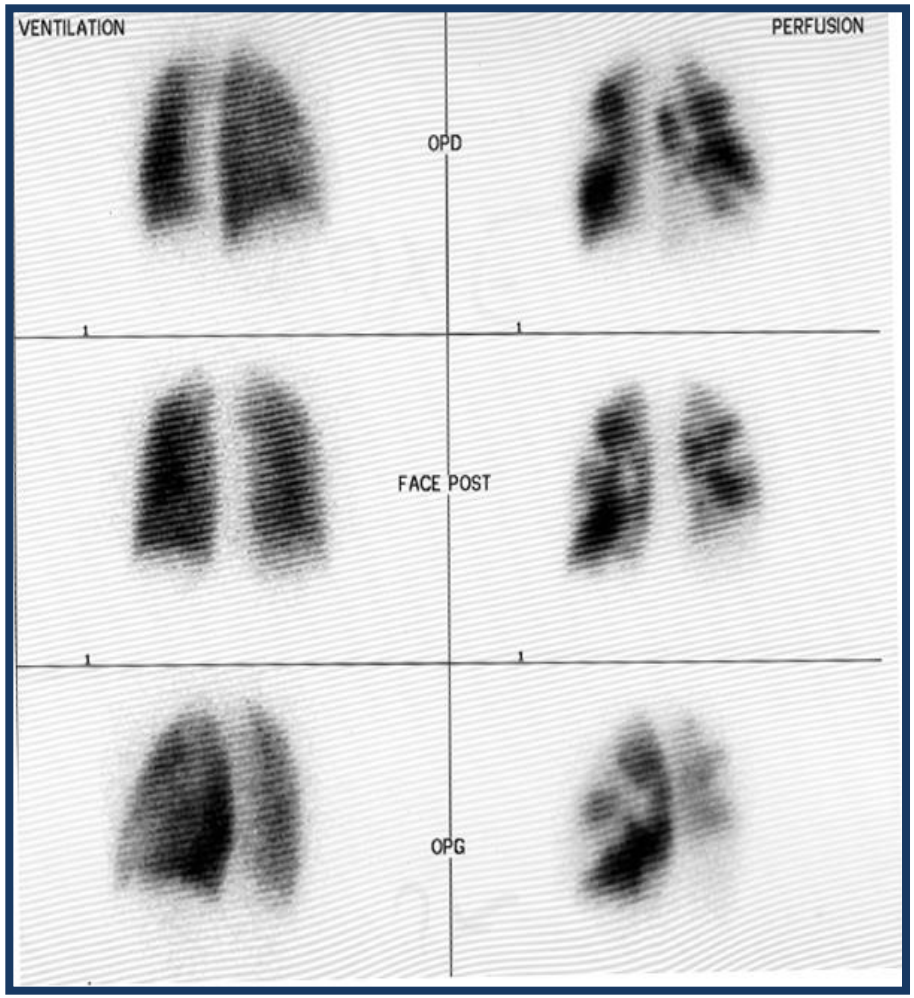

Tunariu N, et al. J Nucl Med 2007

Angio-CT & Pulmonary Angiogram

- Cornerstone of managing patients with CTEPH for many years
- Key investigation
- Confirms the diagnosis by identifying pouch defects, complete obstruction of vessels, vascular webs, intimal irregularities, abrupt narrowing of the major pulmonary arteries
- Mandatory for treatment decision (surgery, BPA, medical Rx)

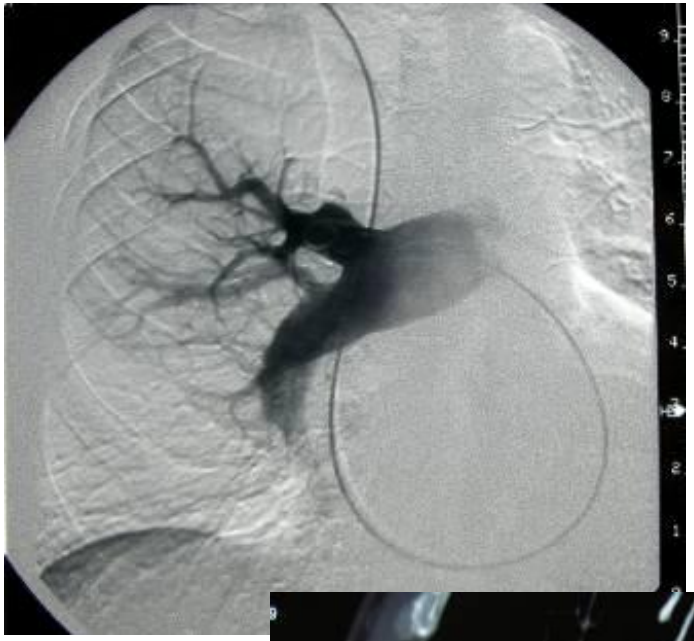

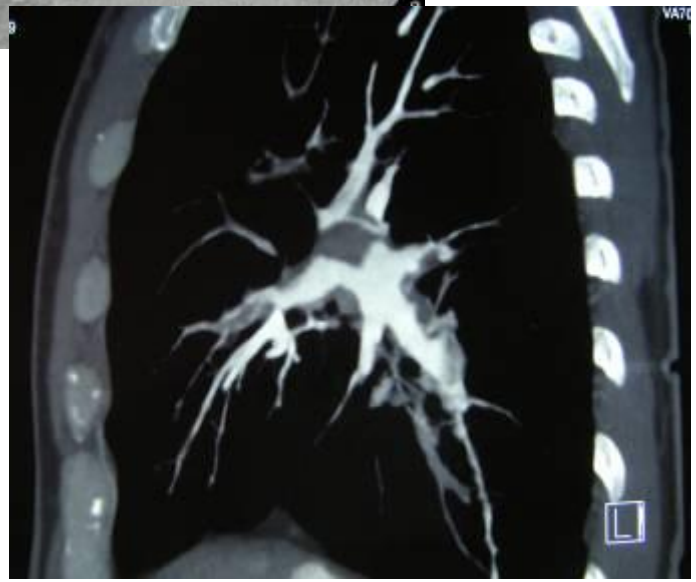

Recherche d’une hypertension portale

- Echo hépatique systématique (doppler tronc porte)
- Devant un hyperdébit cardiaque (au KT droit)
  - Mesure du gradient de pression sus-hépatique
- En fonction du contexte (cirrhose, hépatite virale chronique, maladie systémique…)
  - Bilan de la maladie hépatique
  - FOGD
  - …

Blood tests

- Routine biochemistry, haematology and thyroid function tests
- Antinuclear Antibodies
- Hepatitis testing
- HIV
- Clotting studies (anti-phospholipid antibodies, lupus anticoagulant and anti cardiolipin antibodies)
- BNP or pro-NT BNP
- Troponin

Baseline biomarker levels predicts survival

Uric acid[1]

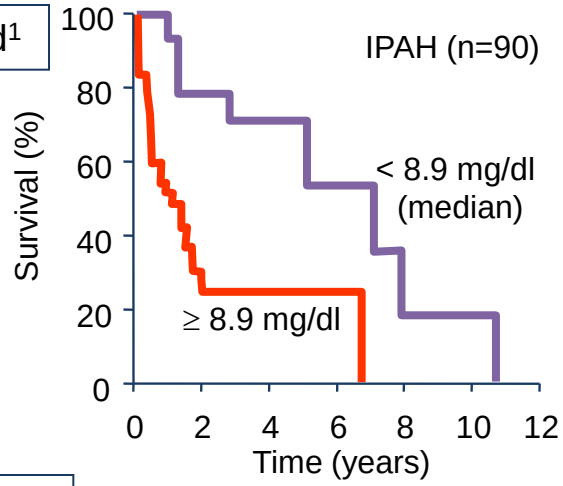

BNP[2]

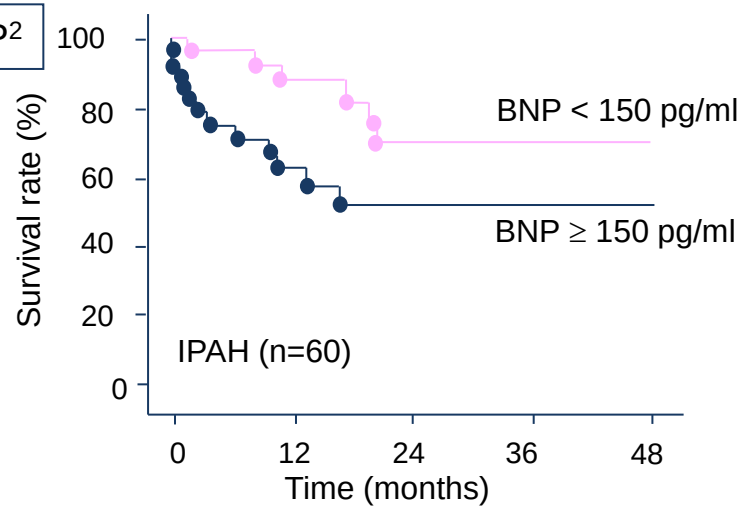

Troponin T[3]

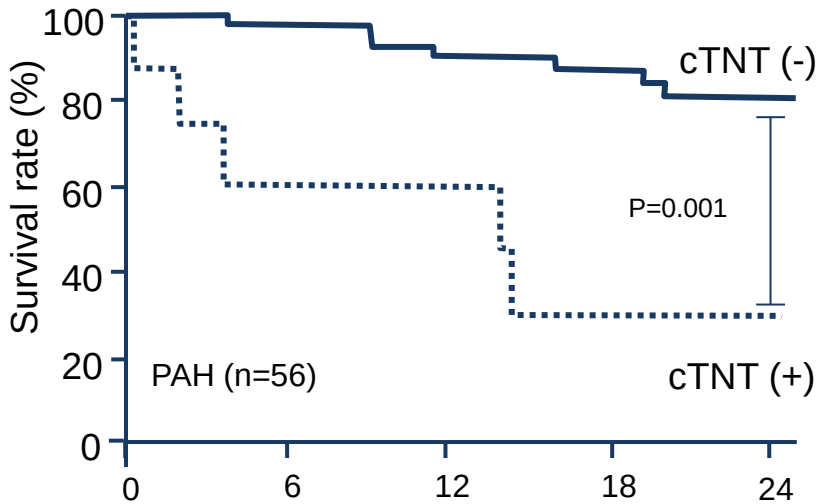

Na^+ [4]

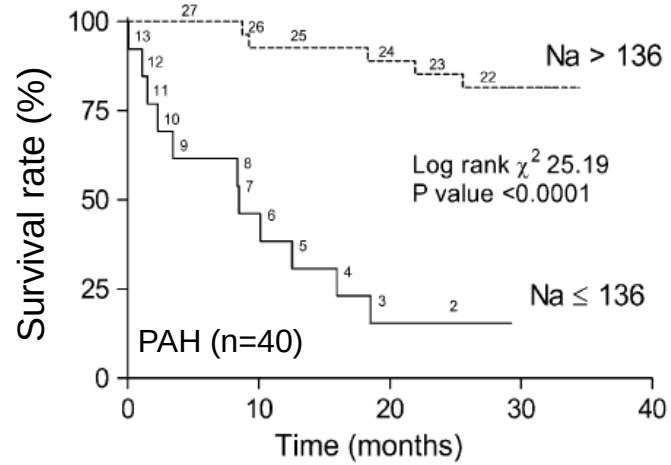

1. Nagaya N. AJRCCM 1999. 2. Nagaya N. Circulation 2000. 3. Torbicki A. Circulation 2003. 4. Forfia P. AJRCCM Med 2008.

NYHA Functional Classification

Class I

Are without resulting limitation of physical activity
ordinary physical activity does not cause undue dyspnoea or fatigue, chest pain or near syncope

Class II

Have slight limitation of physical activity
they are comfortable at rest,
ordinary physical activity causes undue dyspnoea or fatigue, chest pain or near syncope

Class III

Have a pronounced limitation of physical activity
they are comfortable at rest
less than ordinary activity causes undue dyspnoea or fatigue, chest pain or near syncope

Class IV

Show inability to carry out any physical activity without symptoms
these patients manifest signs of right heart failure
dyspnoea and/or fatigue may even be present at rest
discomfort is increased by any physical activity

Baseline functional class predicts survival

French Registry (2002-2003)

Incident and prevalent cases

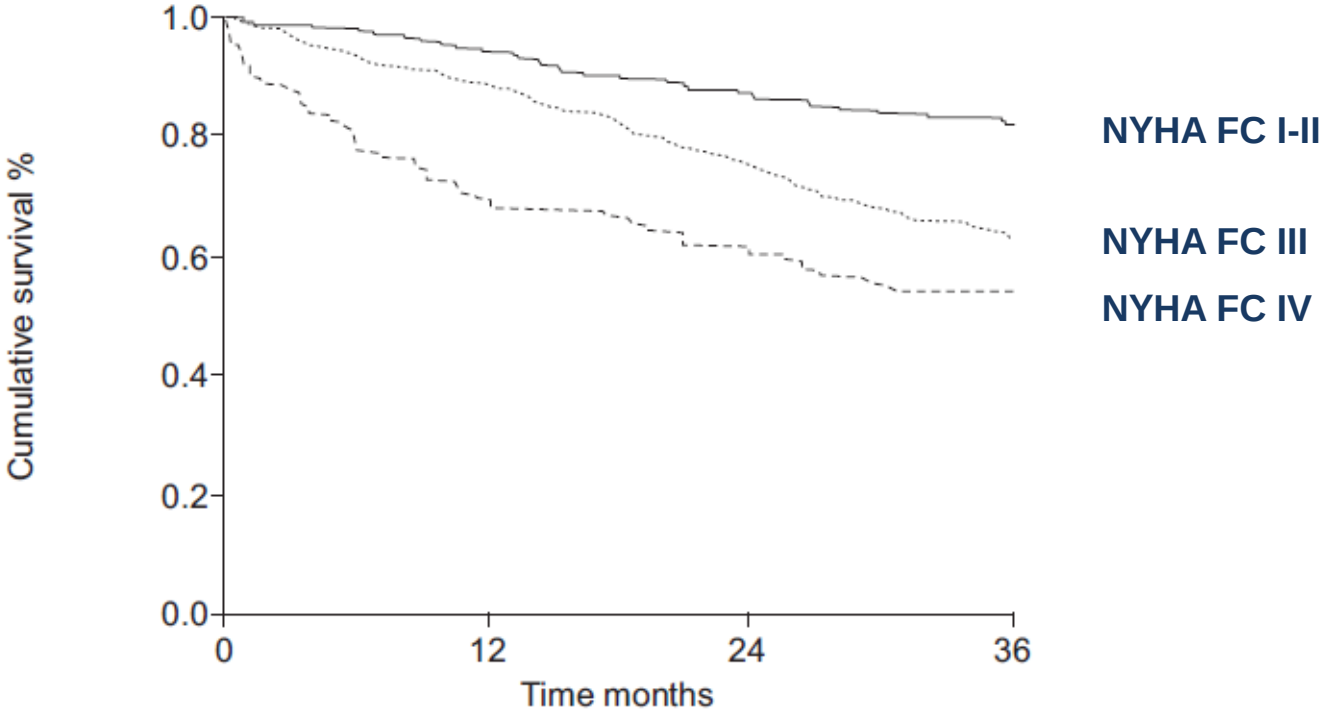

Subjects n				
NYHA FC I/II	172	163	152	144
NYHA FC III	421	374	317	271
NYHA FC IV	81	54	48	43

Humbert M, *et al*. *Eur Respir J* 2010; 36: 549–55.

Prognostic impact of follow-up assessment

NYHA FC at follow up is the strongest prognostic factor in PAH…

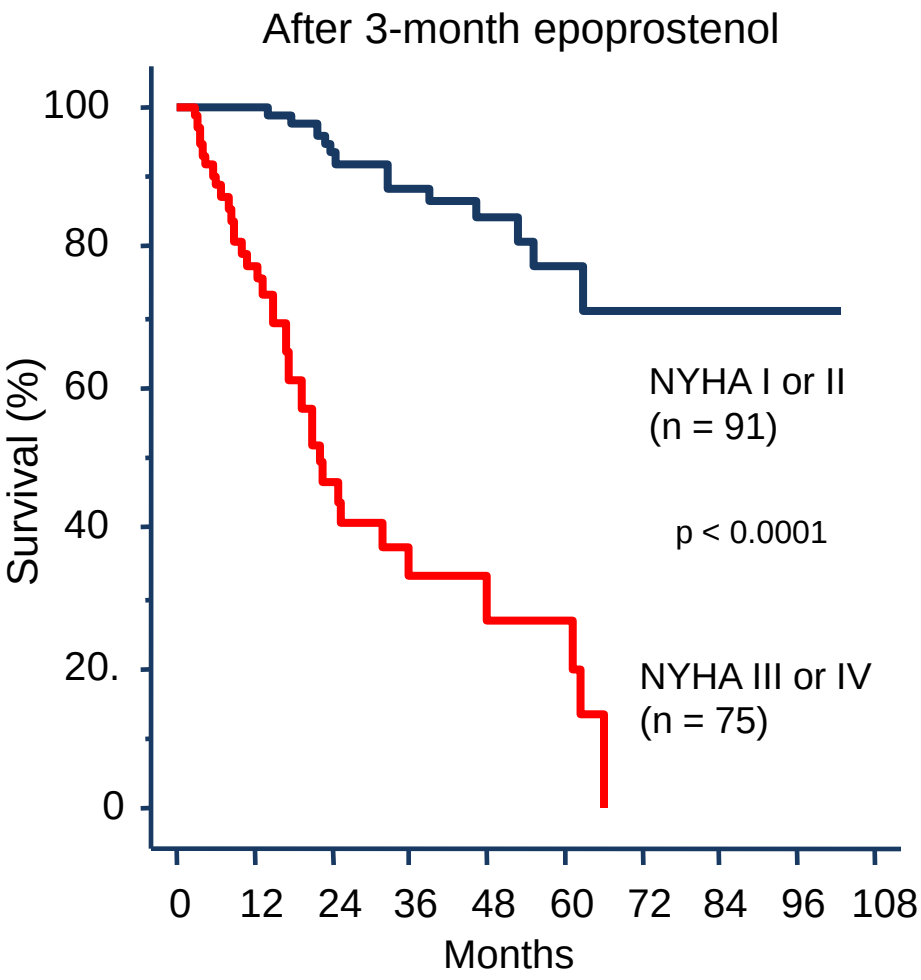

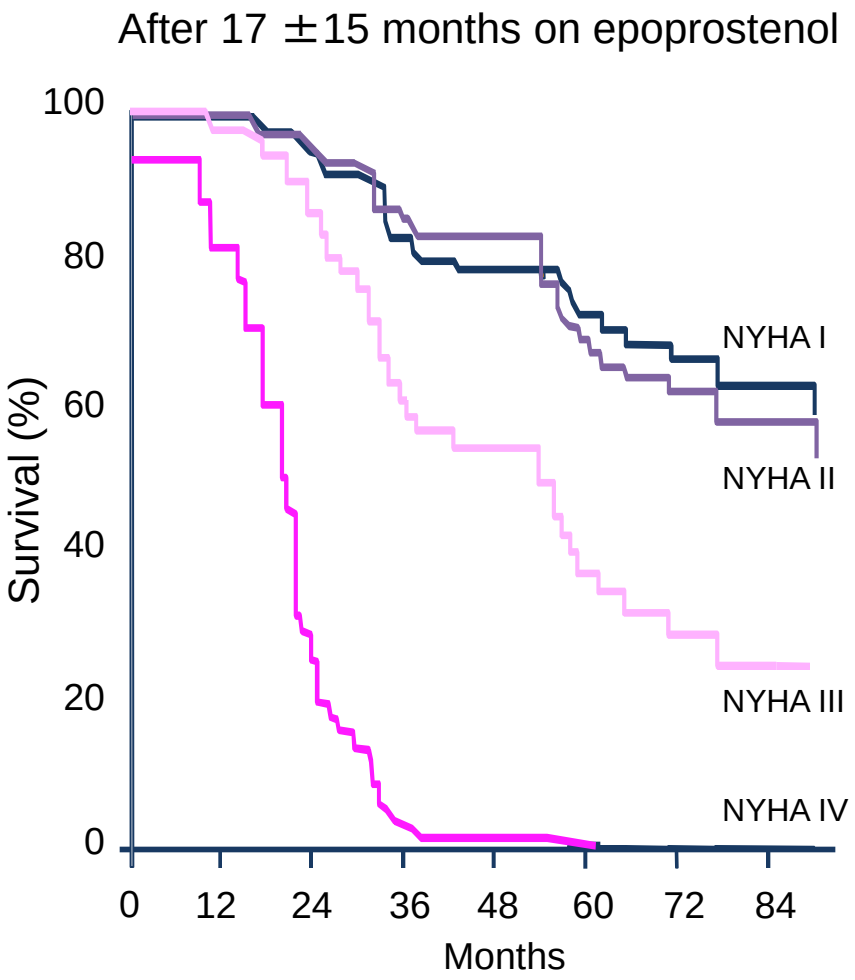

Sitbon O, *et al. J Am Coll Cardiol* 2002;40:780-8.

McLaughlin VV, *et al. Circulation* 2002;106:1477-82.

Baseline 6MWD correlates with survival

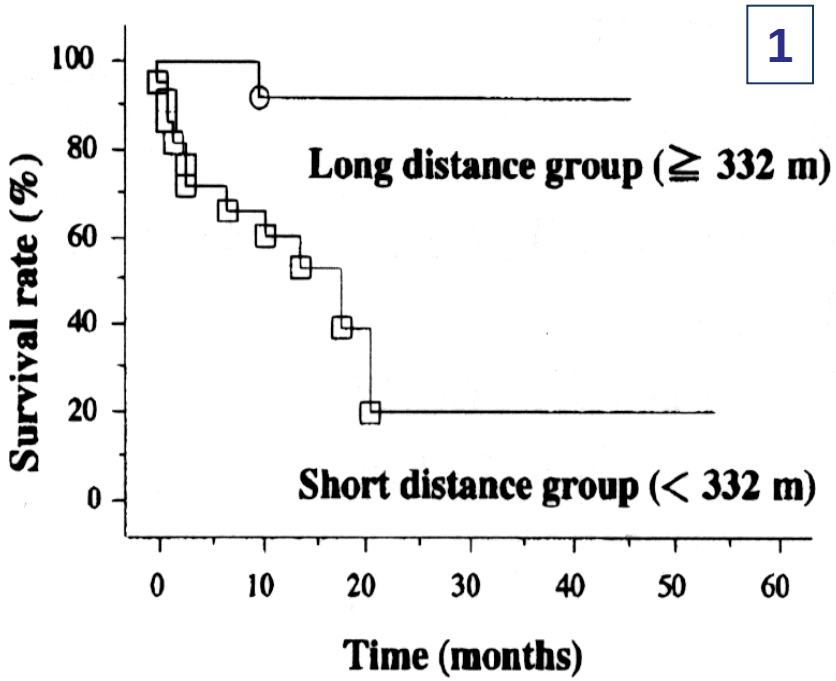

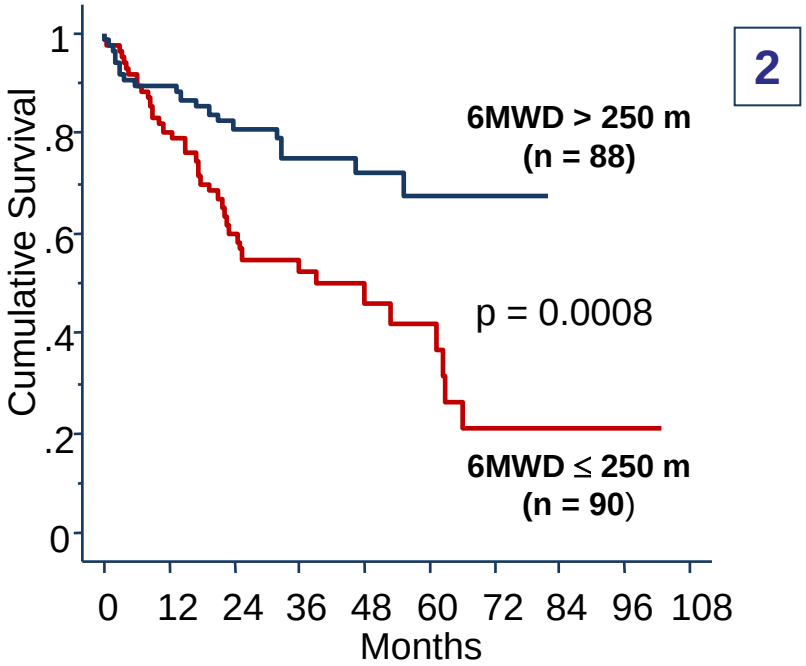

1. **IPAH, n=43, prospective**
2. **IPAH (epoprostenol), n=178, retrospective**

1. Miyamoto M, *et al. Am J Respir Crit Care Med* 2000; 161:487-92.
2. Sitbon O, *et al. J Am Coll Cardiol* 2002; 40: 780-8.

Prognostic impact of follow-up assessment

6MWD after 3 months of therapy predicts survival

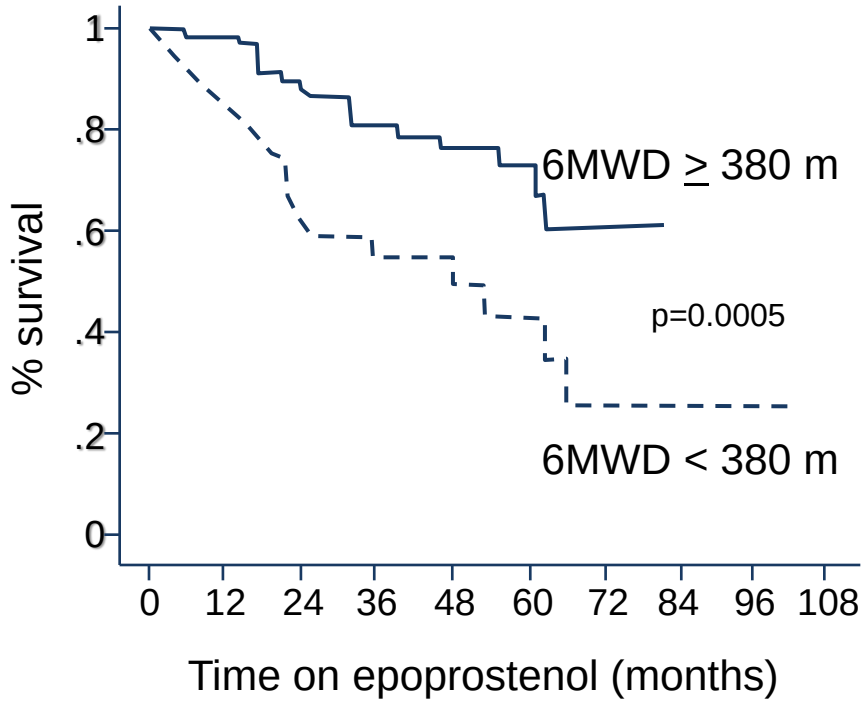

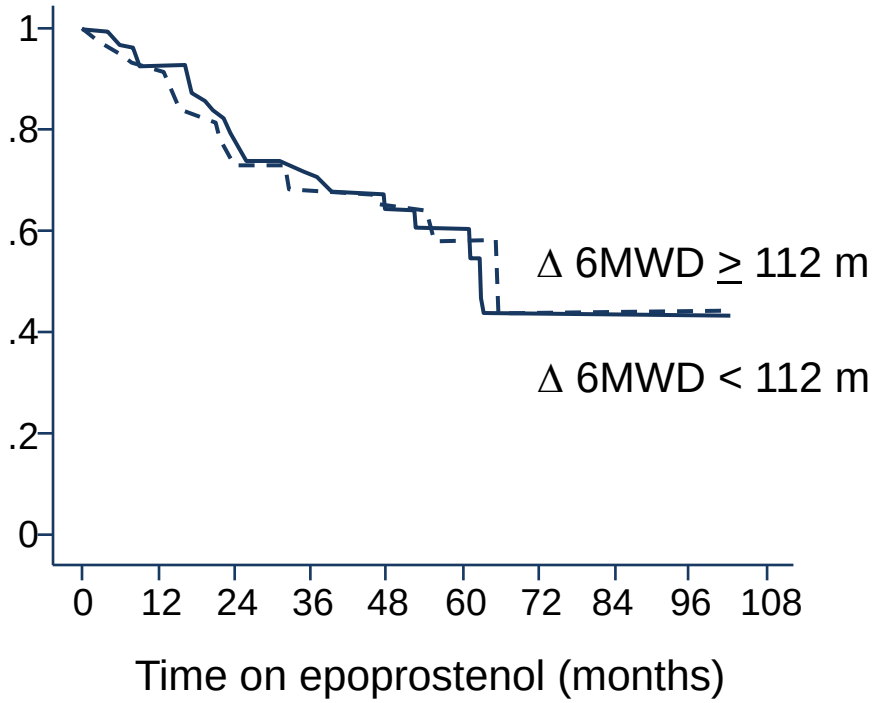

Importance of setting an absolute target vs relative change observed after 3-4 months of therapy

Sitbon O, *et al. J Am Coll Cardiol* 2002; 40: 780-8.

Conclusions I

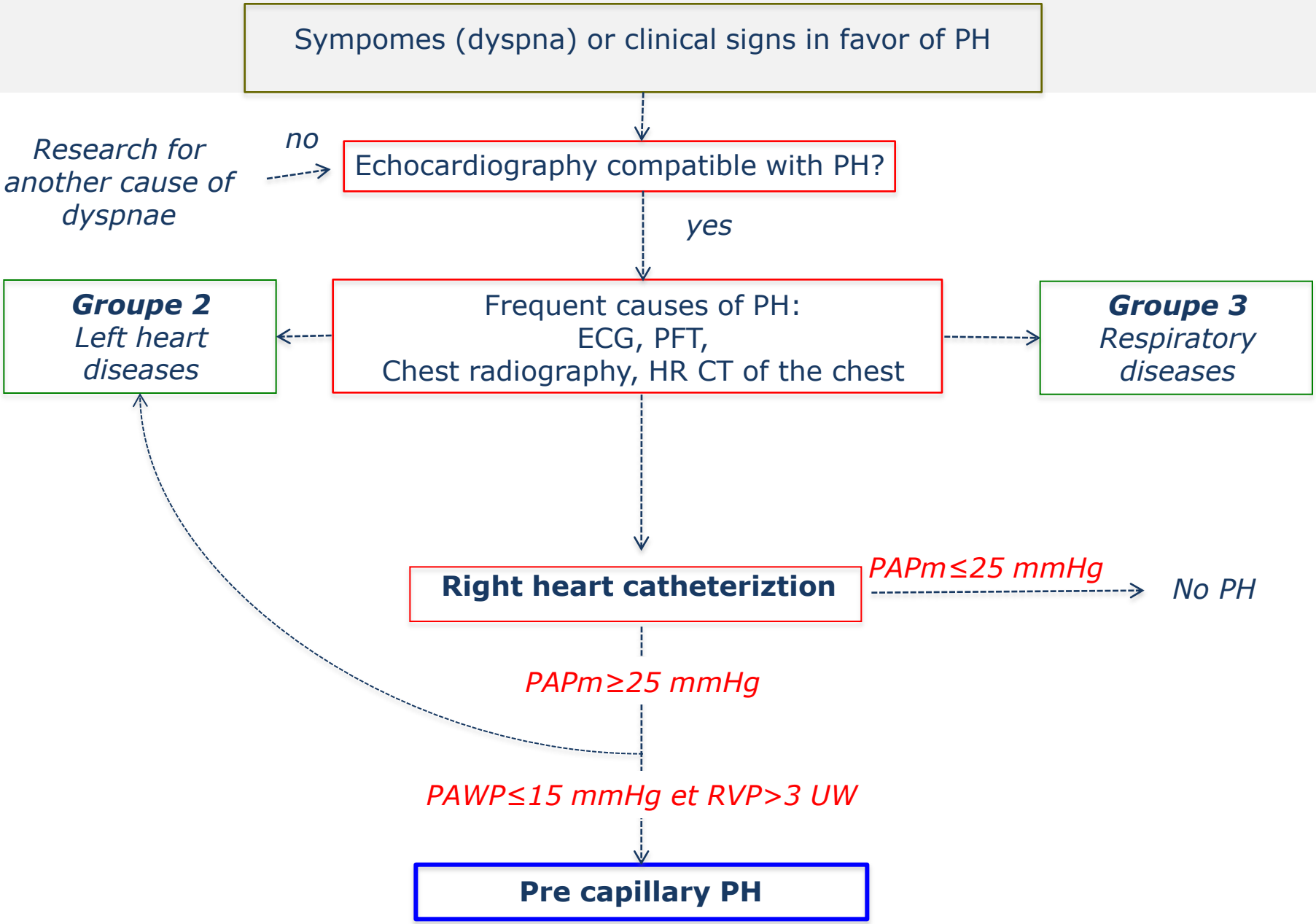

Conclusions II